DOI: 10.21088/nijs.0976.4747.16325.5

New Indian Journal of Surgery
Volume 16 Number 3, July - September 2025

CASE REPORT

Neurothekeoma of the Foot: A Rare Benign Tumour in a Rare Location

Ravisankar Palaniappan[1], Bhuvaneswari Gnanasekar[2], Arounkumar. N[3], Gowripriya. G[4], Padma Priya C[5]

HOW TO CITE THIS ARTICLE:

Ravisankar Palaniappan, Bhuvaneswari Gnanasekar, Arounkumar. N. Neurothekeoma of the Foot: A Rare Benign Tumour in a rare Location. New Indian J Surg. 2025; 16(3): 127-130.

ABSTRACT

Neurothekeomas are a rare, benign superficial cutaneous tumours of the head and neck region, occurs commonly in females, usually in second decades of life. A 19-year-old man presented with a painless swelling in the left foot and had a previous history of excision done on the same site. MRI demonstrated the lesion extending into the subcutaneous layer, without involvement of the fascia. The patient underwent wide local excision and reverse medial plantar artery flap cover. The presence of epithelioid tumour cell nests exhibiting characteristic cytological features, regardless of their focal distribution, serves as a diagnostic indicator. Complete surgical excision is the standard of care and has an excellent prognosis, with recurrence rates remaining exceedingly low. The diagnosis is challenging due to the wide range of clinically and histologically similar tumours.

KEYWORDS

• Neurothekeoma • Benign cutaneous tumour • Skin neoplasm • Nerve sheath tumours

AUTHOR'S AFFILIATION:

[1] Associate Professor, Division of Surgical Oncology, Department of General Surgery, Sri Venkateshwaraa Medical College Hospital & Research Centre, Puducherry 605107, India.

[2] Resident, Department of General Surgery, Sri Venkateshwaraa Medical College Hospital & Research Centre, Puducherry 605107, India.

[3] Associate Professor, Department of Plastic Reconstructure Surgery, Sri Venkateshwaraa Medical College Hospital & Research Centre, Puducherry 605107, India.

[4] Consultant, Department of Pathology, Rela Hospitals, Chennai 600052, India.

[5] Resident, Department of General Surgery, Sri Venkateshwaraa Medical College Hospital & Research Centre, Puducherry 605107, India.

CORRESPONDING AUTHOR:

Ravisankar Palaniappan, Associate Professor, Division of Surgical Oncology, Department of General Surgery, Sri Venkateshwaraa Medical College Hospital & Research Centre, Puducherry 605107, India.

E-mail: ravisankarpichaia@gmail.com

➢ **Received:** 04-06-2025 ➢ **Accepted:** 11-07-2025

Creative Commons Non Commercial CC BY-NC: This article is distributed under the terms of the Creative Commons Attribution NonCommercial 4.0 License (http://www.creativecommons.org/licenses/by-nc/4.0/) which permits non-Commercial use, reproduction and distribution of the work without further permission provided the original work is attributed as specified on the Red Flower Publication and Open Access pages (https://www.rfppl.co.in)

INTRODUCTION

Neurothekeoma (NT) are rare benign cutaneous tumour of the nerve sheath origin, more common in second and third decades of life and the commonest location are upper extremities, head and neck and trunk region.[1-3] They usually present as painless, slow growing masses. Recurrence depends on the completeness of excision.

CASE REPORT

A 19-year-old gentleman presented to our institute with a painless swelling in the left foot for the past three months. Previous history of excision was done over the same region at an outside hospital twice in the last three years and the last excision was done one year back. (Figure 1) The reports revealed that the margins of the specimen were positive and biopsy was suggestive of spindle cell tumor, which was not evaluated further then. Previous blocks review in our institute was suggestive of cellular neurothekeoma after the immunohistochemistry confirmation showing positivity for D2-40 and Neuron-Specific Enolase (NSE) and negative for S-100. (Figure 2a, 2b, 3a, 3b)



Figure 1: Clinical image showing 4 cm lesion on the plantar aspect of the foot

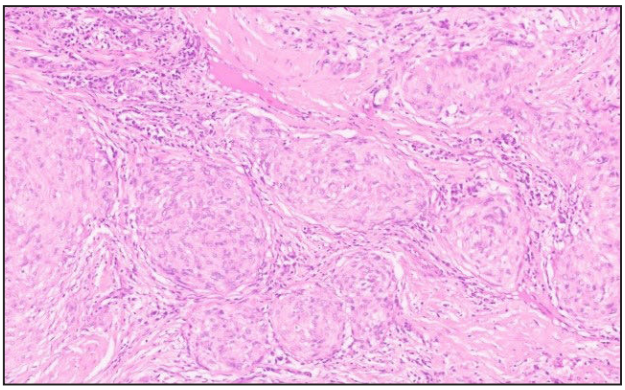

Figure 2a: High Power Microscopic view showing the Neoplasm composed of cells arranged as multiple nodules separated by collagenous stroma

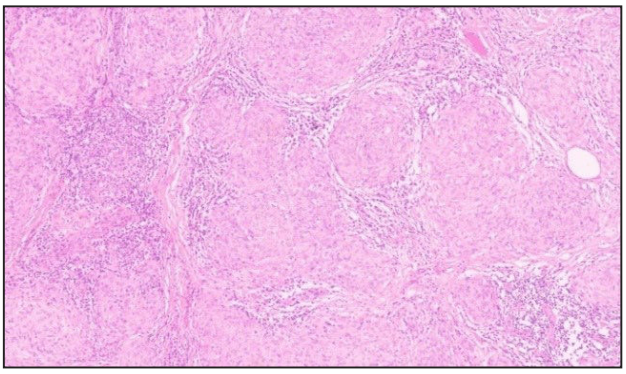

Figure 2b: Nodules composed of whorls/compact swirling clusters of cells with spindle/epithelioid morphology

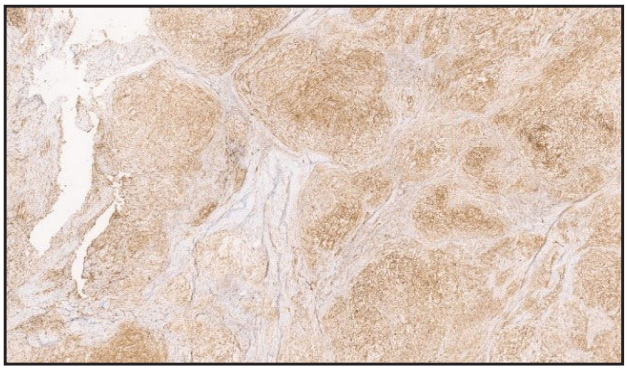

Figure 3a: IHC showing positivity for D2-40 marker

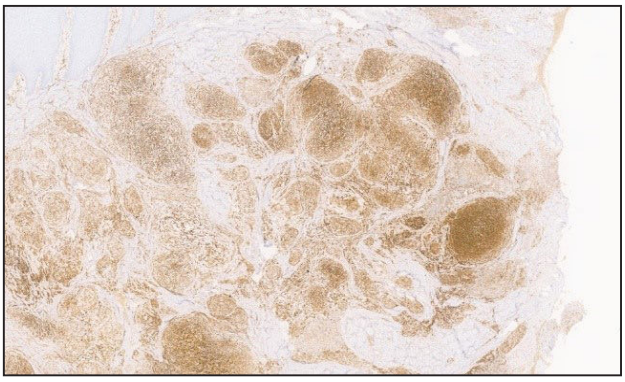

Figure 3b: IHC showing positivity for NSE marker



Figure 4: MRI image of the foot revealing cutaneous and subcutaneous lesion in the foot

Examination findings revealed a firm swelling of 4 cm present with 1 cm central ulceration over the central forefoot region over the plantar aspect. Magnetic resonance imaging (MRI) of the foot revealed the lesion extending to the subcutaneous layer without fascia involvement (Figure 4). Patient underwent wide local excision of 1 cm three-dimensional margin clearance with reverse medial plantar artery flap cover. Post-operative histopathology confirmed the same diagnosis and the microscopic margins were negative. The patient is disease free for the last 18 months.

DISCUSSION

In 1969, Harkin and Reed reported NT in the literature as nerve sheath myxoma.[1] They are predominantly found in young females with the mean age of presentation at 25 years and with an average size of 1cm.[3,4,5] Local trauma and estrogen use have been identified as triggering factors, which may explain the 2:1 ratio in females.[6] The largest study of cellular neurothekeoma included 133 cases, which were in head and neck region predominantly.[2] The most common location was the upper extremity (33.3%), followed by head and neck (29.4%), the trunk (17.2%) and the lower extremities (9.7%). Only 3 cases have been reported in foot since 2004. No malignant transformation of the mass has been described in the literature.[6]

Depending on the amount of myxoid matrix, NT can be classified into cellular NT (< 10% myxoid matrix), mixed NT (10 – 50% myxoid matrix) and myxoid NT (> 50% myxoid matrix).[7] Fetsch *et al.* suggested that neurothekeoma was derived from fibroblast-like cells with the capacity to produce myxoid matrix and differentiate into myofibroblasts. Immunoreactivity of S-100 protein was useful in differentiating nerve sheath myxoma from myxoid neurothekeoma, i.e., S-100 protein was positive in nerve sheath myxoma, but negative in (myxoid) neurothekeoma.[5]

Making the diagnosis is difficult because of the many clinically and histologically mimicking tumours including pyogenic granuloma, keloid, fibrous papule of the nose, angioma, adnexal tumor, hamartoma, melanocytic nevus, and basal cell carcinoma.[5] Recurrence of NT is somewhere around 3%.[5] Risk factors for recurrence are: myxoid type, being female, facial location, younger age at diagnosis, positive margins, and absence of fat-tissue in the sample.[5,6]

CONCLUSION

Neurothekeomas are rare, superficial tumours commonly found in the head, neck, shoulder, or upper extremities of young females, typically measuring less than 2 cm. Complete surgical excision is the recommended treatment, with low recurrence rates even in atypical cases, and awareness of the tumor's presentation is crucial for accurate diagnosis and management.

FUNDING

The authors did not receive support from any organization for the submitted work.

ETHICS APPROVAL

This is a case report. The Institutional Ethics Committee (IEC) has confirmed that no ethical approval is required.

REFERENCES

1. Harkin JC, Reed RJ. Tumors of the peripheral nervous system. Atlas of Tumor Pathology. Washington, DC: Armed Forces Institutes of Pathology; 1969:60–64.

2. Gallager RL, Helwig EB. Neurothekeoma–a benign cutaneous tumor of neural origin. Am J Clin Pathol. 1980;74:759–764.
3. Hornick JL, Fletcher CD. Cellular neurothekeoma: detailed characterization in a series of 133 cases. Am J Surg Pathol. 2007;31:329–340.
4. Papadopoulos EJ, Cohen PR, Hebert AA. Neurothekeoma: report of a case in an infant and review of the literature. J Am Acad Dermatol. 2004;50:129–134.
5. Fetsch JF, Laskin WB, Hallman JR, *et al.* Neurothekeoma: an analysis of 178 tumors with detailed immunohistochemical data and long-term patient follow-up information. Am J Surg Pathol. 2007;31:1103–1114.
6. Navarrete-Dechent C, Curi-Tuma M, Marín C, González S, Sandoval-Osses M. Cellular neurothekeoma: case report and its (un) relation with nerve sheath myxoma. An Bras Dermatol. 2015;90 (3 Suppl 1):S156-9.
7. Ding Y, Zou F, Peng W, Dai M, Gu H, Zhang B and Nie T: A giant neurothekeoma of the left shoulder blade: A case report. Oncol Lett 11: 1130-1134, 2016.