Original Article

New Indian Journal of Surgery
Volume 15 Number 3/July - September 2024
DOI: https://dx.doi.org/10.21088/nijs.0976.4747.15324.5

Use of Three Layered Regenerative Scaffold Dressing in the Wound Bed Preparation of Second Degree Scald Burns

Viswak M[1], Ravi Kumar Chittoria[2], Amrutha J S[3]

How to cite this article:
Viswak M, Ravi Kumar Chittoria, Amrutha J S. Use of Three Layered Regenerative Scaffold Dressing in the Wound Bed Preparation of Second Degree Scald Burns. New Indian J Surg. 2024; 15(3):119-121.

Abstract

Burns are one of the most common injuries among the children, which are due to thermal, scald, electrical burn injuries. Scald injuries tend to be the most common type of burn injury under the age of five, accounting for over 65% of the cases.In current scenario, various scaffolds are used to improve the quality of healing process and reduce the scar formation. Collagen acts as a scaffold through which regeneration of tissues occurs and also helps in new vessel formation. Other scaffolds like amniotic membrane which has unique antiinflammatory, bacteriostatic property helps in proper epithelization and reduces scarring and silicone gel sheets has hydrophobic property, which reduces scarring and provides analgesia. In this study we attempted three layered scaffold dressing for an second degree scald burn pediatric patient.

Keywords: Three layer scaffold; Regenerative; Pediatric; Second degree scald burns.

Author Affiliation: [1]Junior Resident, Department of Surgery, [2]Professor and Associate Dean (Academic), Head of IT Wing and Telemedicine, Department of Plastic Surgery & Telemedicine, [3]Senior Resident, Department of Plastic Surgery, Jawaharlal Institute of Postgraduate Medical Education and Research, Pondicherry 605006, India.

Corresponding Author: Ravi Kumar Chittoria, Professor and Associate Dean (Academic), Head of IT Wing and Telemedicine, Department of Plastic Surgery & Telemedicine, Jawaharlal Institute of Postgraduate Medical Education and Research, Pondicherry 605006, India.

Email: drchittoria@yahoo.com

Received on: 23-06-2024

Accepted on: 12-08-2024

This work is licensed under a Creative Commons Attribution-NonCommercial-ShareAlike 4.0.

INTRODUCTION

Wound healing is a physiological response of a living being to physical, chemical, mechanical or thermal injury. The wound healing process consists of several phases: homeostasis, inflammation, proliferation/granulation, and remodeling/maturation. Still, when the healing course deviates from the normal path, the healing does not advance past the inflammatory phase. In case of burns, there will be deficiency in normal healing. In modern medicine, usage of scaffolds either natural or synthetic has become popular and been recognized.

An ideal scaffold should consist of these key features: fitting physical, mechanical properties,

physiological background to enable cell adhesion, proliferation and differentiation, a high porosity, a large surface area to volume ratio and to be flexible enough to accommodate the shape of the wound and preferably biocompatible and biodegradable.

Collagen, synthetic or natural acts as a substitute for the dermal matrix through which epithelialization occur.[1] In the process of wound healing, degradation of collagen aids in the formation of new vessels, thereby it also helps in angiogenesis.

Amniotic membrane which is a natural scaffold has its own properties which includes its anti inflammatory, bacteriostatic, anti fibrotic, anti scarring and promotion of epithelization as well.[2] Since it has low immunogenicity and has its own progenitor cells, it can be an ideal choice in terms of usage of scaffolds for healing of wounds.

Silicon act as a barrier by reducing mechanical friction and transepidermal water loss which have been shown to be associated with the severity of a subsequent infection.[3] In vitro study shows silicone may regulate the inflammatory growth factors that cause fibrosis and promote acute wound healing.Important elements in this process include inflammatory markers such as TNF-α, TGF-β, IL-1, and IL-6 that are also implicated in acute inflammation.

MATERIALS AND METHODS

This study was conducted in Tertiary Care Centre in Department of Plastic Surgery after getting the department ethical committee approval. Informed consent was obtained. The subject was a 18-month - old female child who had accidental second degree scald burn injury which involves her left upper limb, left side of her face and postauricular region. She was admitted in tertiary burn care unit and initial resuscitation with intravenous fluids, analgesics and prophylactic antibiotics started. On postburn day 3, the three layered scaffold dressing was made and applied over deeper burn areas after dermabrasion assisted tangential excision. The three layers of scaffold is made bysterile amniotic membrane, dry collagen sheet and silicone sheet. The layer of amniotic membrane comes directly over the wound. The dressing was kept intact for 5 days.



Fig. 1: Second degree scalds burn

RESULTS

Intraoperative and post-operative periods were uneventful for the patient. On post operative day 5, dressing was opened and it showed significant areas of re-epithelialization and healing. All second degree superficial burn wound healed completely and islands of re-epithelization appeared in deep second degree burns areas. The future plan is to proceed with skin grafting of deep areas. No complications and side effects were noted during entire procedure.

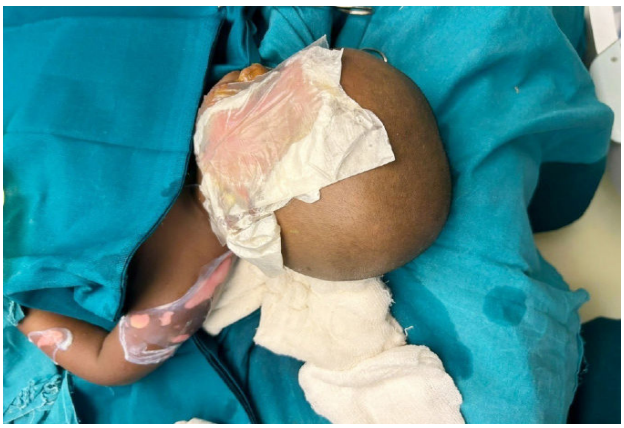

Fig. 2: Three layered scaffold with amnion, dry collagen sheet and silicone sheet applied over the burn wound



Fig. 3: Burn wound 5 days after application of regenerative scaffold- all superficial burns completely healed and islands of re-epithelization formed in deep burn areas

DISCUSSION

Partial-thickness burn wounds can heal spontaneously, whereas full-thickness burn wounds require skin grafting for definitive wound closure. Historically, the gold standard for closure of excised full-thickness burn wounds is split-thickness skin autograft. Patients with very large burn wounds have limited donor sites for harvesting of autograft and may benefit from the use of skin substitutes. Engineered skin substitutes that may provide temporary wound coverage until donor sites are ready to be reharvested for autograft, or if they contain autologous cells, may provide permanent wound closure. Relatively few permanent skin substitutes are currently available, but developments in tissue engineering of human skin are expected to soon provide improved models for increased availability and enhanced healing of burn wounds.[4] Commercially available Dermal Regeneration Template is a two-layered skin regeneration system.[5] The outer layer of this system is made of thin silicone film act as the epidermis of skin. This layer helps in protecting wound from infection and controls in loss of both heat and moisture. The outer collagen glycosaminoglycan (GAG) thermal layer functions as a biodegradable template that helps in regeneration of dermal tissue neodermis by the body. The inner layer of dermal regeneration template is made of complex matrix of cross-linked fibers. The porous material of the template helps in regeneration of skin. The cross-linked fiber material of dermal regeneration template acts a scaffold for the regrowth of skin layer. Once the dermal skin layer is regenerated, the outer layer of template is removed and is replaced with a thin epidermal skin graft. This procedure leaves the wound to a flexible, growing and allows permanent regeneration of skin. It allows faster healing of wound with minimum scarring. Here we have tried to replicate the same mechanism in our indigenously made dermal regeneration scaffold. One of the main drawbacks is the cost of the template. The indigenous dermal regeneration scaffold prepared from silicone sheet, dry collagen sheets and amnion is cost-effective and can be easily prepared and used on wounds. Thus, it can be used in hospital settings in developing countries where the affordability of commercial regeneration template is doubtful.

CONCLUSION

The adoption of this cost effective three layered scaffold dressing in second degree scald burns has been proven effective in this study. It hastens the overall healing time of second degree superficial and deep wound to within a week. Thus minimizing the total hospital stay and infection rates. However a large multicentric, double-blinded control research with statistical analysis is needed.

REFERENCES

1. Lazovic G, Colic M, Grubor M, Jovanovic M. The application of collagen sheet in open wound healing*. Ann Burns Fire Disasters. 2005 Sep 30;18(3):151-6.
2. Bose B. Burn wound dressing with human amniotic membrane. Ann R Coll Surg Engl. 1979 Nov;61(6):444-7.
3. Lucattelli E, Cipriani F, Pascone C, Di Lonardo A. Non-Healing Burn Wound Treatment With A Sterile Silicone Gel. Ann Burns Fire Disasters. 2021 Mar and 31;34(1):53-57.
4. Frame JD, Still J, Lakhel-LeCoadou A, Carstens MH, Lorenz C, Orlet H, *et al.* Use of dermal regeneration template in contracture release procedures: a multicenter evaluation. PlastReconstrSurg 2004; 113:1330-8.
5. Moiemen NS, Staiano JJ, Ojeh NO, Thway Y, Frame JD. Reconstructive surgery with a dermal regeneration template: clinical and histologic study. Plast Reconstr Surg 2001; 108:93-103.