Case Report

New Indian Journal of Surgery
Volume 14 Number 3/July - September 2023
DOI: https://dx.doi.org/10.21088/nijs.0976.4747.14323.6

A Case Series on Hydatid Cyst Disease: Usual and Unusual Sites with Different Approaches and Management

Binoy Kumar Behera[1], Muruganandam G.M.[2], J.G. Bhatt[3], J.G. Vagadia[4]

How to cite this article:
Binoy Kumar Behera, Muruganandam G.M., J.G. Bhatt, *et al.*/ A Case Series on Hydatid Cyst Disease: Usual and Unusual Sites with Different Approaches and Management/New Indian J Surg. 2023; 14(3):145–152.

Abstract

Hydatid disease is a cyclo zoonotic parasitic infection caused by Echinococcus granulosus. This disease is commonly found in the liver and lungs but no organ of the body is immune. When found at unusual sites in the body they show atypical presentations and pose a diagnostic challenge. In such conditions, a high index of suspicion, radiological investigations as well as histopathological examination are necessary in establishing the diagnosis. We present a review of the occurrence of hydatid disease at common as well as unusual sites and our experience with clinical presentation and management of hydatid disease.

Keywords: Hydatid disease; Usual sites; Unusual sites; Echinococcus granulosus.

INTRODUCTION

Hydatid disease in people is mainly caused by infection with the larval stage of the dog tapeworm Echinococcus granulosus. Cystic hydatid disease usually affects the liver (50–70%) and less frequently the lung, the spleen, the kidney, the bones, and the brain. Treatment of hydatid cysts has to be considered mandatory in symptomatic cysts and recommended in viable cysts because of the risk of severe complications. The modern treatment of hydatid cysts varies from surgical intervention to percutaneous drainage or medical therapy. Surgery is still the treatment of choice. This paper emphasizes the fact that hydatid disease should be suspected in cystic lesions affecting any organ in the body, especially in endemic areas of the world. It also shares our approach to managing different cases of hydatid cysts in usual and unusual locations.

Author Affiliation: [1]Second Year Resident, [2]Third Year Resident, [3]Professor & HOD, [4]Assistant Professor, Department of General Surgery, Pandit Deendayal Upadhyay Medical College & Hospital, Rajkot 360001, Gujarat, India.

Corresponding Author: Binoy Kumar Behera, Second Year Resident, Department of General Surgery, Pandit Deendayal Upadhyay Medical College & Hospital, Rajkot 360001, Gujarat, India.

Email: binay1996kumar@gmail.com

Received on 13-05-2023 **Accepted on** 30-06-2023

© Red Flower Publication Pvt. Ltd.

CASE SERIES

Case 1

A 22 year-old female presented with complaints of a gradually enlarging abdominal mass involving the lower abdomen for 6 months which is associated with dull aching and non-radiating pain. These were added to symptoms of breathlessness and

occasional hemoptysis for the past 4 months. There was a history of occasional fever but no weight loss. Breath sounds were diminished over the right lower and mid-zone. Posteroanterior chest x-ray (Fig. 1) revealed a large dense round well demarcated opacity involving the lower zone of the right lung field. Ultrasonography revealed large simple cysts in the right lung and cystic lesions noted in the right lobe of the liver. Another similar cystic lesion was noted in the abdominal cavity extending from the pelvis to the epigastric region compressing bowel loops.

CECT abdomen and pelvis was suggestive of a cystic lesion in segment IVb of the liver along with a lesion extending from the epigastric region up to the pelvic cavity. The lesion compresses bilateral ureters with resultant moderate hydro-uretero-nephrosis. A similar cystic lesion is also noted in the right lower pleural cavity along the mediastinal and posterior costal pleura. Minimal pleural effusion is noted on the right side. There is resultant atelectasis of basal segments of the right lower lobe. Findings were suggestive of hydatid cyst likely (type 1 Gharbi and type CE1 WHO grading likely).

On the first set up abdominal hydatid cyst was removed. The abdominal cyst was adhered to the fibers of the uterus and urinary bladder. Oral albendazole 400mg twice daily was given for 5 days pre-operatively and 4 weeks post-operatively. After a time interval of five weeks, the patient was posted for thoracoscopy guided deroofing of right lung hydatid cyst along with capitonnage. The patient's immediate recovery was remarkable and her symptoms were relieved completely.

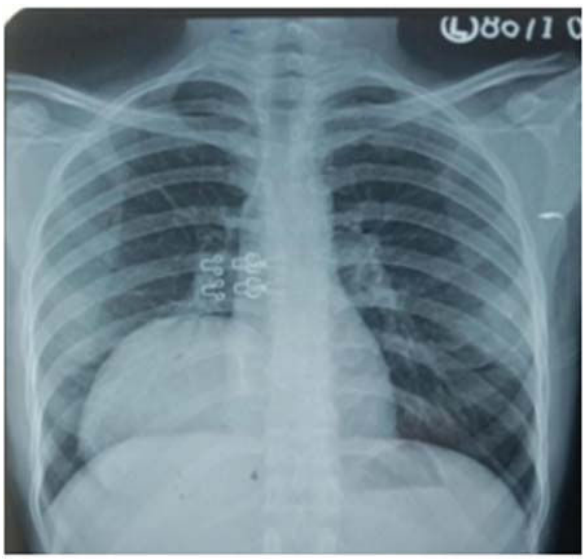

Fig. 1: Chest X-ray showing lung hydatid cyst



Fig. 2: The abdominal cyst adhered to the fibers of the uterus and urinary bladder

Case 2

A 60 year-old female presented with abdominal pain for 15 days associated with vomiting and jaundice. No history of fever or weight loss. Abdominal ultrasound suggested cystic swelling in the liver along with GB calculi. Routine investigations were completed. The eosinophil count was raised. CECT abdomen and pelvis also give the impression of cystic rim-enhancing lesions in the right lobe of the liver. She was put on Tab. Albendazole preoperatively to reduce the size. Open retrograde cholecystectomy with deroofing of liver hydatid cyst was done. The histopathological result adds to the confirmation of the diagnosis. The patient recovered from treatment with Tab. Albendazole 400 mg was given twice a day for 4 months.

Case 3

A 58 year-old male presented with abdominal pain for 3 days associated with vomiting and fever. Abdominal ultrasound suggested a grossly enlarged liver occupying the whole abdomen with multiple hepatic hydatid cysts noted in different stages. CECT abdomen and pelvis suggested a large cystic lesion in the right lobe of the liver with multiple hydatid cysts in the right subhepatic region. It also suggested a hydatid cyst in the left

iliac fossa region, right paraumbilical region, and multiple tiny cysts at the supra umbilical region. Routine investigations were normal. Exploratory laparotomy with deroofing of hydatid cyst was performed. The patient was discharged with drains in POD 5.

Case 4

A 40 year-old male presented with abdominal pain for 2 months associated with no complaints of vomiting or fever. Abdominal ultrasound suggested a complex cystic lesion at the right lobe of the liver. CECT abdomen and pelvis suggested a cystic lesion in the right lobe of the liver extending in the caudate lobe along with a calcified non-enhancing lesion in segment VI of the liver. After having all normal routine investigations and a pre-operative 5 day course of Tab Albendazole twice daily he underwent Exploratory laparotomy with deroofing of hydatid cyst with omentopexy. The patient was discharged with oral Albendazole to continue for 4 months.

Case 5

A 55 year-old female presented with complaints of mild non-radiating epigastric abdominal pain for the last 3 months. There was no history of fever and weight loss. Ultrasonography revealed a large cystic lesion with septic within at left lobe of the liver at the inferior surface pushing the stomach posteroinferior. CECT abdomen and pelvis were suggestive of a non-enhancing exophytic lesion in the left lobe of the liver along with an irregular calcified membrane. Oral albendazole 400 mg twice daily was given for 5 days pre-operatively. An exploratory laparotomy was done. On exploration, a 6x6 cm^2 well defined exophytic mass was found protruding from the left lobe of the liver. Pericystectomy was done. Post-operatively Albendazole was also started on the first post-operative day. The patient's immediate recovery was remarkable and her symptoms were relieved completely.

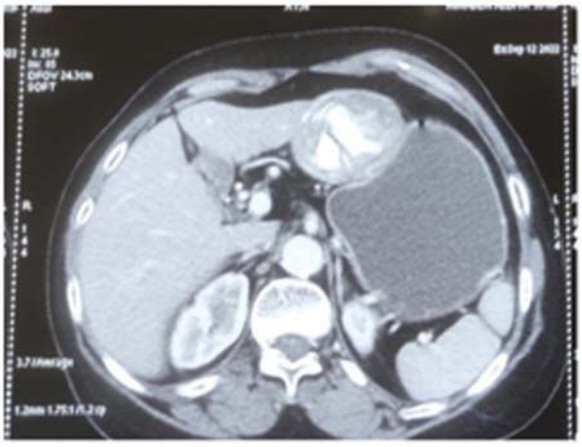

Fig. 3: CECT:A well-defined exophytic non-enhancing lesion of size 57x50x49 mm is noted in the left lobe of the liver with Irregular calcified membranes noted within the lesion.



Fig. 4: Well-defined exophytic mass found protruding from the left lobe of the liver.



Fig. 5: Calcified hydatid cyst en-mass after Pericystectomy

Case 6

A 15 year male patient was admitted with a history of acute abdominal pain in the left side of the upper abdomen, abdominal distention, and vomiting for one month. There was no history of trauma. ELISA antibodies (IgG) for echinococcal antigen were positive. Computed tomography (CT) scan of the abdomen and pelvis showed a cystic lesion with an internal floating membrane in the tail & body of the pancreas. So probable diagnosis of pancreatic hydatid cyst was made. Exploration revealed a hydatid cyst in the tail of the pancreas with omental fat necrosis. The Cyst wall was firmly adherent to the splenic hilum. Distal pancreatectomy with splenectomy was performed. The immediate postoperative course was uneventful.

Three 28 days course of Tab. Albendazole separated by two weeks intervals were given. The patient was given pneumococcal, meningococcal, and Haemophilus influenza vaccinations at the time of Discharge. Histopathological findings confirmed the diagnosis of a pancreatic hydatid cyst. Follow-up after 6 months showed the patient to be symptom and disease free.

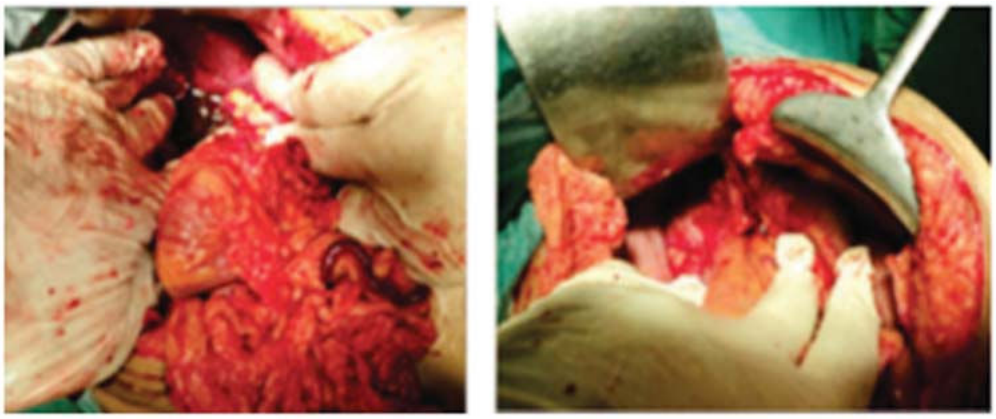

Fig. 6: Intra-operative finding of cyst wall adherent to the pancreas and splenic hilum.

Case 7

A 40 year-old female patient was operated on for a single hydatid cyst by laparoscopic hydatid cystotomy in the year 2010 (14×12 cm cyst in the right lobe of the liver, touching diaphragm with a relatively thick wall, diagnosed by CECT abdomen). After 10 years she presented with chief complaints of a lump in her right upper abdomen and pain around the umbilical region. On examination, a spherical swelling of 8×6 cm over the right hypochondrium, which was non-tender, cystic in consistency, moves with respiration. A diffuse swelling of size 5×3 cm was palpated infra umbilical on the straight leg raise test and not palpated in the supine position. Ultrasonography (USG) scan of the abdomen was suggestive of multiple hydatid cysts of the liver largest one of 14×12 cm, and a mesenteric hydatid cyst of size 6×2 cm around the right side of the umbilical region. CECT of the abdomen revealed 2 hydatid cyst lesions in the liver, a larger one present in the anterior part of the right lobe of the liver of size 149×114×112 mm and a second one posterior to the above lesion of size 104×59×78 mm which was an exophytic cystic lesion, abutting to IVC and right dome of the diaphragm. CECT of the abdomen revealed that previously thought mesenteric hydatid cyst (on USG) was a hydatid cyst of size 83×34×39 mm in the anterior abdominal wall of the right side in the right infra umbilical region which pointed more towards post laparoscopic port site hydatid cyst. The rest of the biochemical and hematological investigations were normal. The patient was managed surgically, liver hydatid cyst was deroofed through the right subcoastal (Kocher's) incision, with omentoplasty done. The port site hydatid cystectomy was done through a small incision of 4cm, 1cm lateral to the umbilicus on the right side. On exploration cystic swelling was seen with dense adhesions towards the old laparoscopic scar mark and the cyst was extraperitoneal, cyst was excised and the site was thoroughly washed with 0.5% cetrimide solution. Histopathological examination of both cyst walls showed the outermost peri cyst fibrous layer suggestive of hydatid cyst disease.

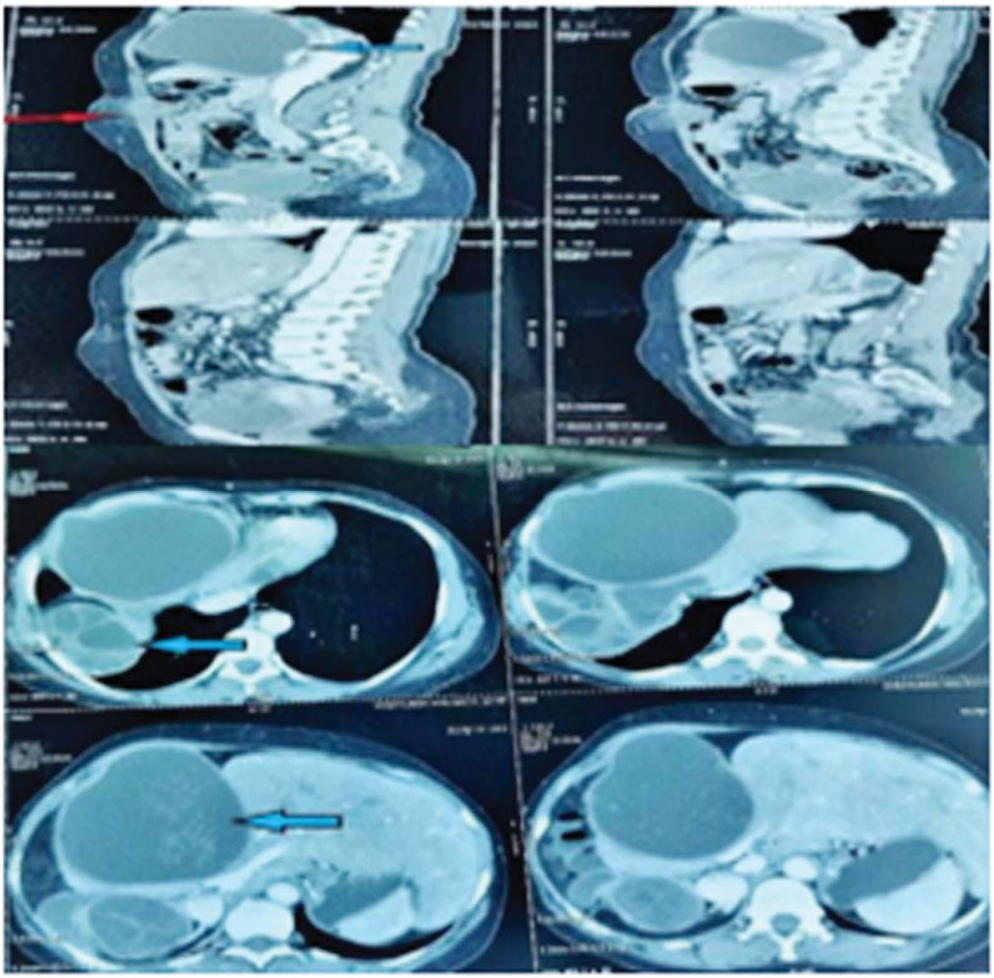

Fig. 7: Port site hydatid cyst (Red arrow), liver hydatid cyst (blue arrow).

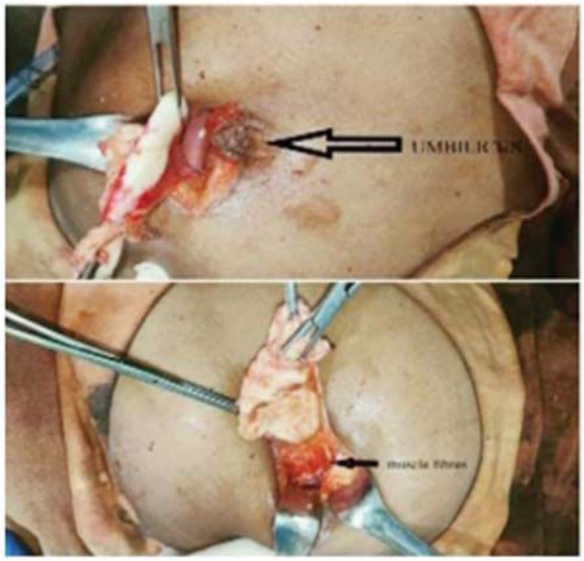

Fig. 8: Intra-operative port site hydatid cyst.

Case 8

A 40 year-old female presented with complaints of left hypochondriac region abdominal pain for the last 2 months. These were a history of fever and weight loss. She had a history of open deroofing of splenic hydatid cyst 8 years ago. Ultrasonography revealed a large cystic lesion with septas within at spleen pushing the stomach posteroinferior. CECT abdomen and pelvis were suggestive of non-enhancing exophytic lesions in the spleen. Oral albendazole 400 mg twice daily was given for 5 days preoperatively. Laparoscopic deroofing of recurrent splenic hydatid cysts was performed. Post-operatively Albendazole was also started on the first postoperative day. The patient's immediate recovery was remarkable and her symptoms were relieved completely.

DISCUSSION

Table 1: Different management approaches for different site of hydatid disease.

Sr. No.	Age/Sex	Presenting Complaints	Investigation	Location of Cyst	Management
1	22/F	Abdominal mass with pain	CECT (A+P)	1. Liver: Segment IVb	1. Deroofing of liver hydatid cyst along with uterine hydatid cyst.
				2. Right lower Pleural cavity	2. Thoracoscopy guided deroofing of right lung hydatid cyst along with capitonnage.
2	60/F	Abdominal pain with vomiting & jaundice	CECT (A+P)	1. Right lobe of the Liver	Open retrograde cholecystectomy with deroofing of liver hydatid cyst.
3	58/M	Abdominal pain with vomiting & fever	CECT (A+P)	1. Right lobe of the liver.	Exploratory laparotomy with deroofing of hydatid cyst
				2. Left iliac fossa.	
				3. Right paraumbilical region.	
				4. Supra umbilical region	
4	40/M	Abdominal pain	CECT (A+P)	1. Liver: segment VI, caudate lobe and right lobe	Exploratory laparotomy with deroofing of hydatid cyst with omentopexy
5	55/F	Abdominal pain	CECT (A+P)	1. Left lobe of liver	Exploratory laparotomy with Pericystectomy.
6	15/M	Abdominal pain with vomiting & abdominal distention	CECT (A+P)	1. Tail and body of pancreas.	Distal pancreatectomy with splenectomy.
7	40/F	Abdominal mass with pain	CECT (A+P)	1. Right lobe of Liver.	Deroofing of liver hydatid cyst through right subcostal Incision.
				2. Laparoscopic port site at anterior abdominal wall	Port site hydatid cystectomy through a small incision lateral to umbilicus on right side.
8	44/F	Abdominal mass with pain	CECT (A+P)	1. Spleen	Laparoscopic deroofing of splenic hydatid cyst.

Hydatid disease has a wide geographic distribution and is considered an important public health issue, mainly in developing countries. Hydatid cysts can involve different organs, mostly the lung, and liver, but it is also reported in other areas. They are usually asymptomatic depending on the size and the location involved.[1] In endemic areas, any patient presenting with a cystic mass, in any tissue or organ, should be considered a potential case of hydatid disease. Typically, cystic hydatidosis consists of a single unilocular cyst. However, in as much as 30% of cases, there may be synchronous multiple cysts located in the same or multiple organs.[2] The usual mode of acquiring the infection is through ingestion of contaminated vegetables. Symptoms are caused by pressure effects but are vague initially. Pain, cough, low-grade fever, and the sensation of abdominal fullness are common features. As the cyst grows, the symptoms become more specific depending on the specific structures involved.[3]

Diagnostic dilemmas with hydatid cysts at unusual sites can lead to complications as sometimes these may present as acute surgical emergencies or a chronic illness leading to morbidity.[4] Diagnosis of hydatid cysts can be made based on history of exposure, serological tests, and radiological images. Based on ultrasound imaging findings,

World Health Organization (WHO) developed cystic echinococcosis (CE) classification system. Computed tomography of the hydatid cysts has a high sensitivity (95–100%). Well circumscribed, hypo-dense round lesions without contrast enhancement can be seen in contrast enhanced CT. Calcification of the cysts can be present in 30% of all cases at the time of diagnosis. Besides radiological methods, serological tests are gaining popularity to confirm a suspected radiologic diagnosis. Serologic tests usually allow hydatid cysts to be distinguished from non-parasitic cysts and abscesses.[6] The diagnosis is often difficult when a hydatid cyst occurs at unusual locations as the imaging appearance varies at different sites.

Intra-abdominal hydatid disease may have a vague abdominal mass and pain due to pressure effects on adjacent organs or traction of the mesentery. The right upper abdominal or epigastric pain, nausea, vomiting, and hepatomegaly are common symptoms and signs of hepatic hydatid cyst. In one of our cases, the left iliac fossa hydatid disease might be due to the rupture of the daughter cyst from the main hepatic cyst to the peritoneum. Events as such have been mentioned in the literature.[7]

The reported prevalence of splenic involvement by hydatid disease varies from 0.9% to 8%. Hydatid disease is the only parasitic infestation of the spleen. Splenic cysts are often unilocular and do not pose difficulty in diagnosis in endemic areas. Splenic hydatid generally develops after systemic dissemination or intraperitoneal spread from a ruptured liver cyst. Splenectomy should be the method of choice and is considered the gold standard for hydatid spleen. Partial splenectomy with Omentoplasty may be reserved for cases with unrespectable cysts tightly adherent to adjacent structures.[2]

Hydatid cyst of the pancreas is rare and very difficult to distinguish from cystic neoplasm of the pancreas. It has been reported to affect the pancreas in 0.25% of patients of overall cases. The head of the pancreas is the most frequent location (57%), followed by the corpus (24%) and then the tail (19%).[2] Abdominal CT scan shows the presence of a cyst in the pancreas, with no enhancement in contrast. Magnetic resonance cholagio-pancreatography (MRCP) can show the communication of the cystic lesion with the pancreatic duct and helps in defining the type of surgical treatment. Magnetic resonance cholagiopancreatography (MRCP) can show the communication of the cystic lesion with the pancreatic duct and helps in defining the type of surgical treatment.[2, 5]

For small cysts (<5cm) or in inoperable cases, Benzimidazole compounds are commonly used. To reduce the risk of anaphylactic reactions and prevent recurrence, preoperative administration of Benzimidazole agents is recommended. Postoperative administration is also important.[6]

For the larger cysts with multiple daughter cysts and hydatidosis, rupture prone hydatid cysts, and all complicated cysts, surgery (laparoscopic or open) is the treatment of choice. The nature of the surgical intervention (pericystectomy, deroofing, capitonnage, hepatectomy, excision) has to be individualized for each patient. Although complete cyst excision with no spillage or cyst rupture is best it is not every time possible. In those situations, Pericystectomy or deroofing or capitonnage with or without Omentoplasty is accomplished.[5] Puncture, aspiration, injection, and respiration (PAIR) using scolicidal agents is also a good treatment option.

In our patients, based on the size and location of cysts the operative interventions had been planned. In the first patient concomitant presence of cyst was there in the liver and lungs, for which a two-stage procedure was planned. During the first setting for abdominal hydatid cyst removal, on exploration hydatid cyst from the uterine wall was also discovered for which deroofing of the cyst was done. Following this thoracoscopy guided deroofing of the right lung hydatid cyst along with capitonnage was performed after five weeks in the second set. In some of our patients, we have undergone exploration due to the large size of hepatic cysts and the simultaneous presence of multiple cysts in other abdominal organs also. Deroofing of liver hydatid cyst has been primarily done for most of our cases which yields us a very satisfactory outcome also. Pericystectomy has been performed in a case of a calcified cystic lesion present at the left lobe of the liver. In one patient with rare involvement of pancreatic body and tail, distal pancreatectomy was planned which on exploration found to involve splenic hilum also. We have also encountered a port site hydatid cyst which was removed with a small incision given at the lateral border. In a case of recurrent splenic hydatid cyst, we have performed a deroofing procedure under the laparoscopic procedure. In the end, we have to perform a splenectomy along with a distal pancreatectomy. In cases of splenectomy, to prevent OPSI proper vaccination has also been completed.

CONCLUSIONS

The occurrence of hydatid cysts in some locations of the body is very rare. These anatomic locations may cause difficulties in making the diagnosis. Hydatid disease should be kept in mind as a differential diagnosis of cystic lesions, especially for patients who belong to endemic regions. CECT should be considered before operative intervention to look for the size and specific location. Based on the diagnostic evidence a complete surgical removal should be planned. Complete cyst excision without spillage of contents has to be the mainstay of our surgical procedures.

REFERENCES

1. Wani RA, Wani I, Malik AA, Parray FQ, Wani AA, Dar AM. Hydatid disease at unusual sites. International Journal of Case Reports and Images 2012;3(6):1–6.
2. Kullolli GK, Vaidya MK, Patil R. Unusual Presentations of Hydatid Cyst - A Case Study. Int J Sci Stud 2017;5(1):218-222.
3. Zaidi, S.H. Some rare presentations of hydatid cysts: two case reports. Cases Journal 2, 62 (2009). https://doi.org/10.1186/1757-1626-2-62
4. Khanna AK, Prasanna GV, Khanna R, Khanna A. Unusual sites of hydatid cysts in India. Trop Doct 2005 Oct;35(4):233–5
5. Ozmen MM, Moran M, Karakahya M, Coskun F. Recurrent acute pancreatitis due to a hydatid cyst of the pancreatic head: a case report and review of the literature. JOP J Pancreas (Online) 2005;6:354–8
6. Tika Ram Bhandari, Sudha Shahi, "Simultaneous Hydatid Cyst of the Liver and Left Iliac Fossa: An Unusual Case Report", Case Reports in Surgery, vol. 2019, Article ID 9101425, 4 pages, 2019. https://doi.org/10.1155/2019/9101425
7. M. C. Safioleas, E. P. Misiakos, M. Kouvaraki, M. K. Stamatakos, C. P. Manti, and E. S. Felekouras, "Hydatid disease of Case Reports in Surgery 3 the liver: a continuing surgical problem," Archives of surgery, vol. 141, no. 11, pp. 1101–1108, 2006.