Case Report

Indian Journal of Dental Education
Volume 15 Number 1, January-March 2022
DOI: https://dx.doi.org/10.21088/ijde.0974.6099.15122.3

One Step Apexification using PRF as Matrix and MTA Apical Barrier

Swati Tomar[1], Ritika Malhotra[2], Hirojit[3], Akanksha Garg[4], Pankaj Datta[5]

Author's Affiliation: [1,3,4]PG Student, [2]Reader, [5]Dean, Department of Paedodontics & Preventive Dentistry, Inderprastha Dental College & Hospital, Ghaziabad 201010, Uttar Pradesh, India.

Corresponding Author: Pankaj Datta, Dean, Department of Paedodontics & Preventive Dentistry, Inderprastha Dental College & Hospital, Ghaziabad 201010, Uttar Pradesh, India.

E-mail: pankajdatta97@gmail.com

Received on: 31.08.2021

Accepted on: 22.01.2022

How to cite this article:
Swati Tomar, Ritika Malhotra, Hirojit, Akanksha Garg, Pankaj Datta/One Step Apexification using PRF as Matrix and MTA Apical Barrier/Indian J Dent Educ. 2022;15(1): 23-26.

Abstract

Carious exposure of young permanent tooth during the time of root development may lead to caseation of root completion, which leads to the absence of physiological apex closure and makes any endodontic treatment a challenge. For the success of the treatment and to create an apical barrier onto which obturating materials are condensed. This can be achieved in many ways traditionally; calcium hydroxide was used but due to drawbacks like long treatment duration and unpredictable results it is replaced by materials like mineral trioxide aggregate (MTA) and regenerative endodontics which appears as a newer modality to treat young permanent tooth with open apex. The only drawback is the over extrusion of MTA. To encounter that a favorable matrix is being used called Platelet-rich fibrin (PRF), this can be used as an apical matrix onto which MTA is condensed and an apical seal with favorable treatment outcomes can be achieved.

Key Messages: Young permanent tooth with open apex makes any endodontic treatment a challenging task. As a treatment modality MTA with an apical matrix barrier like PRF gives favorable results and a good apical seal can be achieved for the success of the treatment.

Keywords: Non-vital tooth; Mineral trioxide aggregate; One-step apexification; Immature tooth; Open apex; internal matrix; Platelet-rich fibrin.

Introduction

Trauma to the anterior teeth is a relatively common occurrence during childhood. Depending on its magnitude it may lead necrosis of the pulp tissue. Pulp necrosis of a young permanent tooth during the time of root development often leads to non-vitality and absences of natural apical constriction which leads to thin and fragile dentinal wall with open apices in which cleaning and shaping is very difficult. Also, conventional endodontic treatment is very difficult to proceed due to the inability to achieve a proper apical seal on which any obturating material can be condensed. Previously, many not-so-successful treatment options have been used as management option so practitioners focused on achieving a continued apical development by apexogenesis or apexification.[1] Apexification is a method of achieving an apical end closure of an immature permanent tooth. Out of the wide range of the materials, two have been shown successful results and successfully advocated as the choice of materials.[2] Calcium hydroxide apexification had a great clinical success rate, apical barrier form in 74% to 100% of the cases. The major drawbacks

here is cervical root fracture and a very long-term follow-up of an average of 12-19 months' time is required to achieve an apical seal in.[1,3] Altering these clinical setbacks, a newer material called mineral trioxide aggregate (MTA) is being used nowadays in an apexification procedure called one-step apexification in which MTA is used as an apical barrier. MTA shows promising results and has various advantages.[4]

The only drawback with MTA is the overfilling or under-filling of the canal. To overcome this a newer concept called the "internal matrix concept" was developed.[5] Platelet-rich fibrin (PRF) is a second-generation platelet-rich concentrate that is being used as a resorbable matrix material in open apex teeth onto which MTA can be placed. Choukroun et al. first described PRF shows various advantages like ease of preparation, accelerated wound healing, bone growth etc. This case report thoroughly described a case of an immature permanent tooth with an open apex and how its managed by using MTA apical barrier on a resorbable PRF membrane as an internal matrix.[6]

Case Report

An 11-year-old male patient, reported with a chief complaint of the upper front broken tooth with blackish discoloration. The patient gave an alleged history of fall two years back which leads to fracture and later blackish discoloration of the tooth. On extra-oral examination, there was no associated swelling. On intraoral examination right central incisor was discolored with Ellis class IV fracture (Fig. 1), there was no response to the vitality tests, periodontal examination of all the teeth showed probing depths within normal limits.

Fig. 1: Pre-operative picture showing fractured 11 with blackish discoloration.

A radiographic image revealed a foreign body inside the canal and also revealed an open apex with periapical radiolucency (Figure 2). The diagnosis was made as asymptomatic apical periodontitis with necrotic pulp. On the first visit informed written consent was taken from the parents.

Fig. 2: Pre-operative radiograph revealed a foreign body w.r.t[11]

Fig. 3: Foreign body removed from the canal.

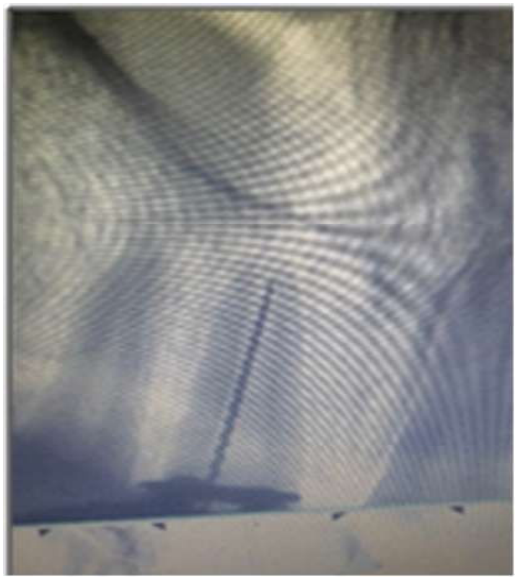

Fig. 4: Working length was determined.

Removal of foreign body was done using the H-file (Fig. 3). Working length was determined (Fig. 4) and after drying the canal calcium hydroxide as an intracanal medicament was placed in the canal and a closed dressing was given.

Fig. 5: Centrifuged patient's blood.

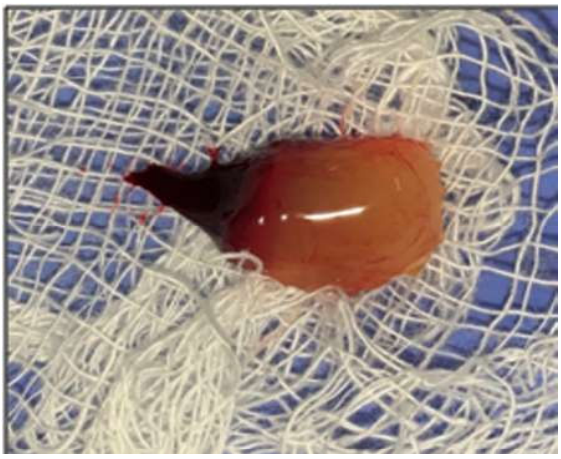

Fig. 6: Platelet rich fibrin.

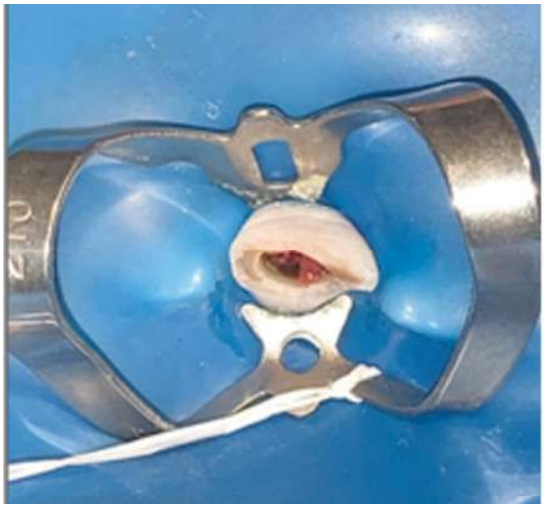

Fig. 7: Platelet rich fibrin in the canal.

On the second visit after one week tooth was reassessed and calcium hydroxide was removed and after that for the PRF preparation Choukrouns's technique was used. A volume of 8.5 ml blood was drawn from the cubital vein and collected in a 10 ml sterile glass tube with no anticoagulant, immediately it was transferred for centrifugation at 3000 revolutions/min (rpm) for 10 minutes.

After centrifugation, the glass tube shows three different layers (Fig. 5). PRF membrane was separated carefully and introduced in the canal to form an apical barrier (Fig. 6). MTA was mixed according to manufacturer instructions and was placed in the canal and condensed till 5 mm of apical thickness (Fig. 7). A wet cotton plug was placed and the cavity was sealed temporarily for 24 hours.

Fig. 8: 1 year post operatively showing complete apical closure.

On the third visit, the cavity was accessed and the cotton plug was removed and teeth was sealed with a permanent restoration of resin composite and was kept under follow-up. The patient was recalled for follow up postoperatively and after a 1 year follow up the radiograph showed healing of the lesion (Fig. 8).

Discussion

The utmost aim of an apexification procedure is to form an apical seal so as to prevent any toxins and bacteria from re-entering the periapical tissues from the root canal. Calcium hydroxide was the material of choice for apexification. Sheehy and Roberts reported that the use of calcium hydroxide for apical barrier formation was successful in 74-100% of cases. A study by El Meligy and Avery on

performing apexification with calcium hydroxide or MTA in 15 children shows persistent periradicular inflammation and tenderness to percussion was present at 6 months and 12 months in two of 15 teeth treated with calcium hydroxide and in none of the teeth treated with MTA.[7]

Another study by Bonte et al on non-vital permanent incisors requiring apexification a mineralized barrier was observed in 50% of the children in the calcium hydroxide group and 82% in the MTA group ($p < 0.07$) in 12 months follow-up. Also four of 15 teeth in the calcium hydroxide group developed root fractures compared with none in the MTA group. This makes MTA a superior choice over calcium hydroxide as aapexification agent. The only and the major drawback of MTA is the need to limit the over extrusion in the periapical area.[8]

Torabinejad et al. demonstrated that MTA implanted into the animal bone resulted in minimal inflammatory reactions with favorable bone healing with direct bone apposition.[9] To prevent this a restorable matrix has been used.PRF inherently contains moisture and serves as a good matrix material for the placement of MTA and shows completely healed periapical lesion with no signs of inflammation giving best possible results.

Conclusion

Combining PRF as a matrix with MTA shows promising results and is also considered a great option in one-step specification procedures. But even after all the possible results controlled clinical trials with larger sample sizes are still required so as to consider the predictability of the outcomes of this technique.

Conflict of interest

All authors declare that no conflicts of interest exist.

References

1. Andreasen JO, Flores MT. Injuries to developing teeth. In: Andreasen JO, Andreasen FM, Andersson L, editors. Textbook and Color Atlas of Traumatic Injuries to the Teeth. 4th ed. Copenhagen: Munksgaard; 2007. p. 542 76.
2. Morse DR, O'Larnic J, Yesilsoy C. Apexification: Review of the literature. Quintessence Int 1990; 21:589 98.
3. Cvek M. Prognosis of luxated non vital maxillary incisors treated with calcium hydroxide and filled with gutta percha. A retrospective clinical study. Endod Dent Traumatol1992; 8:45 55.
4. Simon S, Rilliard F, Berdal A, Machtou P. The use of mineral trioxide aggregate in one visit apexification treatment: A prospective study. Int Endod J 2007; 40:186 97.
5. Lemon RR. Nonsurgical repair of perforation defects. Internal matrix concept. Dent Clin North Am 1992; 36:439 57.
6. Dohan DM, Choukroun J, Diss A, Dohan SL, Dohan AJ, Mouhyi J, et al. Platelet rich fibrin (PRF): A second generation platelet concentrate. Part I: Technological concepts and evolution. Oral Surg Oral Med Oral Pathol Oral RadiolEndod 2006; 101:e37 44.
7. El-Meligy OA, Avery DR. Comparison of apexification with mineral trioxide aggregate and calcium hydroxide. Pediatr Dent. 2006 May-Jun;28(3):248-53.
8. E. Bonte, A. Beslot, T. Boukpessi, J.J. Lasfargues MTA versus Ca(OH)2 in apexification of non-vital immature permanent teeth: a randomized clinical trial comparison.Clin Oral Investig, 19 (2015), pp. 1381-1388.
9. Torabinejad M, Chivian N. Clinical applications of mineral trioxide aggregate. J Endod. 1999;25 3:197–205.