Original Article

RFP Journal of Dermatology
Volume 7 Number 1, January - June 2022

An Interventional Prospective Study on Microdermabrasion the Solution to a Variety of Dermatological Conditions

Hetal C Patel[1], Raksha Patel[2], Ashka D Shah[3], Grishma K Fumtiwala[4]

How to cite this article:

Hetal C Patel, Raksha Patel, Ashka D Shah, et al. An Interventional Prospective Study on Microdermabrasion the Solution to a Variety of Dermatological Conditions. RFP Journal of Dermatology 2022;7(1):5–9.

ABSTRACT

Introduction: Micrrodermabrasion (MDA) is an office procedure for various skin conditions with minimal invasion. This study's aim was to determine efficacy and side effects of MDA in different dermatoses.

Method: This was an interventional prospective study including 45 subjects.

Inclusion criteria pertained to cases having superficial acne scars, superficial wrinkling, mild to moderate acne with post inflammatory hyper pigmentation, acanthosis nigircans and melasma who were ready for regular follow up biweekly among other things. Pre-procedural care included avoidance of certain procedures and priming of skin was done. Detailed history, examination and investigations were done for all patients.

Bimanual technique for MDA was used after giving proper position to the patient. Series of multiple linear sweeping movements were done using handpiece. 2nd pass was carried out perpendicular to the first pass.

Post procedural instructions were vigilantly given.

Results: Out of the 45 cases enrolled, 20 were male and 25 were female of ages 11 to more than 40. No patients showed 100% improvement, minimal to moderate improvement was seen in maximum patients, while some patients of melasma, post acne scarring and mild to moderate acne showed no improvement at all.

Side effects like mild erythema persisting for one to two hours was seen in fifteen patients and irritation in eyes was seen in six patients which usually disappeared after washing.

Conclusion: MDA is a simple and safe office procedure suited for superficial resurfacing problems that does not interfere with normal activities of the patient and has minimal side effect.

Keywords: Body polishing; Non invasive; Acne scars; Hyperpigmentation; Bimanual technique ; Aluminium oxide; Office procedure

Author Afliation:

[1]Senior Resident, Sir Sayajirao General Hospital, Vadodara 390001, Gujarat, India [2]Head and Professor, [3,4]3rd Year Resident, Department of Dermatology, GMERS Medical College, Gotri, Vadodara 390021, Gujarat, India.

Corresponding Author:

Raksha Patel, Head and Professor, Department of Dermatology, GMERS Medical College, Gotri, Vadodara 390021, Gujarat, India.

Email: rakshamp@yahoo.co.in

Received Date: 12.11.2021

Accepted Date: 22.01.2022

INTRODUCTION

Microdermabrasion (MDA) popularly known as "body polishing" has been in trend since the past 20 years or so.[1] It is a minimally invasive epidermal resurfacing procedure used to treat uneven skin tones/textures, photoaging, striae, melasma and scars, including acne scars.[2] It is an office procedure and can be conveniently performed on outpatient basis.

As the name suggests, MDA literally means to wear away a small amount of superficial skin. It is a non-invasive non-surgical procedure used to revitalise and refresh skin.[3]

Abrasive crystals are propelled against the skin under the control of a handheld vacuum system, causing gentle mechanical abrasion of skin. New epidermis formed as a part of wound healing improves skin contour.[1]

The aim of this was to study the efficacy of MDA in different dermatoses and to study its adverse effects if any.

© Red Flower Publication Pvt. Ltd.

MATERIAL AND METHOD

This is an interventional prospective study. Cases amenable to conditions like superficial acne scars, superficial wrinkles, hyperpigmentation, acanthosis nigricans were considered. Informed consent was taken. Total 45 cases with various clinical conditions were included and MDA was performed as per the protocol.

A detailed history regarding onset, duration, aggravating factors, sun exposure profile was taken.

Past history of tendency of hypersensitivity and keloid, and history of using oral or topical isotretinoin was taken in detail.

Routine investigations like complete blood count, blood sugar, lipid profile and thyroid function tests were done.

Each patient was examined thoroughly for distribution, morphology and configuration of lesions.

Inclusion criteria

- Cases having superficial acne scars superficial wrinkling, mild to moderate acne with post inflammatory hyper pigmentation, acanthosis nigircans and melasma who were ready for regular follow up biweekly.
- Patients other than pregnant and lactating mothers.
- Patients who had not taken oral isotretinoin within last 1 year.
- No past history or family history of tendency of keloids or unusual scarring.

Patients were explained about the procedure and those who gave consent and were willing to come for regular treatment and follow up every two weeks up to 3 months were included.

Some patients having post inflammatory hyper pigmentation and post acne scarring were primed for 2 weeks with 0.012%- 0.025% topical retinoids for better results.

Pre procedure

The patients were informed about the procedure in simple terms and possible side effects were explained.

Waxing, tweezing, electrolysis, laser treatment, injection of collagen and botox, any kind of chemical peels and facials were to be avoided for minimum of 7 days before the procedure.

Products like alpha hydroxy acid, salicylic acid, retinoids and topical acne medication were asked to be discontinued 2 days before the procedure.

Priming was done with topical tretinoin (0.012%-0.025%) for 2 weeks and it was discontinued 2 days prior to the procedure.

Technique

Position: sitting if lesions were over neck, lying down if lesions were over face.

The hand piece was placed gently on the skin with its tip perpendicular to the skin surface.

Bimanual technique: stretch and steady the skin with one hand and move the hand piece gently with the other hand in a sweeping motion in the outward direction leaving uniform film of crystal on skin.

Series of multiple such linear sweeping movements were done segment wise to cover the entire face. Delicate skin over the eyelid and the vermillion border was not treated. Remaining aluminium oxide crystals were wiped before 2nd pass. 2nd set of pass was carried out in the direction perpendicular to the first set of pass with a similar technique.

Remaining crystals were wiped off and patients were instructed to clean the skin with water to remove any residue.

Moisturiser and sunscreen was applied locally after the procedure. The patient was allowed to step out 20 minutes after sunscreen application.

Post procedure

At home care: Clean and moisturise the skin twice daily, use broad spectrum sunscreen daily before sun exposure, topical tretinoin and hydroquinone crude to be started three days after MDA & stopped two days prior to the follow up procedure.

These treatments were done every fifteen days. A fore mentioned pre procedural instructions were given.

RESULTS

Out of the 45 cases enrolled, 20 were male and 25 were female of ages 11 to more than 40. (Table 1) 31% patients had mild to moderate acne with post inflammatory hyper pigmentation, 31% had acne scars. 11.1% had hyper pigmentation, 8.8% had

melasma, 8.8% had acanthosis nigricans and 8.8% had rhytides. (Image 1) No patients showed 100% improvement, minimal to moderate improvement was seen in maximum patients, while some patients of melasma, post acne scarring and mild to moderate acne showed no improvement at all. (Table 2) (Figure 1)

Side effects like mild erythema persisting for one to two hours was seen in 15 patients and irritation to eyes was seen in six patients which usually disappeared after washing the eyes.

Table 1:

Age (in years)	Sex		Total (n=45)
	Male n=20	Female n=25	
0-10	-	-	-
10-20	4	4	8
21-30	11	14	25
31-40	4	6	10
>40	1	1	2

Table 2:

Scale of Improvement	Conditions					
	Mild to moderate acne and post inflammatory hyperpigmentation	Post acne scarring	Hyper -pigmentation	Melasma	Acanthosis nigricans	Rhytides
	n=14	n=14	n=5	n=4	n=4	n=4
No (0%)	04 (28.5%)	03(20%)	-	02(50%)	-	-
Minimal (25%)	04(28.5%)	04(28.5%)	01(20%)	02(50%)	02(50%)	02(50%)
Moderate (50%)	07(46%)	07(50%)	02(40%)	-	02(50%)	02(50%)
Marked (75%)	-	-	02(40%)	-	-	-
Maximum (100%)	-	-	-	-	-	-

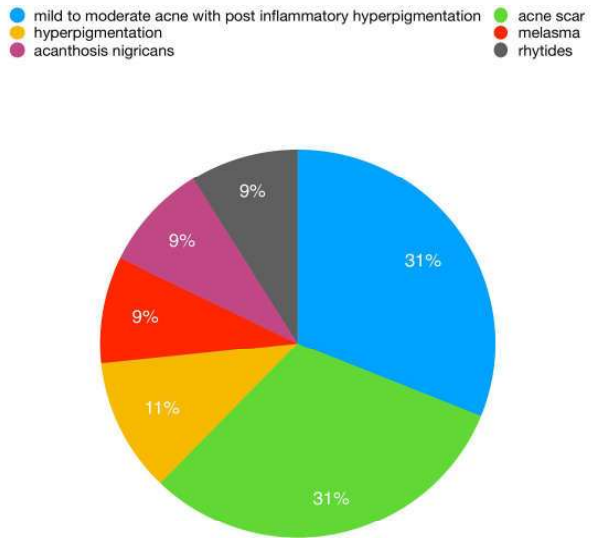

Fig. 1: pie chart showing indications for which microdermab .-rasion was done

DISCUSSION

Facial skin resurfacing can be traced back to Egyptian times, where royals sand blasted their skin in an attempt to rejuvenate their face.[4] From rocks, shells, pumice etc. used in the yester years to using the sophisticated MDA therapy now, this procedure has always been popular with the patients.[4] The principal behind MDA has been the same throughout the timeline.[1]

In the current scenario, MDA is indicated in a lot of conditions like superficial acne scars, post inflammatory hyper pigmentation, rejuvenation of photo damaged skin and blemished skin, stretch marks, melasma, acanthuses nigricans and many more. (grimes 2006)

In this procedure aluminium oxide crystals or other abrasive substances are blown onto the face and then vacuumed off, using a single handpiece.[1] The depth of the peel can be variable, but most of the times only the stratum corneum of the epidermal layer is abraded.[1,6] This depth depends upon the particle size and the speed of the handpiece. With only mild erythema(redness)and oedema (swelling) there is minimal downtime making MDA a lunchtime procedure.[1,6]

Sodium chloride, sodium bicarbonate and magnesium oxide crystals are cheaper options which can be used. On the downside these are less effective.[5,6]

Amongst non-crystal methods diamond tipped devices are the most recent ones. These are preferred by the patient due to lesser pain and are better for us as they require lesser maintenance, shorter procedure time, and are more hygienic.[1, 7]

The ultimate results are due to a combination of mechanical disruption of stratum corneum, partial epithelization and stimulation of epidermal turnover, vasodilatation of dermal blood vessels, dermal oedema and remodelling of dermal collagen.[4,5,8]

Histopathologically, thinning of stratum corneum, increased thickness of dermis and epidermis, even and regular distribution of melanosomes, flattening of rete ridges and remodelling of collagen, elastic tissue and dermal oedema is seen, Vascular ectasia with perivascular mononuclear cellular infiltrate is seen too.[3,5,6] (Fig. 1)

MDA should be strictly avoided in inflammatory acne, active bacterial or viral infection, incase of keloidal tendency, and history of use of isotretinoin in last one year.[5,9]

Side effects like erythema, oedema, increased skin sensitivity, petechiae, purpura, drying, transient hyper pigmentation, blue grey discolouration, infection, acute urticarial reaction, scarring, foreign body reaction to aluminium chloride crystals, respiratory-pulmonary fibrosis, ophthalmic-conjunctival congestion, eye irritation, superficial punctate keratitis can be troublesome.[1,9,10]

The process is painless, requiring no down time and hence barely affecting the patients social life. The procedure can be repeated at short intervals, thus allowing us to evaluate the obtained result and then deciding the timing for further sittings. It is a simple procedure that does not required any anaesthetic.[11]

Spencer et al noted minimal response in 7 out of 10 cases, and mild response in 2 out of 5 cases in his study on MDA in hyper pigmentation.[12]

A study carried out by Dr. Maggie Schwarz at new york, has shown excellent efficacy for MDA in treating melasma when a combination depigmenting regimen is added. According to the results of a study of 50 patients with melasma, at 2 years of follow up, 20% patients reported more than 95% clearing and 60% reported 60%-95% clearing of melasma.[13]

Arielle et al reported successful treatment of melasma using a combination of MDA and Q-Switched Nd:YAG Lasers.[14]

In a study carried out by coimbra m, 20 patients with rhytides with a series of eight MDA treatments at 1 week intervals were enrolled. 17 subjects completed the entire study protocol. They observed improvement in fine rhytides. All patients were very satisfied with the treatment.[15]

Hence it can be said that MDA is a painless lunchtime procedure with minimal side effects, and is safe in fitzpatrick skin types 4 and 6. It can be repeated at short intervals as and when needed without disrupting the patients social life.

CONCLUSION

MDA is a simple and safe office procedure that does not interfere with normal activities of the patient and has minimal side effect.

MDA seems to be a legitimate resurfacing technology that is particularly suited for superficial resurfacing problems such as fine lines, mild acne scars and hyperpigmentation.

It is a non-aggressive technique with a high safety profile. It is a slow acting procedure which requires repeated maintenance sessions for continued effect.

Conflicts of Interest: None.

Financial Support and Sponsorship: None.

Consent for Publication: Not applicable.

REFERENCES

1. Savardekar P. MDA. Indian J Dermatol Venereol Leprol 2007;73:277-9.
2. Shah M, Crane JS. MDA. 2021 Apr 20. In: StatPearls [Internet]. Treasure Island (FL): StatPearls Publishing; 2021 Jan–. PMID: 30571004.
3. Tan MH, Spencer JM, Pires LM, Ajmeri J, Skover G. The evaluation of aluminum oxide crystal MDA for photodamage. Dermatol Surg. 2001 Nov;27(11):943-9. doi: 10.1046/j.1524-4725.2001.01120.x. PMID: 11737128.
4. Savant SS. Microdermabrasion, Textbook of Dermatosurgery and Cosmetology. 2nd Edition 2005, Mumbai, ASCAD, page no. 620-625.
5. Grimes PE. Microdermabrasion. Dermatol Surg. 2005 Sep;31(9 Pt 2):1160-5; discussion 1165. doi: 10.1111/j.1524-4725.2005.31922. PMID: 16176767.
6. Mark G. Rubin, MD, Microabrasion: An Epidermal Abrasion, Aesthetic Surgery Journal, Volume 23, Issue 2, March 2003, Pages 137–139.

7. Kim HS, Lim SH, Song JY, Kim MY, Lee JH, Park JG, Kim HO, Park YM. Skin barrier function recovery after diamond microdermabrasion. J Dermatol. 2009 Oct;36(10):529-33. doi: 10.1111/j.1346-8138.2009.00695.x. PMID: 19785706.
8. Spencer JM. Microdermabrasion. Am J Clin Dermatol. 2005;6(2):89-92. doi: 10.2165/00128071-200506020-00003. PMID: 15799680.
9. Shim EK, Barnetter D, Hughes K et al. Microdermabrasior: A Clinical and Histopathological Study. Dermatologic Surgery 2001, 27(6): 524-530.
10. Newman J et al power peeling. Int J Cosmet surg 1999;6:101-105.
11. Tsai RY, Wang CN, Chan HL. Aluminum oxide crystal microdermabrasion. A new technique for treating facial scarring. Dermatol Surg. 1995 Jun;21(6):539-42. doi: 10.1111/j.1524-4725.1995.tb00258.x. PMID: 7773601.
12. Spencer JM. Microdermabrasion. Am J Clin Dermatol. 2005;6(2):89-92. doi: 10.2165/00128071-200506020-00003. PMID: 15799680.
13. By Maggie Schwarz, Microdermabrasion plus triple-combination therapy successful in treating Melasma, available from http://www.pslgroup.com/dg/244ACE.htm. Last cited on 2007, November 5th.
14. Kauvar AN. Successful treatment of melasma using a combination of microdermabrasion and Q-switched Nd:YAG lasers. Lasers Surg Med. 2012 Feb;44(2):117-24. doi: 10.1002/lsm.21156. Epub 2012 Jan 3. PMID: 22334295.
15. Coimbra M, Rohrich RJ, Chao J, Brown SA. A prospective controlled assessment of microdermabrasion for damaged skin and fine rhytides. Plast Reconstr Surg. 2004 Apr 15;113(5):1438-43; discussion 1444. doi: 10.1097/01.prs.0000113026.94292.0b. PMID: 15060359.