

## REVIEW ARTICLE

# Bladder Cancer: The Role of Immunohistochemistry in the Era of Metabolomics

Devajit Nath<sup>1</sup>, Subhalakshmi Saikia<sup>2</sup>**HOW TO CITE THIS ARTICLE:**

Devajit Nath, Subhalakshmi Saikia, Bladder Cancer: The Role of Immunohistochemistry in the Era of Metabolomics. Ind Jr of Path: Res and Practice 2025;14(1) 13–20.

**Abstract**

Bladder cancer is a challenging urological malignancy with a high likelihood of recurrence, making it difficult to treat. Metabolomics is a promising approach for the detection and treatment of bladder cancer, as it helps understand metabolic alterations linked to the disease. Metabolomics research uses two methodologies: immunohistochemistry and metabolomics. Metabolomics studies the metabolic patterns of biological material, including essential molecules like glucose, lipids, and amino acids. It serves several objectives, including biomarker discovery, pathway identification, and treatment targets.

Immunohistochemistry is crucial in bladder cancer research, as it uses antibodies to identify and detect specific proteins in tissue samples. It helps in protein expression analysis, tumor microenvironment assessment, and classifying bladder cancer subtypes. Combining metabolomics and immunohistochemistry allows for a more profound understanding of the pathology, leading to improved therapy, diagnosis, and treatment. This comprehensive understanding of bladder cancer can lead to improved prognosis for those dealing with this complex ailment.

**KEYWORDS:**

• Bladder Cancer • Immunohistochemistry • Metabolomics

**INTRODUCTION**

Bladder cancer (BC) is the predominant malignancy affecting the urogenital tract. There is a global population of around 1.6 million individuals who

have been diagnosed with BC. It is projected that the United States would have a surge of over 80,000 new cases and 17,000 fatalities in 2022<sup>1</sup> Upon first diagnosis, over 75% of individuals are found to have non-muscle invasive bladder cancer (NMIBC),

**AUTHOR AFFILIATION:**

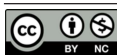
<sup>1</sup>Additional Professor, Department of Pathology, <sup>2</sup>Attending Consultant, Department of Radiation Oncology, Postgraduate Institute of Child Health, Noida, Uttar Pradesh 201310, India.

**CORRESPONDING AUTHOR:**

**Devajit Nath**, Additional Professor, Department of Pathology, Postgraduate Institute of Child Health, Noida, Uttar Pradesh 201310, India.

E-mail: devajit\_nath@yahoo.co.in

Received on: 21.02.2025 Accepted on: 04.04.2025



whereas the remaining individuals have muscle invasive bladder cancer (MIBC) or metastatic illness.<sup>2</sup> Bladder cancer (BC) is more likely to occur in those with a genetic predisposition, those who have been exposed to benzene chemicals, older individuals, those who have undergone pelvic radiation, and cigarette smokers.<sup>3</sup>

The most common kind of urothelial cancer, known as BC, can be classified using TNM staging methods, which include stages ranging from Ta (non-invasive carcinoma) to T4 (extravesical invasion), according to the World Health Organisation (WHO) guidelines from 2016.<sup>3,4</sup>

Pathologists and oncologists face challenges in accurately staging patients due to histological characteristics that resemble different stages or cancers in nearby organs with bladder invasion.<sup>5</sup>

The clinical implications of non-muscle-invasive bladder cancer (NMIBC) and muscle-invasive bladder cancer (MIBC) are distinct due to their divergent approaches to prognosis, therapy, and biomarkers.<sup>6,7</sup>

Bladder cancer is predominantly urothelial origin and accounts for ninety percent of cases. Some of its features include dysplasia, carcinoma in situ (CIS), invasive urothelial carcinoma, and metastatic cancer.<sup>5</sup> The diagnosis is made by clinical evidence, which can present as either extensive, severe hematuria or as microscopic, painless hematuria. Various techniques can assist in the clinical diagnosis and prognosis in this scenario.

Pathologists have determined that immunohistochemistry (IHC), a procedure that involves examining tissue samples, is valuable for both diagnosing cancer and predicting prognosis. It is extensively utilised in cancer research. Coons *et al.* (1941) discovered that it is possible to identify specific antigens in mammalian tissues by using antibodies that are labelled with a fluorescent group.<sup>8</sup> The IHC technique has been improved by including monoclonal and polyclonal antibodies that target tumour antigens, along with the utilisation of advanced technologies such as multiplex IHC or immunofluorescence. Immunohistochemistry (IHC) employs primary or secondary antibodies to bind to specific biological components of interest inside a tissue sample. These constituents might be located inside the cytoplasm, nucleus, extracellular matrix, cell membrane, or other organelles. The tissue is stained with a particular antibody following its fixation in paraffin. 3,3'-Diaminobenzidine tetrahydrochloride (DAB) is the chromogen that is most commonly utilised.<sup>9</sup>

While IHC is a cost-effective and readily accessible technique, not all patients can yet get therapeutic benefits from molecular categorization. In Bladder Cancer, it is crucial to stage and determine the origin of metastatic tumours for the differential diagnosis and classification of MIBC and NMIBC.<sup>7</sup>

Several indicators are being utilised in clinical settings; however, they are still unable to distinguish between all probable stages and types of BC.<sup>5,10,11</sup>

The markers encompass GATA3, CK20, CK5/6, CK14, and CK5. The use of these markers' immunohistochemical (IHC) staining is crucial for the identification of tissue organisation, determination of cancer stage, and prediction of clinical outcomes.<sup>5,12-14</sup> It is necessary to classify BC into luminal and basal subtypes for therapeutic purposes because to their distinct functions and impact on prognostic prediction.<sup>5</sup>

Luminal BC has lower invasiveness and metastatic potential compared to basal BC, despite its reduced sensitivity to standard chemotherapeutic treatments.<sup>15-17</sup>

## KEY IHC INDICATORS FOR CLINICAL APPLICATIONS

### CYTOKERATIN

The outermost and middle cells of the bladder lining express cytokeratins. The atypical expression of this molecule is associated with a worse prognosis.<sup>18</sup> The co-expression of Ki-67 with CK20, which is found in umbrella cells, exhibits a relatively lower correlation with the progression of the disease when compared to isolated CK20 expression which is related with relapse and an increase in cell proliferation.<sup>19,20</sup> The presence of CK5/6 expression in basal progenitor cells has been linked to both inflammatory and aggressive behaviour, as well as increased susceptibility to chemotherapy.<sup>21-23</sup> The variation in cytokeratin expression may also impact the tumor's response to therapy, as demonstrated by Lu *et al.*<sup>24</sup> CK14, a unique basal marker, accurately differentiates between BC subtypes.<sup>25</sup> Consistent with previous research, the study conducted by Al-Sharaky *et al.*<sup>22</sup> assessed CK14 as a distinguishing marker for bladder cancer. By analysing ninety BC samples, this group discovered that individuals with a phenotype characterised by the simultaneous presence of CK5 and CK14, and the absence of CK20 (CK5+CK14+CK20-), had a higher degree of aggressiveness and/or invasiveness towards muscle tissue compared to those who lacked CK14 (CK5+, CK14-, CK20-).<sup>22</sup>

Other studies have also shown similar results, indicating a negative correlation between CK14 and worse overall survival, cancer-specific survival, and recurrence-free survival.<sup>26</sup>

### **GATA3**

The transcription factor GATA3 protein affects haematopoiesis, T-cell formation, proliferation, and epithelial tissue differentiation. It has been established that GATA3 is a relevant biomarker. Previously, it was used together with CK20 to identify the luminal type of breast cancer and was found to be correlated with mRNA expression in 80% of the cases.<sup>23</sup> Therefore, in a disease-causing situation, GATA3 is frequently used to differentiate it from the basal subtype, which is typically identified as CK5/6 positive. However, Wang et al. demonstrated that samples displaying co-expression of both luminal and basal markers may occur in instances with MIBC.<sup>27</sup>

Co-expression of the markers was seen in 48.35% of the MIBC samples in this investigation involving 91 patients. Irrespective of the stage and spread of cancer, increased expression of GATA3 is associated with better chances of not experiencing a recurrence of the disease. Conversely, lower levels of GATA3 staining are associated with a negative prognosis and worse overall survival rates. This may help identify individuals who might benefit from a radical cystectomy. Among the indicators often analysed in research studies, GATA3 has repeatedly shown to be a luminal marker that is strongly linked to clinical outcome.<sup>26,27</sup>

### **P53:**

The expression of the TP53 tumour suppressor gene is modified, inhibiting both genomic instability and growth suppression, two crucial elements for tumour formation.<sup>28,29</sup>

Furthermore, BC has the altered expression of p53 with nuclear accumulation and mutations.<sup>30</sup> p53 staining patterns in BC include absence of staining (null staining) and the accumulation of p53 protein in the cell nucleus.<sup>27</sup> The majority of research fail to demonstrate a link between p53 expression and clinical outcomes such as progression, recurrence, or grade.<sup>27,30,31</sup> A standard procedure is to examine p53 alongside additional IHC markers, such as DDX31, Ki-67, pRb, or p21. These findings have implications for the clinical assessment of p53.<sup>27,31-33</sup>

Study conducted by Daizumoto *et al.*<sup>32</sup> found that there was no association between the expression of p53 protein detected by immunohistochemistry (IHC) and the grading or TNM classification system in 77 BC samples. However, they did find

a correlation between p53 expression and cancer specific survival. Semeniuk-Wojtas *et al.*<sup>34</sup> have shown an independent correlation between p53 and cancer recurrence survival. Lloreta *et al.* discovered a correlation between the expression of p53 and the advanced stage, progression, and recurrence of tumours after examining 162 samples of bladder cancer.<sup>35</sup>

### **Ki-67**

The proliferation marker Ki-67 has a negative correlation with basal NMIBC(CK5+) and a positive correlation with luminal NMIBC(CK20+). This correlation for the chance of cancer recurrence and the aggressiveness of cancer cells is well-established.<sup>19,20,36,37</sup> Previous studies have shown that there is a correlation between Ki-67 and clinical outcomes, as well as staging and grading. Han<sup>38</sup> and his colleagues not only categorised 48 bladder cancer samples into luminal and basal subtypes, but also identified a distinct basal subtype known as the Claudin-Low Subtype (CLS). This subtype was characterised by the presence of markers indicating immune infiltration and the epithelial-to-mesenchymal transition (EMT). Consequently, CLS exhibited poor prognostic outcome and was associated with greater levels of Ki-67 compared to other subtypes of bladder cancer.<sup>38</sup> In addition, Ziaran et al. suggested using Ki-67 expression evaluation for risk categorization in non-muscle invasive bladder cancer (NMIBC), since it has previously been linked to worse outcomes in predicting cancer recurrence in pT1 stages.<sup>31</sup>

Ki-67 thereby demonstrates promising clinical use as an immunohistochemical (IHC) marker for bladder cancer prognosis.

### **UPII**

The uroplakins (UPs) are a group of four proteins that are found on the top surface of the urothelium. They play a crucial role in maintaining the balance and stability of the bladder lining. UPII has recently revealed high sensitivity and specificity for detecting urothelial bladder cancer. It has been consistently linked to luminal BC and serves as a strong marker of distinction from basal BC.<sup>13</sup> The study conducted by Lu et al. discovered that CK20 was more proficient in differentiating between various luminal profile types, which exhibited distinct clinical outcomes, and in determining the presence of UPII in both subtypes.<sup>24</sup>

Leivo *et al.*<sup>39</sup> conducted a comparison between UPII and GATA3 to evaluate UPII's ability to differentiate urothelial carcinoma from other conditions that resemble bladder cancer, including

nephrogenic adenoma, papillary nephrogenic adenoma, endometriosis/ endosalpingiosis, inflammatory myofibroblastic tumour, ectopic prostate tissue, and malakoplakia.<sup>40</sup> This study showed that UPII had a high level of specificity for urothelial lesions, while GATA3 stained for the majority of similar conditions (59%), even though there were only a small number of samples for each similar condition.<sup>40</sup> To summarise, UPII staining may exhibit similarities with CK20 studies in many subtypes of breast cancer. However, it can still serve as a valuable immunohistochemical (IHC) technique for distinguishing bladder cancer from malignancies originating in other organs.

## IHC EXPRESSION OF NEW BC BIOMARKERS

The HER-2 or ERBB2 gene is situated on the q arm of human chromosome 17, and it serves as the innovative immunohistochemistry biomarker.<sup>40</sup> The presence of constitutive activation pathways in breast, lung, bladder, and stomach malignancies leads to an excessive expression of this biomarker. This, in turn, stimulates cellular proliferation and increases the likelihood of carcinogenesis.<sup>41,42</sup>

The overexpression of HER-2 as a luminal marker in bladder cancer has been recognised as hallmark for the illness from its initial publication in 1990, suggesting its potential use as a prognostic or diagnostic marker.<sup>29,43</sup> HER-2-targeted treatment is still in its early stages for BC. Cimpean *et al.*<sup>44</sup> employed the immunohistochemistry (IHC) technique to examine the HER-2 expression in a total of 45 samples. It was discovered that this protein was linked to lymphovascular involvement and had a role in the invasion of urothelial tumours, as shown by IHC scores of +2 and +3. HER-2 overexpression was determined to be a more dependable predictor of disease-free survival compared to prognostic variables such as sex, tumour size/number of recurrences, and use of BCG treatment.<sup>45</sup> Li *et al.* found that 37.5% of the 56 samples of bladder transitional cell carcinoma tested positive for HER-2 compared to non-cancer samples. They also observed a correlation between the expression of HER-2 and the stage of bladder cancer.<sup>46,47</sup> Through the analysis of several subtypes of BC and their reaction to innovative therapies that focus on tyrosine kinase receptors, Wucherpfennig *et al.* discovered that 95% of the squamous differentiated BC cases showed positivity for EGFR and would benefit from anti-HER2 therapy.<sup>48</sup>

Hence, further research of this molecule and its correlation with BC subtyping is imperative to determine its potential efficacy as a prognostic and therapy selection predictor, despite the evident manifestation of HER-2 overexpression in BC.

### PD-1 and PD-L1

Suppression of the PD-L1 and PD-1 immune checkpoints has been found to be beneficial in neoadjuvant and adjuvant treatment for cancer. This is because stromal cells play a crucial role in the development and spread of tumours.<sup>49</sup> When combined with PD-L1, sometimes referred to as B7-H1, PD-1 functions as a mediator of programmed cell death and inhibits the activation of T cells.<sup>50,51</sup>

Monoclonal antibodies have been investigated as a possible treatment for PD-1-expressing cancers in the development of innovative cancer therapeutics, as these malignancies have been linked to immune system evasion.<sup>52</sup> The FDA granted approval to atezolizumab in 2016 as the initial PD-L1 inhibitor for the treatment of urothelial carcinoma.<sup>53</sup> Atezolizumab exhibited favourable effectiveness and acceptable safety in patients with pre-existing local, advanced, or metastatic BC, which was linked to increased PD-L1 expression in lymphocytes that invade the tumour.<sup>52</sup> To summarise, immunotherapy that focuses on immunological checkpoints like PD-L1 or PD-1 might be advantageous for patients with immunotype A. Hence, PD-1 and its ligand are widely recognised as prime targets for immunotherapy, and evaluating their expression using IHC is essential for determining treatment approaches and prognosticating outcomes.

### E-Cadherin

The occurrence of invasion and metastasis is contingent upon the epithelial-mesenchymal transition (EMT) of E-Cadherin. For cancer to undergo epithelial-mesenchymal transition (EMT) and phenotypic flipping, modifications to cell-cell adhesion molecules are necessary. This is because E-cadherin, which is responsible for cell adhesion, is downregulated in several forms of cancer.<sup>54,55</sup>

The expression of E-cadherin was strongly associated with the progression of the tumour stage. It was shown to be negative ( $p < 0.001$ ) in all instances of pT3 and pT4, but positive in 20% of pT1 patients.<sup>56</sup>

The reduced expression of the E-cadherin marker is associated with low survival rates and invasiveness, suggesting that it might serve as a useful prognostic predictor in BC research. Additional study is required to demonstrate the efficacy of this survival predictor

and to establish consensus about its implementation in clinical settings.

### SOX-2

Stem cell markers are often investigated in cancer research because to their similarity to some tumour cells, particularly during the periods of self-renewal and poor differentiation, which are referred to as cancer stem cells (CSC).<sup>57,58</sup> The gene SOX-2, located on chromosome 3, plays a crucial role in the characteristics of stem cells, embryonic development, and the advancement of cancer.<sup>59,60</sup> Prior research has established a strong correlation between elevated expression of this cancer stem cell (CSC) marker and unfavourable outcomes in BC, including poor prognosis, tumour size and grade, muscle invasion, and low recurrence-free survival.<sup>61,62</sup>

The neuroendocrine phenotype represents an aggressive variant of bladder cancer, and the detection of SOX2 in neuroendocrine-like tumours suggests their progression towards this phenotype.<sup>62</sup>

This research is significant since it explores the potential for early detection of neuroendocrine tumours and offers suitable treatment options for affected individuals.<sup>63</sup>

However, the authors emphasised the difficulties in identifying the CSC population in BC when utilising the IHC approach to assess low-grade, high-grade, and MIBC.<sup>64</sup> This is due to the fact that CSCs constitute a relatively minuscule portion of the tissue. The field of CSC biomarkers, like as SOX2, is both captivating and stimulating. However, using them in a clinical setting using the IHC technique remains challenging.

### CONCLUSION

Conclusively, the task of establishing criteria for IHC staining indications in bladder cancer can pose difficulties. Pathologists have increased difficulty in diagnosing and prognosing patients when using IHC technology, determining marker combinations, and establishing cut-off values for each marker. Various studies demonstrate that the variety of bladder cancer poses challenges in classifying subtypes as either luminal or basal. Consequently, even the markers now used in clinical settings for bladder cancer were unable to offer a consistent recommendation across the publications. There is emphasis in ensuring the accessibility of newly identified biomarkers for utilisation in clinical environments, enabling promising treatment

for bladder cancer. Given the favourable results obtained from HER-2 and PD-L1 staining, it is imperative to conduct more investigations on novel biomarkers

*Conflict of Interest:* None

*Funding:* Nil

### REFERENCES

1. Siegel RL, Miller KD, Fuchs HE, Jemal A. Cancer statistics, 2022. *CA Cancer J Clin* (2022) 72:7-33. doi: 10.3322/caac.217081
2. Smith AB, Deal AM, Woods ME, Wallen EM, Pruthi RS, Chen RC, et al. Muscle-invasive bladder cancer: evaluating treatment and survival in the national cancer data base. *BJU Int* (2014) 114:719-26. doi: 10.1111/bju.12601
3. Lenis AT, Lec PM, Chamie K. Bladder cancer: A review. *J Am Med Assoc*. 2020;324(19):1980-91.
4. Kirkali Z, Chan T, Manoharan M, Algaba F, Busch C, Cheng L, et al. Bladder cancer: Epidemiology, staging and grading, and diagnosis. *Urology*. 2005;66(6 Suppl 1):4-34.
5. Akgul M, MacLennan GT, Cheng L. The applicability and utility of immunohistochemical biomarkers in bladder pathology. *Hum Pathol*. 2020;98:32-55.
6. Witjes JA, Bruins HM, Carrión A, Cathomas R, Compérat EM, Efstathiou JA, et al. EAU Guidelines on Muscle-invasive and Metastatic Bladder Cancer. In: *EAU Annual Congress Amsterdam*. Amsterdam: EAU Guidelines; 2022.
7. Babjuk M, Burger M, Gontero P, Liedberg F, Palou J, van Rhijn BWG. EAU Guidelines on Non-muscle-invasive Bladder Cancer (TaT1 and CIS). In: *EAU Annual Congress Amsterdam*. Amsterdam: EAU Guidelines; 2022.
8. Coons AH, Creech HJ, Jones RN. Immunological properties of an antibody containing a fluorescent group. *Proc Soc Exp Biol Med*. 1941;47(2):200-2.
9. Sukswai N, Khoury JD. Immunohistochemistry innovations for diagnosis and tissue-based biomarker detection. *Curr Hematol Malig Rep*. 2019;14(5):368-75.
10. Razzaghdoust A, Ghajari M, Basiri A, Torbati PM, Jafari A, Fattahi M-R, et al. Association of immunohistochemical markers of tumor subtype with response to neoadjuvant chemotherapy and survival

- in patients with muscle-invasive bladder cancer markers of chemotherapy response in bladder cancer. *Investig Clin Urol.* 2021;62(3):274-81.
11. Cox RM, Magi-Galluzzi C, McKenney JK. Immunohistochemical pitfalls in genitourinary pathology: 2018 Update. *Adv Anat Pathol.* 2018;25(6):387-
  12. Akhtar M, Rashid S, Ben GM, Taha M, Al Bozom I. CK20 and CK5/6 immunohistochemical staining of urothelial neoplasms: A perspective. *Adv Urol.* 2020;2020;4920236.
  13. Ikeda J, Ohe C, Yoshida T, Kuroda N, Salto R, Kinoshita H, et al. Comprehensive pathological assessment of histological subtypes, molecular subtypes based on immunohistochemistry, and tumor-associated immune cell status in muscle-invasive bladder cancer. *Pathol Int.* 2021;71(3):173-82.
  14. Bejananda T, Kanjanapradit K, Saetang J, Sangkhathat S. Impact of immunohistochemistry-based subtyping of GATA3, CK20, CK5/6, and CK14 expression on survival after radical cystectomy for muscle-invasive bladder cancer. *Sci Rep.* 2021 Oct 27;11(1):21186. doi: 10.1038/s41598-021-00628-5. PMID: 34707176; PMCID: PMC8551252.
  15. Labban M, Najdi J, Mukherji D, Abou-Kheir W, Tabbarah A, El-Hajj A. Triple-marker immunohistochemical assessment of muscle-invasive bladder cancer: Is there prognostic significance? *Cancer Reports (Hoboken).* 2021;4(2):e1313.
  16. Choi W, Czerniak B, Ochoa A, Choi W, Czerniak B, Ochoa A, Su X, Siefher-Radtke A, Dinney C, et al. Intrinsic basal and luminal subtypes of muscle-invasive bladder cancer. *Nat Rev Urol.* 2014;11(7):400-10.
  17. Choi W, Porten S, Kim S, Willis D, Plimack ER, Hoffman-Censits J, et al. Identification of distinct basal and luminal subtypes of muscle-invasive bladder cancer with different sensitivities to frontline chemotherapy. *Cancer Cell.* 2014;25(2):152-65.
  18. Dadhania V, Zhang M, Zhang L, Bondaruk J, Majewski T, Siefher-Radtke A, et al. Meta-analysis of the luminal and basal subtypes of bladder cancer and the identification of signature immunohistochemical markers for clinical use. *eBioMedicine.* 2016;12:105-17.
  19. Ranzi AD, da Silva JNL, Graziottin TM, Anells N, Bica CG. Immunohistochemistry biomarkers in nonmuscle invasive bladder cancer. *Appl Immunohistochem Mol Morphol.* 2017;25(3):178-83.
  20. Breyer J, Wirtz RM, Otto W, Erber P, Kriegmair MC, Stoehr R, et al. In stage pT1 Non-Muscle-Invasive Bladder Cancer (NMIBC), high KRT20 and low KRT5 mRNA expression identify the luminal subtype and predict recurrence and survival. *Virchows Arch.* 2017;470(3):267-74.
  21. Dadhania V, Zhang M, Zhang L, Bondaruk J, Majewski T, Siefher-Radtke A, et al. Meta-analysis of the luminal and basal subtypes of bladder cancer and the identification of signature immunohistochemical markers for clinical use. *eBioMedicine.* 2016;12:105-17.
  22. Al-Sharaky DR, Abdelwahed M, Asaad N, Foda A, Abdou AG. Stratification of urinary bladder carcinoma based on immunohistochemical expression of CK5, CK14 and CK20. *J Immunoassay Immunochem.* 2021;42(3):236-51.
  23. Guo CC, Bondaruk J, Yao H, Wang Z, Zhang L, Lee S, et al. Assessment of luminal and basal phenotypes in bladder cancer. *Sci Rep.* 2020;10(1):9743.
  24. Lu J, Zhang Y, Wu C, Chu C, Liu Z, Cao Y. Impact of immunohistochemistry- based molecular subtype on predicting chemotherapy response and survival in patients with T1 stage bladder cancer after bladder-preserving treatment. *Jpn J Clin Oncol.* 2021;51(3):424-33.
  25. Hardy CSC, Ghaedi H, Slotman A, Sjödaahl G, Gooding RJ, Berman DM, et al. Immunohistochemical assays for bladder cancer molecular subtyping: Optimizing parsimony and performance of lund taxonomy classifiers. *J Histochem Cytochem.* 2022;70(5):357-75.
  26. Yuk HD, Jeong CW, Kwak C, Kim HH, Moon KC, Ku JH. Clinical outcomes of muscle invasive bladder Cancer according to the BASQ classification. *BMC Cancer.* 2019;19(1):897.
  27. Wang C-C, Tsai Y-C, Jeng Y-M. Biological significance of GATA3, cytokeratin 20, cytokeratin 5/6 and p53 expression in muscle-invasive bladder cancer. *PLoS One.* 2019;14(8):e0221785.
  28. Livingstone LR, White A, Sprouse J, Livanos E, Jacks T, Tlsty TD. Altered cell cycle arrest and gene amplification potential accompany loss of wild-type p53. *Cell.* 1992;70(6):923-35.
  29. Hanahan D. Hallmarks of Cancer: New Dimensions. *Cancer Discov.* 2022;12(1):31-46.

30. da Silva JNL, Ranzi AD, Carvalho CT, Scheide TV, Strey YTM, Graziottin TM, et al. Cell cycle markers in the evaluation of bladder cancer. *Pathol Oncol Res.* 2020;26(1):175-81.
31. Ziaran S, Harsanyi S, Bevizova K, Novakova ZV, Trebaticky B, Bujdak P, et al. Expression of E-cadherin, Ki-67, and p53 in urinary bladder cancer in relation to progression, survival, and recurrence. *Eur J Histochem.* 2020;64(2):3098.
32. Daizumoto K, Yoshimaru T, Matsushita Y, Fukawa T, Uehara H, Ono M, et al. A DDX31/Mutant-p53/EGFR axis promotes multistep progression of muscle-invasive bladder cancer. *Cancer Res.* 2018;78(9):2233-47.
33. Mitra AP, Datar RH, Cote RJ. Molecular pathways in invasive bladder cancer: new insights into mechanisms, progression, and target identification. *J Clin Oncol.* 2006;24(35):5552-64. B, et al. Prognostic markers in pT3 bladder cancer: A study from the international bladder cancer tissue microarray project. *Urol Oncol.* 2021;39(5):301.e17-301.e28.
34. Semeniuk-Wojtaś A, Lubas A, Cierniak S, Brzóskowska U, Syryło T, Zieliński H, et al. Selected protein expression in a new prognostic model for patients with non-muscle-invasive bladder cancer. *J Cancer Res Clin Oncol.* 2020;146(8):2099-108.
35. Lloreta J, Font-Tello A, Juanpere N, Frances A, Lorenzo M, Nonell L, et al. FOXO1 down-regulation is associated with worse outcome in bladder cancer and adds significant prognostic information to p53 overexpression. *Hum Pathol.* 2017;62:222-31.
36. Hodgson A, Rhijn BWG van, Kim SS, Ding C, Saleeb R, Vesprini D, et al. Reassessment of p53 immunohistochemistry thresholds in invasive high grade bladder cancer shows a better correlation with TP53 and FGFR3 mutations. *Pathol Res Pract.* 2020;216(11):153186.
37. Semeniuk-Wojtaś A, Lubas A, Cierniak S, Brzóskowska U, Syryło T, Zieliński H, et al. Selected protein expression in a new prognostic model for patients with non-muscle-invasive bladder cancer. *J Cancer Res Clin Oncol.* 2020;146(8):2099-108.
38. Han L, Gallan AJ, Steinberg GD, Sweis RF, Paner GP. Morphological correlation of urinary bladder cancer molecular subtypes in radical cystectomies. *Hum Pathol.* 2020;106:54-61.
39. Leivo MZ, Tacha DE, Hansel DE. Expression of uroplakin II and GATA-3 in bladder cancer mimickers: Caveats in the use of a limited panel to determine cell of origin in bladder lesions. *Hum Pathol.* 2021;113:28-33.
40. Akiyama T, Sudo C, Ogawara H, Toyoshima K, Yamamoto T. The product of the human c-erbB-2 Gene: A 185-kilodalton glycoprotein with tyrosine kinase activity. *Science.* 1986;232(4748):1644-6.
41. Yarden Y, Sliwkowski MX. Untangling the ErbB signaling network. *Nat Rev Mol Cell Biol.* 2001;2(2):127-37.
42. Oh D-Y, Bang Y-J. HER2-targeted therapies - A role beyond breast cancer. *Nat Rev Clin Oncol.* 2020;17(1):33-48.
43. Zhau HE, Zhang X, Von Eschenbach AC, Scorsone K, Babain RJ, Ro JY, et al. Amplification and expression of the c-erb B-2/neu proto-oncogene in human bladder cancer. *Mol Carcinog.* 1990;3(5):254-7.
44. Cimpean AM, Tarlui V, Cumpănaș AA, Bolintineanu S, Cumpănaș A, Raica M. Critical overview of HER2 assessment in bladder cancer: What is missing for a better therapeutic approach? *Anticancer Res.* 2017;37(9):4935-42.
45. Cormio L, Sanguedolce F, Cormio A, Massenio P, Pedicillo MC, Cagiano S, et al. Human epidermal growth factor receptor 2 expression is more important than Bacillus Calmette Guerin treatment in predicting the outcome of T1G3 bladder cancer. *Oncotarget.* 2017;8(15):25433-41.
46. Franceschini T, Capizzi E, Massari F, Schiavina R, Fiorentino M, Giunchi F. Immunohistochemical over-expression of HER2 does not always match with gene amplification in invasive bladder cancer. *Pathol Res Pract.* 2020;216(8):153012.
47. Li W, Wang Y, Tan S, Rao Q, Zhu T, Huang G, et al. Overexpression of Epidermal Growth Factor Receptor (EGFR) and HER-2 in bladder carcinoma and its association with patients' clinical features. *Med Sci Monit.* 2018;24:7178-85.
48. Wucherpfennig S, Rose M, Maurer A, Cassataro MA, Seillier L, Morsch R, et al. Evaluation of therapeutic targets in histological subtypes of bladder cancer. *Int J Mol Sci.* 2021;22(21):11547.
49. Roma-Rodrigues C, Mendes R, Baptista PV, Fernandes AR. Targeting tumor microenvironment for cancer therapy. *Int J Mol Sci.* 2019;20(4):840.
50. Ishida Y, Agata Y, Shibahara K, Honjo T. Induced expression of PD-1, a novel member of the immunoglobulin gene

- superfamily, upon programmed cell death. *EMBO J.* 1992;11(11):3887-95.
51. Agata Y, Kawasaki A, Nishimura H, Ishida Y, Tsubata T, Yagita H, et al. Expression of the PD-1 antigen on the surface of stimulated mouse T and B lymphocytes. *Int Immunol.* 1996;8(5):765-72.
  52. Dong H, Strome SE, Salomao DR, Tamura H, Hirano F, Flies DB, et al. Tumor-associated B7-H1 promotes T-cell apoptosis: A potential mechanism of immune evasion. *Nat Med.* 2002;8(8):793-800.
  53. Rosenberg JE, Hoffman-Censits J, Powles T, Van Der Heijden MS, Balar AV, Necchi A, et al. Atezolizumab in patients with locally advanced and metastatic urothelial carcinoma who have progressed following treatment with platinum-based chemotherapy: A single-arm, multicentre, phase 2 trial. *Lancet.* 2016;387(10031):1909-20.
  54. Sisto M, Ribatti D, Lisi S, Kurien T. Cadherin signaling in cancer and autoimmune diseases. *Int J Mol Sci.* 2021;22(24):13358.
  55. Yu W, Yang L, Li T, Zhang Y. Cadherin signaling in cancer: Its functions and role as a therapeutic target. *Front Oncol.* 2019;9:989.
  56. Hussein S, Mosaad H, Rashed HE, Ahmed S, Ragab A, Ismail EI. Molecular factors regulating E-cadherin expression in urothelial bladder cancer and their correlations with the clinicopathological features. *Mol Biol Rep.* 2017;44(4):365-77.
  57. Hatina J, Schulz WA. Stem cells in the biology of normal urothelium and urothelial carcinoma. *Neoplasma.* 2012;59(6):728-36.
  58. Zhu F, Qian W, Zhang H, Liang Y, Wu M, Zhang Y, et al. SOX2 is a marker for stem-like tumor cells in bladder cancer. *Stem Cell Rep.* 2017;9(2):429-37.
  59. Zhang S, Xiong X, Sun Y. Functional characterization of SOX2 as an anticancer target. *Signal Transduct Target Ther.* 2020;5(1):135.
  60. Leis O, Eguiara A, Lopez-Arribillaga E, Alberdi MJ, Hernandez-Garcia S, Elorriaga K, et al. Sox2 expression in breast tumours and activation in breast cancer stem cells. *Oncogene.* 2012;31(11):1354-65.
  61. Fu H, Zhu Y, Wang Y, Liu Z, Zhang J, Xie H, et al. Identification and validation of stromal immunotype predict survival and benefit from adjuvant chemotherapy in patients with muscle-invasive bladder cancer. *Clin Cancer Res.* 2018;24(13):3069-78.
  62. Ruan J, Wei B, Xu Z, Yang S, Zhou Y, Yu M, et al. Predictive value of Sox2 expression in transurethral resection specimens in patients with T1 bladder cancer. *Med Oncol.* 2013;30(1):445.
  63. Costa JB da, Gibb EA, Bivalacqua TJ, Liu Y, Oo HZ, Miyamoto DT, et al. Molecular characterization of neuroendocrine-like bladder cancer. *Clin Cancer Res.* 2019;25(13):3908-20.
  64. Belgorosky D, Girouard J, Langle YV, Hamelin-Morrisette J, Marino L, Agüero EI, et al. Relevance of iNOS expression in tumor growth and maintenance of cancer stem cells in a bladder cancer model. *J Mol Med (Berl).* 2020;98(11):1615-27.

