

Colarado Microdissection Needle: A Review

Jacob Antony Chakiath¹, Ravi Kumar Chittoria²

How to cite this article:

Jacob Antony Chakiath, Ravi Kumar Chittoria/Colarado Microdissection Needle: A Review/Indian Journal of Pathology: Research and Practice 2023;12(1) 17-20.

Abstract

Elective surgery requires planned incisions, and these require appropriate blades. Major elective incisions are used for sectioning of skin, vessels, deeper tissue. The Colorado micro dissection needle was introduced into clinical practice with various applications. The concept of electrocautery incisions is fast gaining acceptance not only amongst the neurosurgeons, but also the plastic surgeons, orthopedics, the general surgeons for thoracic and abdominal incisions and the myths behind its complications are soon fading with excellent result. This article reviews colaradomicrodissection needle in all aspects.

Keywords: Colarado; Microdissection; Needle; Electrocautery.

INTRODUCTION

Elective surgery requires planned incisions, and these require appropriate blades. Major elective incisions are used for sectioning of skin, vessels, deeper tissue and most commonly the internal organs. If particular blades have evolved specific to each tissue incised, their remote origins remain mundane. In all probability 'surgical' blades were borrowed from domestic items and weaponry, at

least until some 2000 years ago; in certain primitive societies such sources persist today.¹ Incisions on skin with a cold steel (scalpel) have been associated with unfavorable side effects such as excessive blood flow with inadequate visibility caused by blood in the operating field.² Current advances in equipment technology have offered us with tremendous advantage in performing various surgeries. Among these is the Colorado electro micro-dissection needle. Although use of electro surgery dates back to 1909 when it was first used to fulgurate tumors, to 1926 when "Cushing" first introduced it in Neurosurgery.³ The general surgical use of electrocautery had been mainly reserved for incising and dissecting the subcutaneous tissue and deeper layers. The use of the electrocautery scalpel to open skin has been rejected or reserved in past for fear of delayed wound healing or infection.⁴ Currently there is enough literature and evidence to support favorable use of electro-cautery as a complete or partial substitution to cold steel, in terms of operative blood loss, post-operative pain and surgical scar.^{4,6} The electrocautery knife has

Author Affiliation: ¹Senior Resident, Department of Plastic Surgery & Telemedicine ²Professor & Registrar (Academic) Head of IT Wing, Department of Plastic Surgery & Telemedicine, Jawaharlal Institute of Postgraduate Medical Education and Research, Pondicherry 605006, India.

Corresponding Author: Ravi Kumar Chittoria, Professor & Registrar (Academic) Head of IT Wing, Department of Plastic Surgery & Telemedicine, Jawaharlal Institute of Postgraduate Medical Education and Research, Pondicherry 605006, India.

E-mail: drchittoria@yahoo.com

Received on: 07.12.2022

Accepted on: 15.01.2023

been used widely by general surgeons to create abdominal and thoracic incisions, with excellent results. The need for a fast and more hemostatic method to create incisions is even more important in Neurosurgery, particularly for scalp incisions and in the pediatric age group. The concept of electrocautery incisions is fast gaining acceptance not only amongst the neurosurgeons, but also the plastic surgeons, orthopedics, the general surgeons for thoracic and abdominal incisions and the myths behind its complications are soon fading with excellent result.

COLORADO MICRO DISSECTION NEEDLE

The needle used was N110 A (2.3622 mm sleeve diameter). Generator unit was set at between 10W to 15W for both cutting and coagulation & 390 kHz sinusoid waveform. N 103 A and N 110 A Colorado micro dissection needle were used alternatively. The incision depth included dermis, epidermis, and fascia.

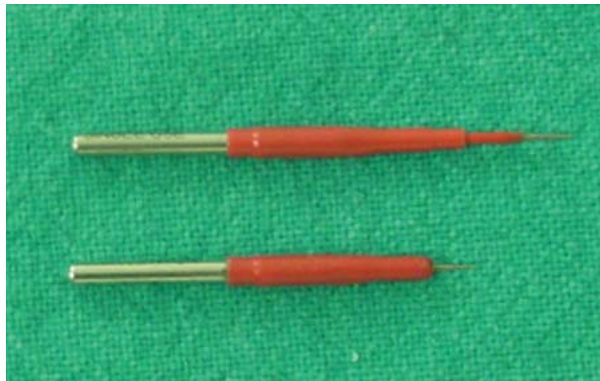


Fig. 1: N 103 A, N 110 A Colorado Microdissection Needles

The Colorado micro dissection needle (Stryker-Leibinger, Freiburg, Germany) was introduced into clinical practice with various applications.⁵ The instrument tip is a delicately machined, insulated tungsten diathermy needle that is compatible with any standard cautery hand piece. The advantage of this micro dissection needle has been described by Farnworth and colleagues (1993).⁶ They microscopically examined and compared incisions made with standard electrocautery, the micro dissection needle and the Shaw hemostatic scalpel. The study showed that by decreasing the surface area of the electrocautery device, higher power densities are sustained at comparatively low wattage. The net result permits reduced dissipation of heat energy into the surrounding tissue. This results in a smaller zone of tissue necrosis than conventional cautery devices.⁶

DISCUSSION

One of the reported benefits of electrocautery is the significant reduction in cutting time.^{5,7} The study reported by Kearns et al, mean differences in cutting time 40 seconds favor of electrocautery incisions.⁸ Sheikh B reported, the speed of incision when the steel scalpel was used ranged between 0.17 and 0.37 mm/s, with an average of 0.3 mm/s. The speed of incision when the Colorado micro dissection needle electrocautery scalpel was used ranged between 1.8 and 2.5 mm/s, with an average of 2.3 mm/s.⁷ According to the study reported by Madhukar KT et al., the speed of incision when a cold scalpel was used ranged between 0.15 mm/s and 0.4 mm/s, with an average of 0.2 mm/s. The speed of incision with electrocautery blade was between 1.3 mm/s and 2.8mm/s, with an average of 1.8 mm/s.⁹ Milan et al study showed a mean difference between Colorado microdissection needle and the cold scalpel, the time taken for incision with Colorado micro dissection needle was less than cold steel, however, it was not statistically significant.¹⁰

Incisional blood loss with Colorado needle is reportedly significantly less when compared to the steel scalpel incisions.^{5,7,8,11} Sheikh B reported approximately four times more blood loss with a steel scalpel when compared to the Colorado micro dissection needle for scalp incisions in neurosurgical procedures.⁷ Rideout B et al. compared results with those of a number of recent reports in the literature that described other advocated tonsillectomy techniques and authors found Blood loss was least for Electro micro dissection tip than cold steel.⁵ N Nitta et al. reported that, the blood loss was three to five time lesser using the micro needle electrocautery scalpel compared to cold steel (scalpel) for scalp incisions in neurosurgical procedures.¹¹ The study reported by Kearns et al, incisional blood loss with electrocautery incisions is reportedly significantly less when compared to the steel scalpel incisions.⁸ Milan et al study showed that almost all cases had less incisional blood loss with Colorado micro dissection needle, supported by a statistically significant result.

The post-operative pain is probably of utmost importance to the patient.^{5,12} Rideout B et al. compared results with those of a number of recent reports in the literature that described other advocated tonsillectomy techniques and author found post-operative pain was much lesser for Electro micro dissection tip than cold steel.⁵ Perkins J determined micro dissection needle for tonsillectomy resulted decreased postoperative

pain when compared with standard electrocautery.¹² In Milan et al study, as expected, the mean pain scores for both modalities decreased at each pain assessment after surgery. The mean pain scores for Colorado micro dissection needle were less and P-value suggest statistically significant.

One of the concerns regarding electrosurgery was the theoretical risk of increased wound complications due to the heat production which results in a zone of tissue necrosis adjacent to the incision.¹³ It was proven by several studies that electrosurgically created incisions showed less increased incidence of wound complications such as dehiscence and infection. This was shown by Sheikh B, Sharma R and N. Nitta et al. No data investigating the wound complications for craniofacial incisions with the Colorado micro dissection needle could be found.^{4,7,11} There are no reports which suggest that the wound infection rates have increased by use of the electrocauteries (Colorado micro dissection needle) in neurosurgical cases.⁷

According to Milan et al study, at 6 months follow up the level of the scar as compared with surrounding skin, colour match, consistency and width were normal in all the cases.⁴ N Nitta et al. suggest use of Colorado micro dissection needle, results in minimal wound damage, minimal scarring, excellent healing and minimal alopecia as it works with minimal electric contact technique.¹¹

In Milan et al study, 60 incision were considered in which two of the incisions showed infection and dehiscence belonging one from each group. This is well within the acceptable range of maxillofacial wound infection rate, indicating no increase in the rate of wound infection with the use of Colorado micro dissection needle. This result was similar to reported by NNitta. The width of scar was evaluated in millimeters at 3rd month and 6th month interval. It was noted that, a Colorado micro dissection needle gives less width and better scar than cold steel (Scalpel). Margarita Peneva et al. evaluated the results of routine use of electrosurgical microneedle in performing skin incisions in the facial regions.

Eighty patients with both benign and malignant skin lesions in the facial regions undergoing surgery were enrolled in Milan et al study. In group A comprising 40 patients, cold steel surgical scalpel No. 15 was used for the surgical procedure. They found that the two groups did not significantly differ in the speed of incision and speed of excision although both the speed of incision and the speed of excision were found to be slightly faster in the electrosurgery group. There was significantly less blood loss in the electrosurgery group compared

with the scalpel group. Statistical analysis did not confirm as significant the difference in complications between the two groups although most of the complications were associated with the patients operated with scalpel.¹⁰

Rampalli Viswa Chandra, Boya Savitharani, Aileni Amarender Reddy compared compare the outcomes of incisions made by Colorado[®] microdissection needle, electrosurgery tip, and surgical blade during periodontal surgery. Twenty-two individuals participated in this study. Three quadrants in each individual were randomly assigned into each of the following experimental groups: Colorado[®] microdissection needle (CMD), electrosurgery tip (EC) and surgical blade (BP), in which, incisions were given with Colorado[®] microdissection needle, straight electrocautery tip, and a scalpel blade, respectively. They found that the use of CMD for periodontal surgery showed better results over EC in all parameters. CMD resulted in lesser bleeding and less postoperative pain and attained similar results to that of BP in clinical parameters of periodontal disease.¹¹

Yonca O Arat et al. compared ecchymosis, cosmesis, and histologic tissue image of incisions made with a scalpel or Colorado needle in patients undergoing upper and lower aesthetic blepharoplasty. A total of 254 eyelids of 101 patients were included in Milan et al study. No significant difference was observed in ecchymosis on postoperative day 1 and 7 and scar cosmesis on day 30 and 180 between the 2 techniques. Histologically, necrosis was noted only with the Colorado needle sides ($p = 0.001$). No adverse events occurred on the Colorado needle side at any time after surgery. They concluded that no clinical difference is noted between Colorado needle and scalpel incisions in terms of ecchymosis and scar cosmesis after aesthetic blepharoplasty.¹²

In Milan et al study, all the patients tolerated the procedures well, with no increased risk from the use of the Colorado micro dissection needle, it was noted that a Colorado micro dissection needle could be safely used for skin incision without any increased risk of cutaneous scarring, wound infection, or wound dehiscence in Maxillofacial Surgery. There was significant less incisional blood loss intra operative and less pain post operatively compared with a cold steel (scalpel). There was no evidence of any scar tenderness or keloid formation in follow up of the cases and It was noted that, the width of post-operative scar when using Colorado micro dissection needle is lesser and better healing than cold steel (Scalpel). Also, the time taken for

incision with Colorado micro dissection needle was lesser than cold steel, but it was statistically insignificant.

ADVANTAGES

1. Reduction in cutting time
2. Less blood loss
3. Less postoperative pain
4. Less wound complications
5. Less scar and better cosmetic results.

DISADVANTAGES

1. Requirement of infrastructure

CONCLUSION

The Colorado micro dissection needle is both safe and useful in surgical procedures compared to other modalities.

REFERENCES

1. Kirkup J (1995) The history and evolution of surgical instruments- VI The surgical blade: from fingernail to ultrasound. *Ann R CollSurgEngl* 77: 380-388.
2. Bashetty K, Nadig Kapoor S (2009) Electrosurgery in aesthetic and restorative dentistry: A literature review and case reports. *Jrnl Cons Dent* 12(4): 139-146.
3. Hausner K (1986) Electrosurgery. Addison IL Elmed, Inc p. 2-10.
4. Sharma R (2017) Safety of coloradomicrodissection needle (stryker) for skin opening in craniomaxillofacial surgery. *J. Maxillofac. Oral Surg* 11(1): 115-118.
5. Rideout B, Shaw G Y (2004) Tonsillectomy using the coloradomicrodissection needle: A prospective series and comparative technique review. *Southern Medical Journal* 97(1): 11-17.
6. Farnworth T, Beals S, Manwaring K, Trepeta R (1993) Comparison of skin necrosis in rats by using a new microneedle electrocautery, standardized electrocautery, and the Shaw hemostatic scalpel. *Ann PlastSurg* 31(2): 164-167.
7. Sheikh B (2015) Safety and efficacy of electrocautery scalpel utilization for skin opening in neurosurgery. *Br J Neurosurg* 18(3): 268-272.
8. Kearns S, Conolly E, McNally S, McNamara D, Deasy J (2001) Randomised clinical trial of diathermy versus scalpel incisions in midline laparotomy. *Br J Surg* 88: 41-44.
9. Madhukar KT, Ganesh MT (2016) Comparative study of safety and efficacy of electrocautery blade with cold scalpel blade for skin opening during fixation of fracture of forearm bone with plate and screws. *International Journal of Health & Allied Sciences* 1(3): 153-157.
10. Margarita Peneva, Andrijana Gjorgjeska, Vladimir Ginoski, Hristina Breshkovska, Roza Dzoleva Tolevska (2018) Electro- surgical microneedle versus scalpel skin incisions in the facial region. *Sanamed* 13(3): 1-8.
11. Rampalli Viswa Chandra, Boya Savitharani, Aileni Amarender Reddy (2016) Comparing the outcomes of incisions made by coloradomicrodissection needle, electrosurgery tip, and surgical blade during periodontal surgery: A randomized controlled trial. *J Indian Soc Periodontol* 20: 612-622.
12. Yonca O Arat, Almila S Sezenoz, Francesco P Bernardini, Mark A Alford, Merih Tepeoglu, et al. (2016) Comparison of Colorado Microdissection Needle Versus Scalpel Incision for Aesthetic Upper and Lower Eyelid Blepharoplasty. *OphthalPlastReconstrSurg* 13: 1-6.

