

## Laparoscopic Injury to Urinary Bladder and its Identification, Repair: Distended Urosac Bag-A Vigilant Observation

Shashikala Mallesh<sup>1</sup>, Niranjana P.B<sup>2</sup>, Shreya Mallesh<sup>3</sup>

### How to cite this article:

Shashikala Mallesh, Niranjana P.B, Shreya Mallesh/Laparoscopic Injury to Urinary Bladder and its Identification, Repair: Distended Urosac Bag-A Vigilant Observation/Indian J Obstet Gynecol. 2023;11(3):121-123.

### Abstract

Bladder perforation during laparoscopy is a seldom recognized, uncommon complication. We present a case of distended urosac bag secondary to bladder injury.

Repair was done laparoscopically in two layers, Catheter was kept for 3 weeks.

Patient had no complaints later on.

**Keywords:** Bladder; Gaseous Distention; Laparoscopy; Perforation; Urinary bag.

## INTRODUCTION

Laparoscopic gynecologic surgery has been described as an effective and safe procedure. It is associated with decreased morbidity and admission periods and is widely used in practice. However, regardless of these advantages, this procedure has its own potential for serious complications related to pneumoperitoneum, position change, and laparoscopic instrument.

**Author's Affiliation:** <sup>1</sup>Senior Consultant, Department of Obstetrician and Gynecologist, Infertility Specialist, Laparoscopic Surgeon, <sup>2</sup>Laparoscopic Surgeon, Department of Minimal Invasive Surgery, <sup>3</sup>Consultant, Department of Obstetrician and Gynecologist, Dr. Mallesh City Hospital, Shimoga, Shivamogga - 577201 Karnataka, India.

**Corresponding:** Niranjana P.B, Laparoscopic Surgeon, Department of Minimal Invasive Surgery, Dr. Mallesh City Hospital, Shimoga, Shivamogga 577201 Karnataka, India.

**E-mail:** [lislin333@gmail.com](mailto:lislin333@gmail.com)

**Received on:** 27.06.2023 **Accepted on:** 31.07.2023

It is known that the incidence of bladder injury during laparoscopic procedures ranges from 0.02% to 8.3%, and that the most common laparoscopic procedure during which bladder injury occurs is laparoscopic assisted vaginal hysterectomy.<sup>1</sup>

Traumatic complications due to instruments manipulation include bowel perforation, large vessel injury, gastric perforation, bladder perforation, and ureter injury.

There are a wide range of bladder injuries during laparoscopic procedures. Here we report a case of bladder injury which was identified with distended urosac bag, and laparoscopic repair was done successfully.

## CASE REPORT

A 42 yr old female came with abnormal uterine bleeding type multiple leiomyoma with dysmenorrhea. The patient was given medical management, upon persistent symptoms the patient opted for hysterectomy.

No significant medical history noted, patient was

posted for laparoscopic hysterectomy.

Under general anesthesia, patient was positioned in head low position.

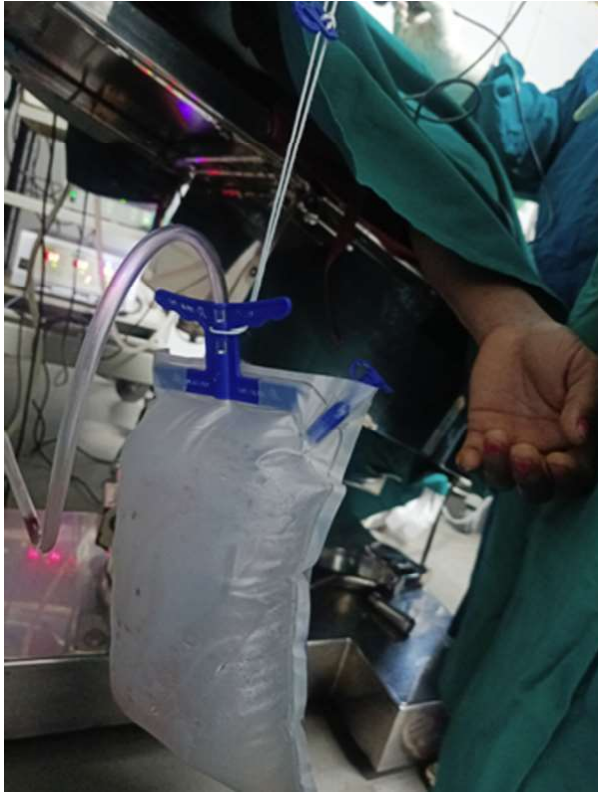


Fig -1: Distended uro sac bag

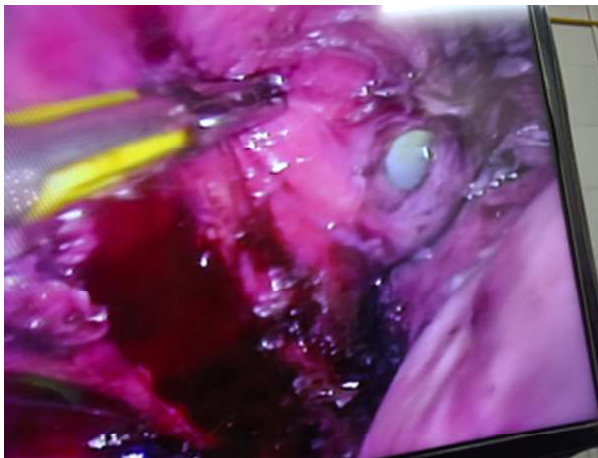

Fig -2: Bladder injury noted , Foley's bulb visible.

#### Steps of Laparoscopic Hysterectomy, Followed:

Bladder mobilized, and ot staff (Heena, Deepika, karlina sisters) noted that uro sac bag was filling and getting tense.

Suspicion of bladder injury, urinary bladder was filled with saline + methylene blue dye.

Leak noted, in the dissected area, defect was around 3 cm, Foley's bulb was clearly visible.

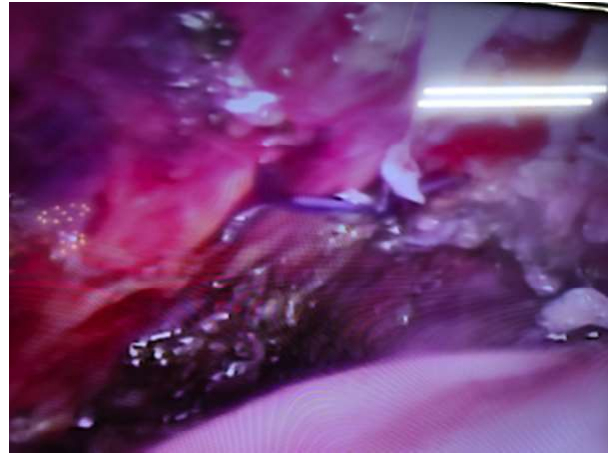


Fig- 3: 2 layer laparoscopic closure done

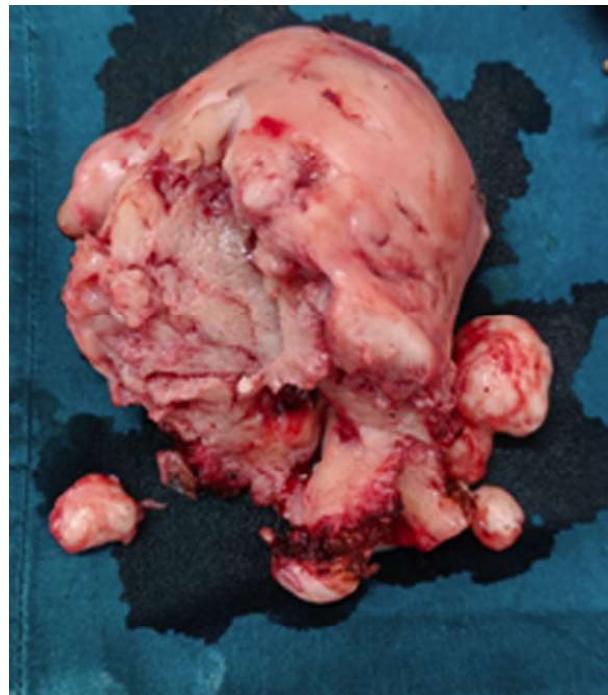


Fig - 4: 12 Week size uterus extracted vaginally

Dye pushed again, no leak noted.

Urosac bag, was not distended.

Hysterectomy completed laparoscopically.

Patient was discharged with Foley's catheter, catheter was removed after 3 weeks.

Patient has good recovery.

#### DISCUSSION

Bladder perforation is an uncommon complication of laparoscopic surgery. Since it was first reported, it has been noted to occur during procedures involving a verres needle, trocars (primary or secondary), and electrocautry

regardless of improvements in surgical techniques and safety instructions.<sup>2</sup> Predisposing risk factors for complications during laparoscopic procedures include operation history of the patient, pelvic adhesion, endometriosis, obesity, urachal anomaly, and unskilled surgeons.<sup>3</sup>

Bladder perforation during laparoscopic surgery may be detected by intraperitoneal bleeding, clear liquid in the operation field, hematuria, and gaseous distention of the urinary bag.<sup>4</sup>

Among these, hematuria and gaseous distention of the urinary bag could be detected early by anesthesiologists. If hematuria is found intra-operatively or post-operatively, cystoscopy or cystoradiography can be used to confirm bladder perforation. Hematuria may not occur in all bladder perforation cases and there are difficulties in diagnosing intra-operatively.<sup>5</sup>

In our case, it is thought that bladder perforation occurred through laparoscopic dissection of severe adhesion of uterus with bladder despite no previous abdominal surgery.

The uterus was big 12 week size with multiple fibroids.

Early detection during laparoscopic surgery allows immediate bladder repair via laparoscopy or laparotomy and decreases postoperative morbidity. A small undetected tear may heal if bladder decompression is maintained, but may cause oliguria, peritonitis, and fistula formation.<sup>9</sup>

Insertion of a foley catheter is associated with a risk of infection; on the other hand, this decreases the risk of bladder injury because it permits continuous decompression of bladder. It also allows early detection of bladder injury which is not found in the operation field, so insertion of indwelling foley catheter is recommended.<sup>5</sup>

In conclusion, vigilant observation in operation theatre like distended uro sac bag can prevent

disaster later on.

## REFERENCES

1. Ostrzenski A, Ostrzenska KM. Bladder injury during laparoscopic surgery. *Obstet Gynecol Surv.* 1998;53:175-180. [PubMed] [Google Scholar].
2. Georgy FM, Fettermann HH, Chefetz MD. Complication of laparoscopy; two cases of perforated urinary bladder. *Am J Obstet Gynecol.* 1974;120:1121-1122. [PubMed] [Google Scholar].
3. Mirhashemi R, Harlow BL, Ginsburg ES, Signorello LB, Berkowitz R, Feldman S. Predicting risk of complications with gynecologic laparoscopic surgery. *Obstet Gynecol.* 1998;92:327-331. [PubMed] [Google Scholar].
4. Font GE, Brill AI, Studhldreher PV, Rosenzweig BA. Endoscopic management of incidental cystotomy during operative laparoscopy. *J Urol.* 1993;149:1130-1131. [PubMed] [Google Scholar].
5. Lamaro VP, Brome JD, Vancaillie TG. Unrecognized bladder perforation during operative laparoscopy. *J Am Assoc Gynecol Laparosc.* 2000;7:417-419. [PubMed] [Google Scholar].
6. Sia-Kho E, Kelly RE. Urinary drainage bag distention: An indication of bladder injury during laparoscopy. *J Clin Anesth.* 1992;4:346-347. [PubMed] [Google Scholar].
7. Schanbacher PD, Rossi LJ, Jr, Salem MR, Joseph NJ. Detection of urinary bladder perforation during laparoscopy by distention of the collection bag with carbon dioxide. *Anesthesiology.* 1994;80:680-681. [PubMed] [Google Scholar].
8. Classi R, Sloan PA. Intraoperative detection of laparoscopic bladder injury. *Can J Anaesth.* 1995;42:415-416. [PubMed] [Google Scholar].
9. Ho AM, Roth P, Cowan WD. Gaseous distention of the urinary bag indicating bladder perforation during laparoscopic pelvic procedures. *Int J Gynaecol Obstet.* 1996;55:297-298. [PubMed] [Google Scholar].