

## Spinal Schwannoma in Third Trimester of Pregnancy: A Rare yet Challenging Case

Rajvi Hans<sup>1</sup>, Rajani Upadhyaya<sup>2</sup>, Shripad Hebbar<sup>3</sup>, Kavisha Bhat<sup>4</sup>, Divyashree Bhat<sup>5</sup>

### How to cite this article:

Rajvi Hans, Rajani Upadhyaya, Shripad Hebbar *et al.*, Spinal Schwannoma in Third Trimester of Pregnancy: A Rare yet Challenging Case. Indian J Obstet Gynecol. 2024;12(4):185-188.

### Abstract

**Introduction:** Spinal schwannomas during pregnancy are exceedingly rare, with most cases occurring as pregnancy-related spinal tumors (PRST). These tumors can appear or become symptomatic within a year of pregnancy. Few reports exist of third-trimester diagnoses, and their management presents unique challenges, including balancing maternal-fetal safety during diagnosis and intervention.

**Case Presentation:** We present the case of a 35-year-old woman at 36 weeks of gestation (G2P1L1) who developed acute bilateral lower limb weakness, rapidly progressing to involve the upper limbs. Neurological examination revealed absent reflexes and sensory loss below T12. MRI without contrast identified an intradural extramedullary lesion, likely a schwannoma, at the C5-D1 level compressing the spinal cord. An emergent lower segment cesarean section (LSCS) was performed, followed by successful tumour resection via C4-D1 laminotomy. Histopathology confirmed ancient schwannoma. Postoperative recovery was gradual, with significant neurological improvement after three months.

**Discussion:** The diagnosis of spinal tumours during pregnancy is often delayed due to symptom overlap with common pregnancy-related conditions. Surgical timing remains a contentious issue, but the literature supports intervention under general anaesthesia as safe during pregnancy when neurological symptoms are rapidly progressing. Our case demonstrates the successful use of a multidisciplinary approach involving obstetricians, anaesthetists, neurosurgeons, and neonatologists to manage maternal and fetal outcomes.

**Conclusion:** Spinal schwannomas in pregnancy, though rare, require early diagnosis and a multidisciplinary treatment approach to optimise maternal and fetal outcomes. Timely surgical intervention can lead to favourable neurological recovery and safe delivery.

**Keywords:** Spinal schwannoma, Pregnancy, Third trimester, Caesarean section, Tumour resection, Multidisciplinary management.

**Author's Affiliation:** <sup>1</sup>Junior Resident, <sup>2</sup>Assistant Professor, <sup>3</sup>Professor and HOD, <sup>4,5</sup>Senior Resident, Department of Obstetrics and Gynecology, Kasturba Medical College Manipal, Manipal Academy of Higher Education, Manipal, Karnataka, India.

**Corresponding Author:** Rajani Upadhyaya, Assistant Professor, Department of Obstetrics and Gynecology, Kasturba Medical College Manipal, Manipal Academy of Higher Education, Manipal, Karnataka, India

**E-mail:** Rajaniu89@gmail.com

**Received on:** 18.11.2024

**Accepted on:** 27.12.2024



## INTRODUCTION

Most spinal Schwannomas have been reported to occur as a pregnancy-related spinal tumour (PRST), which can appear or be symptomatic within a year of the pregnancy.<sup>1</sup> It might affect the release of the tumor-growth factor. The symptoms usually start with pain and sensory loss at the spinal cord level. We report a case of thoracolumbar schwannoma with a history of chronic low back pain since post-pregnancy. A Thirty-Seven years old female, suffered chronic low back pain for 3 years since she had a pregnancy. In the last 4 months, she suffered paresis and tingling sensation on the right foot. MRI shown intradural mass at Th 12 - L2. Biopsy, tumor resection, and laminectomy were performed to do the histopathology analysis, resect, and stabilization. Histopathology examination revealed Schwannoma types. The patient was discharged three days after complete tumor resection and stabilization, with an improvement of neurological function. Spinal Schwannoma can occur as a Pregnancy-related spinal tumor (PRST It is even reported in some circumstances in early pregnancy. However, very few reports of the same are noted in the third trimester of pregnancy.<sup>2</sup>

They commonly present as radiculopathy along the affected nerve root, with or without numbness and tingling. In severe cases, bowel and bladder incontinence may be observed. For these reasons, in pregnancy, the diagnosis of a spinal tumour, especially a slow-growing benign Schwannoma, may be missed<sup>3</sup> and her symptoms were misdiagnosed as normal reactions to pregnancy until she progressed to complete paralysis and incontinence within 2 weeks. She was then confirmed to have thoracic intraspinal schwannoma through MRI.

**Interventions and Outcomes:** Surgery was performed using a unilateral hemilaminectomy approach with a comfortable lateral position during operation. The patient exhibited significant improvements in sensation and muscle strength after surgery. She delivered 2 healthy baby girls by eutocia in her 38th week of pregnancy.

**Lessons:** The diagnosis of this disease and the 4 possible mechanisms of its aggravated clinical presence are discussed. Intraspidal schwannomas during pregnancy are rare but may cause critical consequences for both the mother and the fetus. Timely diagnosis and multidisciplinary treatment by obstetricians, anesthesiologists, surgeons, oncologists, and neonatologists are essential for the clinical management of this disease.”,“container-ti

tle”:"Medicine",“DOI”:"10.1097/MD.0000000000006327",“ISSN”:"1536-5964",“issue”:"11",“journalAbbreviation”:"Medicine (Baltimore) it has also been theorised that oestrogen and progesterone can contribute to the sudden increase in size during gestation.

Pregnancy related spinal schwannomas are exceedingly rare, with limited literature available to guide clinical management. Most of the existing literature comprises case reports and small case series, highlighting the rarity of this clinical entity and the consequent lack of robust evidence-based guidelines.

While managing spinal schwannoma in pregnancy, one must balance the need for timely diagnosis and intervention with the risks associated with radiation exposure from imaging studies and potential fetal complications from surgery or anaesthesia. Additionally, the physiological changes of pregnancy, such as increased blood volume and hormonal fluctuations, may influence tumour growth and symptomatology.<sup>4</sup>

Keeping in mind the dearth of literature on this rare occurrence, we present a unique case of a Spinal Schwannoma diagnosed in the third trimester, presenting an unprecedented challenge to the obstetrician.

## CASE REPORT

This is the case of a 35-year-old pregnant woman, with one previous living child (G2P1L1) at 36 weeks of gestation, who presented with weakness in both lower limbs, which was sudden in onset, starting at her toes and calf, and gradually ascending to involve her upper limbs. She had no associated history of tingling, numbness or loss of sensation and had a continent bowel and bladder.

This pregnancy was a spontaneous conception with initial ANCs at a local primary care hospital. Her dating was noted to be excellent, and she took postconceptional folic acid. However, her First-trimester aneuploidy screening was not done. Iron and calcium supplements were taken during pregnancy. Her second-trimester scan was unremarkable for that gestation. The estimated fetal weight on her last scan was 1765 grams with a fundal anterior placenta. She developed acute onset bilateral lower limb weakness one morning and was thus referred to our hospital.

Her first pregnancy was four years back, which was terminated by lower segment cesarean section in view of non-progress of labor. She delivered a

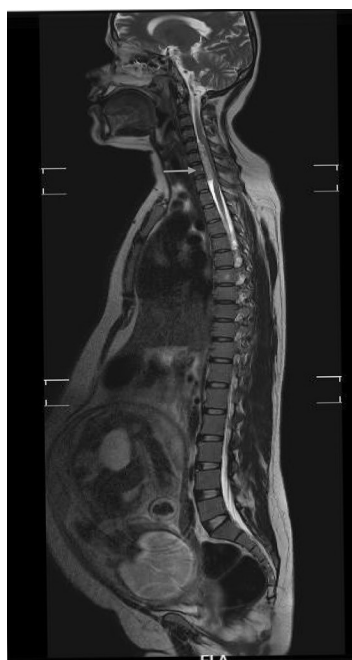female baby of around 2600 grams who is active and healthy. She gave a history of fall and seizures in her first pregnancy at 24 weeks. This was evaluated at a tertiary centre, and no radiological abnormality was noted. She had no other underlying comorbidities or surgeries.

Upon receiving the patient, she had stable vitals, was unable to lift both her lower limbs, and had weakness in her upper limbs. On examination, absent reflexes were noted in both lower limbs and decreased power in all four limbs. She had absent knee reflex in both limbs with Babinski sign positivity. Bilateral limb sensation was noted to be absent till T12. The obstetric examination showed a uterus corresponding to gestational age and a fetal heart sound within normal range. Other systemic examinations were noted to be normal.

When we performed routine blood investigations, alkaline phosphatase was slightly elevated, while other investigations were well within normal limits.

A Trans-abdominal Ultrasound by a level II General Ultrasound Practitioner, revealed a viable foetus corresponding to 36+1 weeks POG, with a normal anterior placenta.

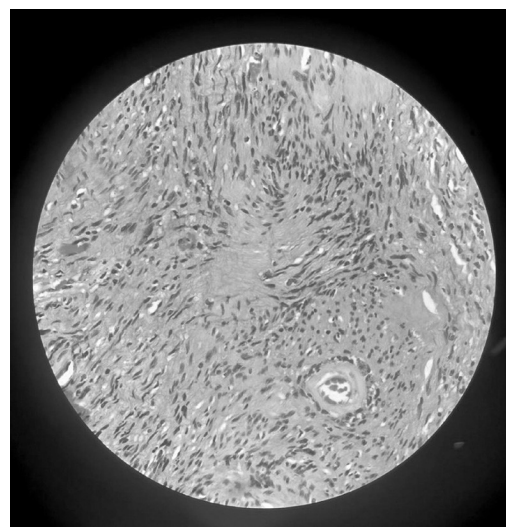
An MRI of the abdomen, pelvis, uterus, and fetus without contrast was performed, which revealed a well-defined intradural extramedullary lesion in the spinal canal, C5-D1 level compressing the spinal cord with T2 hyperintensity suggestive of a nerve sheath tumour likely schwannoma.



**Fig. 1:** MRI showing a well-defined intradural extramedullary lesion in the spinal canal, C5-D1 level compressing the spinal cord with T2 hyperintensity likely schwannoma

After a thorough evaluation, the patient underwent an emergent lower segment cesarean section (LSCS) followed by tumour resection with a multidisciplinary team of neurosurgeons, anaesthetists, and neurologists. Under general anaesthesia, emergency LSCS was performed, and a live female baby weighing 2.2kg was extracted with an APGAR 8/10 at 5 minutes.

Immediately after completion of LSCS, the patient was put in a lateral position, and C4-D1 laminotomy and total resection of the tumor was done successfully.



**Fig. 2:** Histopathological examination showing Verocay body suggestive of ancient schwannoma

The specimen sent for histopathological examination showed ancient schwannoma.

The neurological function started recovering slowly over two weeks; the patient was discharged to a rehabilitation center after two weeks.

After three months, there was a significant improvement in neurological function.

## DISCUSSION

The diagnosis of spinal tumours in pregnant women might be delayed because the early symptoms, such as back pain and numbness of the lower extremities, are similar to some typical reactions to pregnancy.

As a result of the rarity of spinal tumours occurring with pregnancy, the scheduling of surgical procedures during pregnancy continues to be a contentious issue.<sup>5</sup> There were thirty-four cases of women who were pregnant or early postpartum and required a neurosurgical intervention, according to the findings of Nossek *et al.*<sup>6</sup> in which

case surgery was promptly performed.

## RESULTS

Sixteen patients underwent neurosurgical intervention during pregnancy between 11 to 34 weeks of gestation (7 tumor, 3 vascular, 2 VP shunt, 2 spinal, 2 trauma). Sixteen patients received neurological intervention throughout their pregnancy, which occurred between the 11th and 34th week of their pregnancy. Regarding most pregnant women, the authors concluded that intervention under general anaesthesia is safe and ought to be considered early rather than very late. After doing a retrospective study of 10 pregnant women who had undergone spine surgery, Han *et al.*<sup>2</sup> arrived at the conclusion that, in the majority of instances, spinal surgery could be safely conducted while the woman was still pregnant. A further recommendation that was made was that the procedure should be carried out after the inducement of birth for patients who were between 34 and 36 weeks pregnant and were experiencing deteriorating neurological symptoms.

Because of the progression of neurological symptoms, with support of the above mentioned guidelines, we were able to successfully performed emergency LSCS and spinal surgery during the third trimester of our pregnancy, which was at 36 weeks of gestation. We believe that MDT (multidisciplinary treatment) is critical for ensuring a good prognosis. Our MDT group consisted of obstetricians, anesthesiologists, neurosurgeons, and neonatologists, to ensure the best outcomes for the mother and the foetus.

## CONCLUSION

Spinal schwannoma is a rare occurrence in pregnancy and can cause considerable worsening of outcomes. However, with a multidisciplinary team approach, as used in the management of our case, the delivery of the foetus can be safe, and the neural compression can be revealed.

## Learning Points / Take Home Messages

**Vigilant Monitoring:** Pregnant patients with neurological symptoms need close observation,

especially if symptoms escalate swiftly.

**Differential Diagnosis:** Rapid symptom aggravation aids in distinguishing between typical pregnancy-related changes and spinal tumours.

**Prompt Follow-up:** Immediate medical attention is crucial for accurate diagnosis and management.

**Multidisciplinary Approach:** Involvement of a diverse medical team ensures safe outcomes for both mother and fetus.

**Timely Intervention:** Early detection and treatment by a multidisciplinary team improve prognosis and reduce risks during pregnancy

**Conflict of interest:** None

**Funding:** None

**Ethics Declaration:** No ethical issued involved in the case report.

## REFERENCES

1. Wiyanjana KDF, Putra KK, Maliawan S, Gotra IM. Spinal Schwannoma as Pregnancy Related Spinal Tumor. *Neurol Spinale Medico Chir* [Internet]. 2020 Jan 6 [cited 2024 Sep 25];2(3). Available from: <http://nsmc.indoscholar.com/index.php/nsmc/article/view/80>
2. Han IH, Kuh SU, Kim JH, Chin DK, Kim KS, Yoon YS, *et al.* Clinical approach and surgical strategy for spinal diseases in pregnant women: a report of ten cases. *Spine*. 2008 Aug 1;33(17):E614-619.
3. Chen R, Xiao A, Xing L, You C, Liu J. A rare thoracic intraspinal schwannoma in twin pregnancy with aggravated clinical presence: A case report following CARE. *Medicine (Baltimore)*. 2017 Mar;96(11):e6327.
4. Kawaguchi K, Akeda K, Takegami N, Kurata T, Toriyabe K, Ikeda T, *et al.* Cervical schwannoma in the early stage of pregnancy: a case report. *BMC Surg*. 2020 Dec;20(1):245.
5. Meng T, Yin H, Li Z, Li B, Zhou W, Wang J, *et al.* Therapeutic strategy and outcome of spine tumors in pregnancy: a report of 21 cases and literature review. *Spine*. 2015 Feb 1;40(3):E146-153.
6. Nossek E, Ekstein M, Rimon E, Kupfermich MJ, Ram Z. Neurosurgery and pregnancy. *Acta Neurochir (Wien)*. 2011 Sep;153(9):1727-35.