

## Supra Ventricular Tachycardia in Pregnancy

Uzma Khanam<sup>1</sup>, Aisvarya Kapoor<sup>2</sup>, K Datta<sup>3</sup>

### How to cite this article:

Uzma Khanam, Aisvarya Kapoor, K Datta/Supra Ventricular Tachycardia in Pregnancy/Indian J Emerg Med 2022;8(2):45–49.

### Abstract

The physiological changes during pregnancy predispose female of new-onset or recurrent arrhythmia. Supraventricular arrhythmia is that the commonest sort of arrhythmia during pregnancy and, although often benign in nature. We describe a complex case of supraventricular arrhythmia during pregnancy and review the currently available literature. In pregnancies complicated by arrhythmia, a follow-up and both maternal and fetal monitoring during pregnancy, delivery and post partum should be made. Diagnostic modalities should be used as in non-pregnant women. All antiarrhythmic drugs cross the placenta, but when necessary, medical treatment should be used.

Electrical cardioversion is safe during pregnancy, and electrophysiological study and catheter ablation sometimes performed in selected patients, preferably with zero-fluoroscopy technique. Sometimes, delivering the fetus (if viable) is that the best therapeutic option.

**Keywords:** Pregnancy; Supra-Ventricular Tachycardia.

### INTRODUCTION

Anatomical, hemodynamic and hormonal changes of maternal physiology make pregnancy a high-risk period for the occurrence of new onset arrhythmia, or the recurrence of pre-existing arrhythmia. The maternal intravascular volume expands up to 45% throughout pregnancy, to compensate in systemic vascular resistance that facilitates the formation of the uteroplacental circulation.<sup>1</sup> The quantity

expansion causes atrial and ventricular stretch, which together with a physiologically increased pulse and contractility, increased sympathetic activity and altered catecholamine sensitivity creates an arrhythmogenic state. Arrhythmia risk peaks within the trimester. Maternal risk factors are previous arrhythmia, advanced maternal age, African ancestry and congenital heart condition, during which surgical scars and aberrant cardiac anatomy compound things.

Data on the prevalence of arrhythmia during pregnancy are scarce and conflicting, and lack clarity because complaints of palpitations are common and predominantly benign. Arrhythmia was observed in 68 per 100 000 pregnancy related hospitalisations, which probably underestimates the entire prevalence considering the extra cases of arrhythmia without hospitalisation. Supraventricular arrhythmias are more common than ventricular arrhythmias and can be the main

**Author Affiliation:** <sup>1</sup>Resident, <sup>2</sup>Attending Consultant, <sup>3</sup>Associate Director, Department of Emergency Medicine, Max Hospital, Shalimar Bagh, New Delhi-110088, India.

**Corresponding Author:** Aisvarya Kapoor, Attending Consultant, Department of Emergency Medicine, Max Hospital, Shalimar Bagh, New Delhi-110088, India.

**E-mail:** dr.sajidn@gmail.com

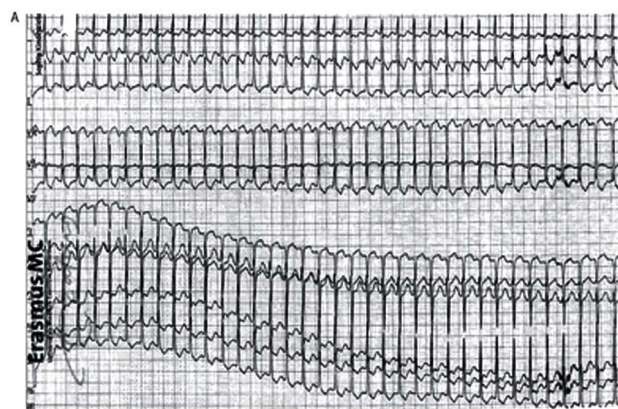
**Received on:** 21.03.2022

**Accepted on:** 16.04.2022

target of this review.

Atrial fibrillation or flutter (AF, 31–59 per 100 000 pregnancies) is the most frequently reported arrhythmia in pregnancy, with a growing prevalence in the past two decades that may be partly explained by the increasing maternal age.<sup>7,9</sup> Non-AF supraventricular tachycardia (SVT) is reported in 22–33 per 100 pregnancies,<sup>5,7,10</sup> including atrioventricular (nodal) re-entry tachycardia (AV(N)RT) and atrial tachycardia.

Although most arrhythmias are benign, they're related to increased maternal mortality (OR 13 for AF and OR 6 for SVT).<sup>7</sup> Appropriate workup and multidisciplinary management are therefore important, but the literature to guide clinical decisions is scarce.



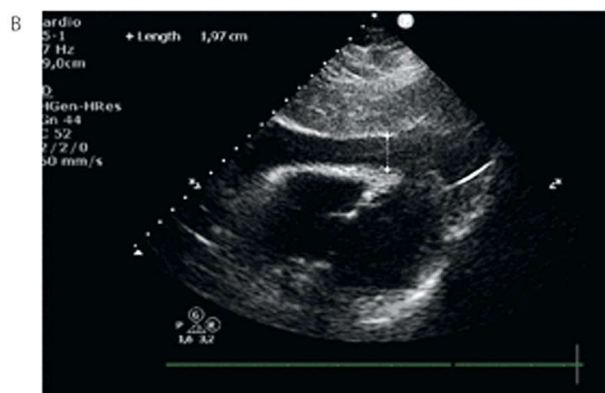
ECG and echocardiogram of a lady aged 38 years at 16 weeks of gestation, presenting with atrioventricular (nodal) re-entry tachycardia (AV(N)RT).

(A) ECG of a daily supraventricular tachycardia of 205 bpm with an intermediate axis and a narrow QRS complex. A retrograde P wave was observed 120 ms behind the QRS complex, implicational an AV(N)RT.

According to the ESC guidelines, our multidisciplinary pregnancy heart team classified her as WHO II, as all supraventricular arrhythmia without underlying structural heart condition.<sup>11</sup> Rhythm-surveillance level 1 was recommended during delivery. An EP study with ablation was discussed, but we decided to first pursue pharmacological treatment and only perform an ablation just in case of refractory complaints. Verapamil 120 mg once daily replaced the metoprolol, and she was advised to avoid excessive exertion. The dosage was gradually increased to 120 mg 3 times daily, with a suitable but incomplete result on the

## CASE REPORT

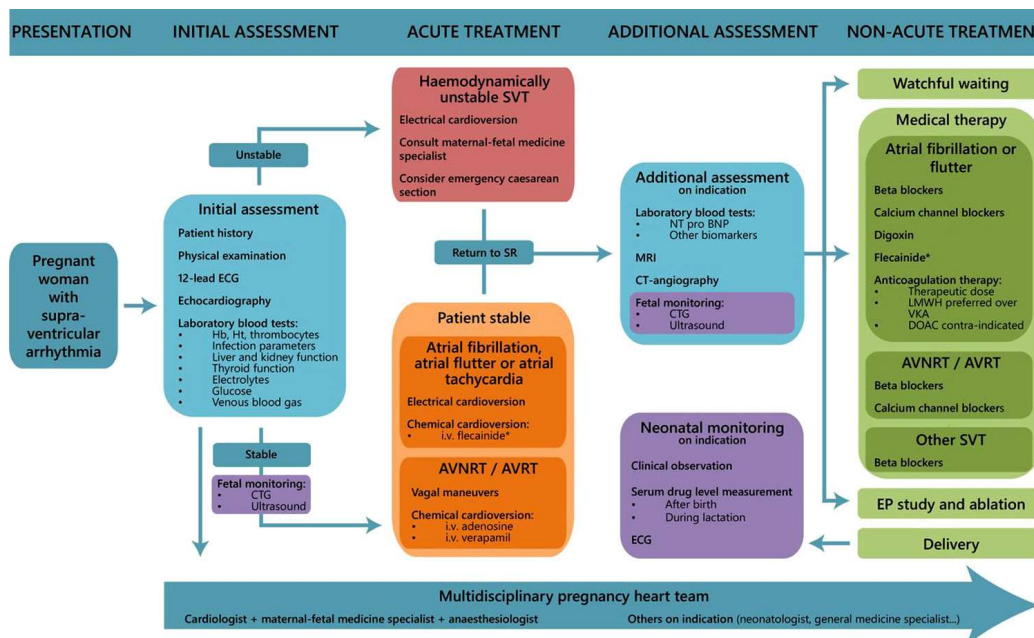
A primigravid woman aged 38 years presented at 16 weeks of gestation at a secondary hospital with palpitations that had increased in intensity during pregnancy. She had no history of cardiac disease. She was diagnosed with an AV(N)RT and treated with metoprolol 12.5 mg twice daily without sufficient effect, after which she was referred to our centre. Here, the ECG showed a regular SVT of 205 bpm with an intermediate axis and a narrow QRS complex (figure 3A). A mid-RP narrow complex tachycardia was observed, consistent with AVNRT, AVRT or less likely atrial tachycardia. The arrhythmia terminated after administration of inj adenosine 6mg iv stat, but afterwards many recurrences were observed, provoked by light physical activity. There were no signs of congestion. An echocardiogram showed that there was no structural heart disease.



frequency and intensity of her complaints. The fetal status and growth were monitored regularly within the obstetric outpatient clinic with CTG and fetal ultrasound, and remained reassuring. Labour was induced at 37 weeks of gestation due to the persisting complaints of arrhythmia. The patient had an uncomplicated delivery of a girl of 3585 g (90th percentile), with Apgar scores of 9/10. Because of the maternal verapamil use during pregnancy and lactation, the neonate was observed for twenty-four hours. The neonatal heart rate and ECG were normal, while the serum verapamil levels were very low and below therapeutic range.

## DISCUSSION

We have described case of supraventricular arrhythmia during pregnancy where different forms of intervention were necessary. Below figure presents a step-by-step guide for the diagnosis and management of supraventricular arrhythmia in pregnancy. We discuss the current knowledge on the subject, using the cases and the figure as a framework.



Flow chart of the diagnosis and treatment of supraventricular arrhythmia during pregnancy. \*Flecainide is relatively contraindicated in women with structural heart disease, and is also contraindicated in case of atrial flutter due to risk of 1:1 AV conduction. AVNRT, atrioventricular nodal re-entry tachycardia; AVRT, atrioventricular re-entry tachycardia; CTG, cardiogram; DOAC, direct oral anticoagulants; EP, electrophysiological; Hb, haemoglobin; Ht, haematocrit; LMWH, low molecular weight heparin; NT-proBNP, N-terminal pro b-type natriuretic peptide; SR, sinus rhythm; SVT, supraventricular tachycardia; VKA, vitamin K antagonist.

### CONCLUSIONS

Pregnancy creates an arrhythmogenic environment and the pregnant population is increasingly at risk of arrhythmias. Starting at the initial presentation, a multidisciplinary approach is crucial to balance maternal cardiac, obstetric and fetal considerations. In any case, optimal maternal health is a prerequisite for good fetal health, so diagnostic modalities and therapeutic options (such as electrical or chemical cardioversion) should be used where necessary and not be avoided or delayed due to the fetus. Knowledge of the physiology of pregnancy helps to predict the consequences and consequences of interventions and drug therapy. A good secondary assessment for underlying causes of arrhythmia, like structural heart condition or endocrine disorders, shouldn't be forgotten. However, often the pregnancy itself is that the most vital contributor

to the burden of arrhythmia, and therefore the delivery of the child is usually a viable therapeutic option.

*Conflict of Interest:* None Declared

### REFERENCES

1. de Haas S, Ghossein-Doha C, van Kuijk SMJ, et al, Physiological adaptation of maternal plasma volume during pregnancy: a systematic review and meta-analysis. *Ultrasound Obstet Gynecol* 2017;49:177-87. doi:10.1002/uog.17360pmid:http://www.ncbi.nlm.nih.gov/pubmed/28169502 CrossRefPubMedGoogle Scholar
2. Brodsky M, Doria R, Allen B, et al. New-onset ventricular tachycardia during pregnancy. *Am Heart J* 1992;123:933-41. doi:10.1016/0002-8703(92)90699-Vpmid:http://www.ncbi.nlm.nih.gov/pubmed/1550003CrossRefPubMedWeb of ScienceGoogle Scholar
3. Meah VL, Cockcroft JR, Backx K, et al. Cardiac output and related haemodynamics during pregnancy: a series of meta-analyses. *Heart* 2016;102:518-26. doi:10.1136/heartjnl-2015-308476pmid:http://www.ncbi.nlm.nih.gov/pubmed/26794234 Abstract/FREE Full TextGoogle Scholar
4. Shotan A, Ostrzega E, Mehra A, et al. Incidence of arrhythmias in normal pregnancy and relation to palpitations, dizziness, and syncope. *Am J Cardiol* 1997;79:1061-4. doi:10.1016/S0002-9149(97)00047-7pmid:http://www.

- ncbi.nlm.nih.gov/pubmed/9114764 CrossRefPubMedWeb of ScienceGoogle Scholar
5. Li J-M, Nguyen C, Joglar JA, et al. Frequency and outcome of arrhythmias complicating admission during pregnancy: experience from a high-volume and ethnically-diverse obstetric service. *Clin Cardiol* 2008;31:538-41. doi:10.1002/clc.20326pmid:http://www.ncbi.nlm.nih.gov/pubmed/19006111CrossRefPubMedWeb of ScienceGoogle Scholar
  6. Tateno S, Niwa K, Nakazawa M, et al. Arrhythmia and conduction disturbances in patients with congenital heart disease during pregnancy: multicenter study. *Circ J* 2003;67:992-7.doi:10.1253/circj.67.992pmid:http://www.ncbi.nlm.nih.gov/pubmed/14639012 CrossRefPubMedWeb of ScienceGoogle Scholar
  7. Vaidya VR, Arora S, Patel N, et al. Burden of arrhythmia in pregnancy. *Circulation* 2017;135:619-21.doi:10.1161/CIRCULATIONAHA.116.026681pmid:http://www.ncbi.nlm.nih.gov/pubmed/28154000 FREE Full TextGoogle Scholar
  8. Silversides CK, Harris L, Haberer K, et al. Recurrence rates of arrhythmias during pregnancy in women with previous tachyarrhythmiaandimpactonfetalandneonatal outcomes. *Am J Cardiol* 2006;97:1206-12. doi:10.1016/j.amjcard.2005.11.041pmid:http://www.ncbi.nlm.nih.gov/pubmed/16616027 CrossRefPubMedWeb of ScienceGoogle Scholar
  9. Lee M-S, Chen W, Zhang Z, et al. Atrial fibrillation and atrial flutter in pregnant Women-A population-based study. *J Am Heart Assoc* 2016;5:e003182. doi:10.1161/JAHA.115.003182pmid:http://www.ncbi.nlm.nih.gov/pubmed/27076563 Abstract/FREE Full TextGoogle Scholar
  10. Lee K-T, Chang S-H, Kuo C-F, et al. Incidence and time course of symptomatic paroxysmal supraventriculartachycardiaduringpregnancy: a nation-wide database study. *ActaCardiol Sin* 2020;36:44-9.doi:10.6515/ACS.202001\_36(1).20190707Apmid:http://www.ncbi.nlm.nih.gov/pubmed/31903007PubMedGoogle Scholar
  11. Regitz-Zagrosek V, Roos-Hesselink JW, Bauersachs J, et al. 2018 ESC guidelines for the management of cardiovascular diseases during pregnancy. *Eur Heart J* 2018;39:3165-241. doi:10.1093/eurheartj/ehy340pmid:http://www.ncbi.nlm.nih.gov/pubmed/30165544 CrossRefPubMedGoogle Scholar
  12. Brugada J, Katritsis DG, Arbelo E, et al. 2019 ESC guidelines for the management of patients with supraventricular tachycardiaThe Task force for the management of patients with supraventricular tachycardia of the European Society of cardiology (ESC). *Eur Heart J* 2020;41:655-720.doi:10.1093/eurheartj/ehz467pmid:http://www.ncbi.nlm.nih.gov/pubmed/31504425 PubMedGoogle Scholar
  13. Goy J-J, Fromer M. Antiarrhythmic treatment of atrioventriculartachycardias. *J Cardiovasc Pharmacol* 1991;17:S41-40.doi:10.1097/00005344-199100176-00008pmid:http://www.ncbi.nlm.nih.gov/pubmed/1723116 PubMedGoogle Scholar
  14. Byerly WG, Hartmann A, Foster DE, et al. Verapamil in the treatment of maternal paroxysmal supraventricular tachycardia. *Ann Emerg Med* 1991;20:552-4.doi:10.1016/S0196-0644(05)81615-4pmid:http://www.ncbi.nlm.nih.gov/pubmed/2024796 CrossRefPubMedWeb of ScienceGoogle Scholar
  15. Ramlakhan KP, Johnson MR, Roos-Hesselink JW. Pregnancy and cardiovascular disease. *Nat Rev Cardiol* 2020;17:718-31.doi:10.1038/s41569-020-0390-zGoogle Scholar
  16. Ruys TPE, Roos-Hesselink JW, Hall R, et al. Heart failure in pregnant women with cardiac disease: data from the ROPAC. *Heart* 2014;100:231-8.doi:10.1136/heartjnl-2013-304888pmid:http://www.ncbi.nlm.nih.gov/pubmed/24293523Abstract/Free Full TextGoogle Scholar
  17. Salam AM, Ertekin E, van Hagen IM, et al. Atrial Fibrillation or Flutter During Pregnancy in Patients With Structural Heart Disease: Data From the ROPAC (Registry on Pregnancy and Cardiac Disease). *JACC Clin Electrophysiol* 2015;1:284-92.doi:10.1016/j.jacep.2015.04.013pmid:http://www.ncbi.nlm.nih.gov/pubmed/29759316 Abstract/Free Full TextGoogle Scholar
  18. Drenthen W, Pieper PG, Roos-Hesselink JW, et al. Outcome of pregnancy in women with congenital heart disease: a literature review. *J Am Coll Cardiol* 2007;49:2303-11.doi:10.1016/j.jacc.2007.03.027pmid:http://www.ncbi.nlm.nih.gov/pubmed/17572244 Free Full TextGoogle Scholar
  19. Szekely P, Snaith L. Atrial fibrillation and pregnancy. *Br Med J* 1961;1:1407-10. doi:10.1136/bmj.1.5237.1407pmid:http://www.ncbi.nlm.nih.gov/pubmed/13774531 Free Full TextGoogle Scholar
  20. Hindricks G, Potpara T, Dagres N, et al. 2020 ESC guidelines for the diagnosis and management of atrial fibrillation developed in collaboration with the European association for Cardio-Thoracic surgery (EACTS): the task force for the diagnosis and management of

- atrial fibrillation of the European Society of cardiology (ESC) developed with the special contribution of the European heart rhythm association (EHRA) of the ESC. *Eur Heart J* 2021;42:373–498. doi:10.1093/eurheartj/ehaa612pmid:http://www.ncbi.nlm.nih.gov/pubmed/32860505 CrossRefPubMedGoogle Scholar
21. Wang Y-C, Chen C-H, Su H-Y, et al. The impact of maternal cardioversion on fetal haemodynamics. *Eur J Obstet Gynecol Reprod Biol* 2006;126:268–9. doi:10.1016/j.ejogrb.2005.11.021pmid:http://www.ncbi.nlm.nih.gov/pubmed/16377063 CrossRefPubMedGoogle Scholar
  22. Barnes EJ, Eben F, Patterson D. Direct current cardioversion during pregnancy should be performed with facilities available for fetal monitoring and emergency caesarean section. *BJOG* 2002;109:1406–7. doi:10.1046/j.1471-0528.2002.02113.xpmid:http://www.ncbi.nlm.nih.gov/pubmed/12504980 CrossRefPubMedGoogle Scholar
  23. Masuda K, Ishizu T, Niwa K, et al. Increased risk of thromboembolic events in adult congenital heart disease patients with atrial tachyarrhythmias. *Int J Cardiol* 2017;234:69–75. doi:10.1016/j.ijcard.2017.02.004pmid:http://www.ncbi.nlm.nih.gov/pubmed/28209388 PubMedGoogle Scholar
  24. Chang S-H, Kuo C-F, Chou I-J, et al. Outcomes associated with paroxysmal supraventricular tachycardia during pregnancy. *Circulation* 2017;135:616–8. doi:10.1161/Circulationaha.116.025064pmid:http://www.ncbi.nlm.nih.gov/pubmed/28153999 Free Full TextGoogle Scholar
  25. Fitton CA, Steiner MFC, Aucott L, et al. In-utero exposure to antihypertensive medication and neonatal and child health outcomes: a systematic review. *J Hypertens* 2017;35:2123–37. doi:10.1097/HJH.0000000000001456pmid:http://www.ncbi.nlm.nih.gov/pubmed/28661961 CrossRefPubMedGoogle Scholar
  26. Driver K, Chisholm CA, Darby AE, et al. Catheter ablation of arrhythmia during pregnancy. *J Cardiovasc Electrophysiol* 2015;26:698–702. doi:10.1111/jce.12675pmid:http://www.ncbi.nlm.nih.gov/pubmed/25828853 CrossRefPubMedGoogle Scholar
  27. Katritsis DG, Boriani G, Cosio FG, et al. European heart rhythm association (EHRA) consensus document on the management of supraventricular arrhythmias, endorsed by heart rhythm Society (HRS), Asia-Pacific heart rhythm Society (APHRS), and Sociedad Latinoamericana de Estimulación cardiaca y Electrofisiología (SOLAECE). *Europace* 2017;19:465–511. doi:10.1093/europace/euw301pmid:http://www.ncbi.nlm.nih.gov/pubmed/27856540 PubMedGoogle Scholar
  28. Chen G, Wang Y, Proietti R, et al. Zero-fluoroscopy approach for ablation of supraventricular tachycardia using the EnsiteNavX system: a multicenter experience. *BMC Cardiovasc Disord* 2020;20:48. doi:10.1186/s12872-020-01344-0pmid:http://www.ncbi.nlm.nih.gov/pubmed/32013865 PubMedGoogle Scholar
  29. Koźluk E, Piątkowska A, Kiliszek M, et al. Catheter ablation of cardiac arrhythmias in pregnancy without fluoroscopy: a case control retrospective study. *Adv Clin Exp Med* 2017;26:129–34. doi:10.17219/acem/68275pmid:http://www.ncbi.nlm.nih.gov/pubmed/28397444 PubMedGoogle Scholar
  30. Fink T, Sciacca V, Feickert S, et al. Outcome of cardiac tamponades in interventional electrophysiology. *Europace* 2020;22:1240–51. doi:10.1093/europace/euaa080pmid:http://www.ncbi.nlm.nih.gov/pubmed/32500141 PubMedGoogle Scholar
  31. Briggs GG, Freeman RK, Yaffe SJ. *Drugs in pregnancy and lactation*. Philadelphia: Lippincott Williams & Wilkins, 2009

