

## An Atypical Presentation of Acute Coronary Syndrome

Sudip Chakraborty<sup>1</sup>, Debanjana Mukherjee<sup>2</sup>, Souvik Goswami<sup>3</sup>

### How to cite this article:

Sudip Chakraborty, Debanjana Mukherjee, Souvik Goswami/ An Atypical Presentation of Acute Coronary Syndrome/Indian J Emerg Med 2022;8(1):27–29.

### Abstract

A 62 year old male patient was presented in ER due to the sudden onset of a precordial chest pain for an hour which aggravated in the last 30 minutes along with vomiting. The patient had no medical co-morbidities as such but had a known case of haemorrhoids and was a chronic smoker. On admission, he was conscious about the time and place and his vitals were HR: 50, BP: 110/70 mm of hg, RR: 20/min, SPO2: 99% (RA), CBG: 163 mg/dl. We could not find any evidence of MI in ECG, or any wall motion abnormality in ECHO but the patient was still complaining of chest pain and diaphoresis even post getting treated with isosorbide dinitrate and ranolazine. So, we took the patient to the Cath lab for a coronary angiography, which revealed LCX proximal 95-99% disease and RCA minor plaque in mid-part and diffuse disease in distal RCA. Primary PCI to LCX was done and treated conservatively. From this particular case, we learnt the significance of coronary angiography in ACS even if there was no significant finding on ECG, ECHO or cardiac enzymes.

**Keywords:** Acute coronary syndrome; Coronary angiography; Chest pain; No regional wall motion abnormality; ECG.

**Message:** Coronary Angiography played a major role to rule out acute coronary syndrome even though there was no change in ECG, cardiac markers and 2D-Echocardiography.

### Introduction

“Acute Coronary Syndrome (ACS) is an absolute medical emergency. Something dramatic, right this minute is going on in the arteries that is hurting the blood flow to the heart.” said Ann Bolger, a cardiologist from San Francisco General Hospital and member of American Heart Association. The risk factors of ACS are divided into 2

categories Modifiable (Smoking, hyperlipidaemia, hypertension, diabetes, obesity, cocaine use) & Non-modifiable: age, male, family history, ethnicity. Patient may show symptoms like Chest pain (heavy or crushing) radiating to either one or both arms, jaw, neck, back or stomach, sweating, nausea, vomiting, shortness of breath, dizziness or light-headedness.

**ACS can be further categorised into 3 traditional types:** ST Elevation Myocardial Infarction (STEMI), Non-ST Elevation Myocardial Infarction (NSTEMI) and Unstable Angina. ACS denotes a variety of coronary artery diseases that ranges from acute myocardial ischaemia to myocardial infarction. ACS is caused by Atheroma (plaque) rupture- 60% cases and atheroma erosion 30% cases, causing thrombus formation leading to blockage in coronary arteries. 60% STEMI caused by plaque rupture, 30% STEMI by plaque erosion and in case of NSTEMI just the opposite.

**Author Affiliation:** <sup>1</sup>Consultant and Head of the Department, <sup>2</sup>Postgraduate 1st Year Student, <sup>3</sup>RMO, ICU, Department of Emergency Medicine, B P Poddar Hospital and Medical Research Pvt. Ltd., New Alipore 700053, Kolkata West Bengal, India.

**Corresponding Author:** Sudip Chakraborty, Consultant and Head of the Department, Department of Emergency Medicine, B P Poddar Hospital and Medical Research Pvt. Ltd., New Alipore 700053, Kolkata West Bengal, India.

**E-mail:** sudip.emed@gmail.com

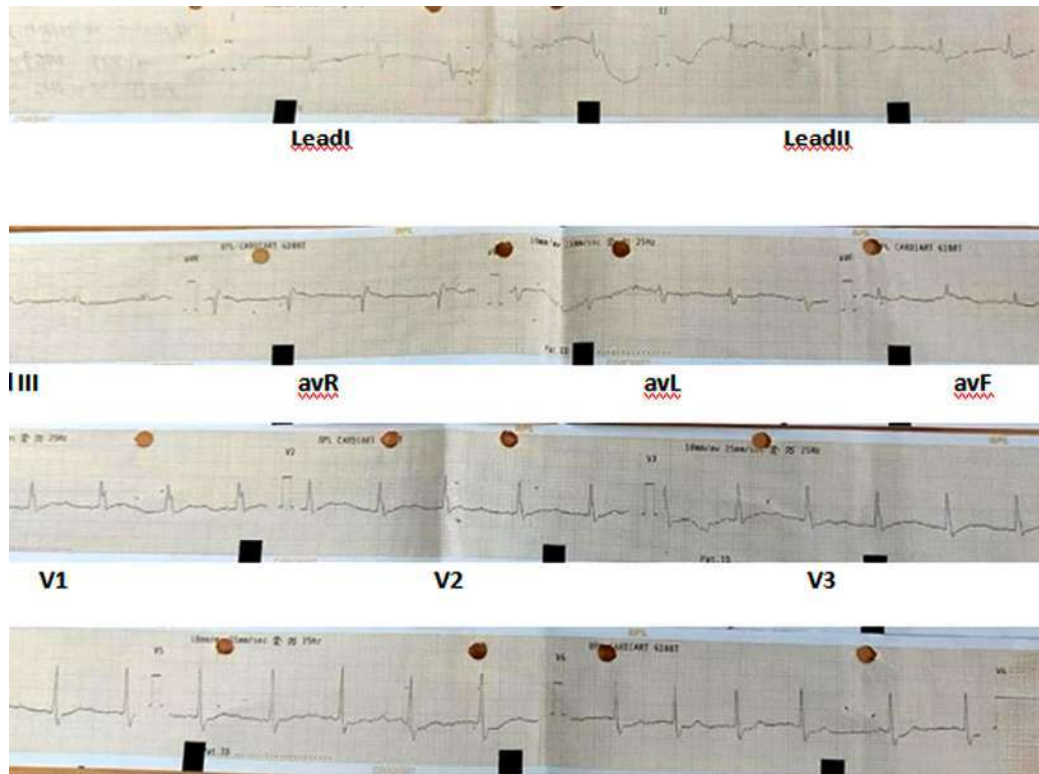
**Received on:** 23.12.2021

**Accepted on:** 12.02.2022

**ACS can be diagnosed by ECG: STEMI:** there is a complete blockage of the coronary artery, where we can see ST elevation in two or more anatomically

contiguous ECG leads. NSTEMI: there is a partial blockage of coronary artery where we may see ST segment depression or T inversion. Relevant blood

### ECG of the Patient



reports Blood reports: Troponin-T, Troponin-I, Cpk, Cpk-Mb, Ldh, Echo (2D), Coronary Angiography.

### Case Presentation

A 62 year old male patient was presented in ER due to the sudden onset of a precordial chest pain for an hour which aggravated in the last 30 minutes along with vomiting. The patient had no medical co-morbidities as such but had a known case of haemorrhoids and was a chronic smoker. We conducted necessary investigations in ER, ECG showed bi-fascicular blockage, Troponin T was negative, 2D-echocardiography revealed ejection fraction of 60% with no RMWA and mild TR with trivial MR. USG W/A revealed Hepatomegaly with grade II steatosis and epigastric probe tenderness. Blood investigations done urgently revealed Hb-12.0, TC-11.1, CRP-4.0, Urea-12, Creatinine-0.9, Na-140, K-3.8, LFT-normal, amylase-33, lipase-12, CK-93, CK-MB-14, LDH-140. PT-13.3, INR-1.1. In spite of getting treated with Tab. Isosorbide dinitrate & Tab. Ranolazine. The patient was still not getting

any comfort. He was continuously complaining of chest pain and diaphoresis, for which we took the patient to Cath lab within 30 minutes of arrival-for coronary angiography which revealed LCX proximal 95-99% disease and RCA minor plaque in mid part and diffuse disease in distal RCA. Primary PCI to LCX was done through right radial artery under local anaesthesia aseptically. The procedure was uneventful and patient was advised to take tab. aspirin (150mg) once daily, tab. clopidogrel (75mg) twice daily, tab. atorvastatin (80mg) once daily.

### Discussion

As we can see there was no evidence of myocardial infarction in ECG, Trop T, Trop I, CPK, CPK-MB, LDH. Even ECHO (2D) reports did not show any wall motion abnormality and LVEF was 60%. The patient was complaining of chest pain and vomiting-1 episode. As clinically the patient was showing symptoms, we went ahead with Coronary Angiography and incidentally revealed LCX proximal 95 - 99% disease and RCA minor plaque

in mid-part and diffuse disease in distal RCA.

Primary PCI to LCX was done through the right radial artery and the patient was advised for supportive medications.

### Conclusion

This case illustrated several interesting features. Here, we have a patient aged 62 years following chest pain and vomiting. The patient neither revealed any increase in cardiac enzymes nor any specific changes in ECG. Also, he had no regional wall motion abnormality in 2D-echocardiogram but his coronary angiography revealed double vessel disease which needed PCI.

### References

1. The Pharmaceutical Journal, 2015. Acute coronary syndrome guideline.
2. Hirachan, A., 2021. Rare Case of Dual Right Coronary Artery Intervention Presenting as Acute Coronary Syndrome. *Clinical Cardiology and Cardiovascular Interventions*, 04(16),pp.01-03.
3. Trost, J. and Lange, R., 2011. Treatment of acute coronary syndrome: Part 1: Non-ST-segment acute coronary syndrome. *Critical Care Medicine*, 39(10),pp.2346-2353.
4. Inami, S., Takano, M. and Mizuno, K., 2012. Acute Coronary Syndrome: Insights Based on Intravascular Imaging. *Journal of the Japanese Coronary Association*, 18(2),pp.107-117.
5. Chaowalit, N., Yipintsoi, T., Tresukosol, D., Kanjanavanit, R., Kiatchoosakun, S. and Representing the Thai Acute Coronary Syndrome Registry, 2009. Prognostic Value of Selected Presenting Features of Acute Coronary Syndrome in Predicting In-Hospital Adverse Events: Insight from the Thai Acute Coronary Syndrome Registry. *Internal Medicine*, 48(9),pp.639-646.
6. Millsaps, R., 1989. Echocardiogram Profiles After Acute Myocardial Infarction. *Critical Care Medicine*, 17(5),p.487.
7. Yavagal, S. and Baliga, V., 2019. Non-ischemic regional wall motion abnormality. *Journal of The Indian Academy of Echocardiography & Cardiovascular Imaging*, 3(1),p.7.
8. Yavagal, S. and Baliga, V., 2019. Non-ischemic regional wall motion abnormality. *Journal of The Indian Academy of Echocardiography & Cardiovascular Imaging*, 3(1),p.7.
9. azeem, s., 2018. Accuracy of 12 lead ECG for diagnosis of posterior myocardial infarction taking 15 lead ECG as gold standard. *Journal of Medical Biomedical And Applied Sciences*,6(9).
10. ŞAHİN, M., GÖRMELİ, C., DAĞ, N. and KURT, F., 2021. Comparison of multi-detector computed tomography coronary angiography with invasive coronary angiography in patients with coronary artery disease. *MedicalRecords*.
11. Soiza, R., Leslie, S., Harrild, K., Peden, N. and Hargreaves, A., 2005. Age-Dependent Differences in Presentation, Risk Factor Profile, and Outcome of Suspected Acute Coronary Syndrome. *Journal of the American Geriatrics Society*, 53(11),pp.1961-1965.
12. The Pharmaceutical Journal, 2020. Acute coronary syndrome: risk factors, diagnosis and treatment.

