

Recent Updates on Carcinosarcoma of the Uterus

Priyanka Yoga Purini¹, Sharmila V², Abhishek Raghava K S³,
Poongodi R⁴, Darshan H.N⁵

How to cite this article:

Priyanka Yoga. Purini, Sharmila V, Abhishek Raghava K S *et al.* Recent Updates on Carcinosarcoma of the Uterus. Indian J Obstet Gynecol. 2024;12(2):91-94.

Abstract

Carcinosarcoma is a very rare, aggressive malignant neoplasm of the uterus and it is associated with poor prognosis. We are presenting a case of a 66-year-old multiparous postmenopausal women who had bleeding for a period of 3 months. On MRI Imaging there is a 6 cm lesion in the endometrial cavity, biopsy from the endometrium showed carcinosarcoma and she underwent extrafascial hysterectomy with bilateral salpingoophorectomy, omentectomy, and retroperitoneal lymph node dissection. Postoperatively ascites is positive for malignant cells, histopathology of specimen reported as carcinosarcoma FIGO grade 3 and lymph nodes are positive for malignancy. She received adjuvant chemotherapy with carboplatin and paclitaxel.

Keywords: Post menopausal bleeding; Polypoidal mass; Carcinosarcoma; Malignant mixed mullein tumour.

INTRODUCTION

Carcinosarcomas are very rare, aggressive in nature and associated with poor prognosis irrespective of the stage of disease, the survival rate is 50% even in the early stage of the disease.¹ Carcinosarcoma of uterus accounts for 2%-5% of uterine malignancies.² The World Health Organization (WHO) classification of uterine neoplasms, uterine malignancies

containing both carcinomatous and sarcomatous elements are designated as carcinosarcoma. These neoplasms, also known as malignant mixed mullerian tumors, are usually seen among elderly postmenopausal women. These tumors are highly aggressive, and often present at an advanced stage, commonly FIGO III or IV. Uterine carcinosarcoma and endometrial carcinoma share similar risk factors, such as obesity, nulliparity, exogenous estrogen use, tamoxifen use. Oral contraceptive usage protects against the development of both. The sarcomatous component of these tumors may be either homologous (composed of tissues normally found in the uterus) or heterologous (containing tissues not normally found in the uterus, most commonly malignant cartilage or skeletal muscle). Most carcinosarcomas but not all, are monoclonal, derived from a single stem cell. The sarcomatous element is derived from the carcinomatous component by dedifferentiation.³ Spread of carcinosarcomas is primarily via lymphatics like endometrial carcinomas, whereas true sarcomas, commonly metastasise hematogenously. The behavior of these tumors are determined by the epithelial component. Epithelial elements invade the lymphatic, vascular

Author's Affiliation: ^{1,3,4}Assistant Professor, Department of Obstetrics and Gynaecology, ²Professor and Head, Department of Obstetrics and Gynaecology, ⁵Academic Junior Resident, Department of Obstetrics and Gynaecology, All India Institute of Medical Sciences, Mangalagiri 522503, Andhra Pradesh, India.

Corresponding Author: Priyanka Yoga Purini, Assistant Professor, Department of Obstetrics and Gynaecology, All India Institute of Medical Sciences, Mangalagiri 522503, Andhra Pradesh, India.

E-mail: priyankapurini@gmail.com

Received on: 30.04.2024 **Accepted on:** 20.05.2024



spaces and metastasize, whereas the spindle cell component has a very limited metastatic potential.¹ Immunohistochemistry staining of uterine carcinosarcoma tissue shows expression of p27, p53, p16, c-KIT, COX-2, EGFR, HER2/neu, the oncogene AKT, the PIK3C gene, and the PAX8 paired genes.⁴ Surgery is the main modality of treatment in carcinosarcoma of uterus. Extrafascial hysterectomy bilateral salpingoophorectomy with retroperitoneal lymph node dissection and omentectomy.⁵ Pelvic lymph node dissection is advised in all stages of uterine carcinosarcoma.⁴ Adjuvant chemotherapy with ifosfamide alone or in combination with platinum based drugs improves overall survival compared to adjuvant vaginal brachytherapy. Carboplatin and paclitaxel are another set of chemotherapeutic agents which have proven good survival outcomes.⁴ Here we present a case of the carcinosarcoma of uterus successfully managed surgically, followed by adjuvant chemotherapy.

CASE REPORT

A 66-year-old postmenopausal woman presented to us with complaints of bleeding on and off for a period of 3 months. Her obstetric index was P3L3 with normal vaginal delivery, and she was tubectomised. She was a known case of diabetes and hypertension for 10 years. A history of transient ischemic attack 10 years ago for that she was taking only Aspirin. On examination, her vitals were stable. The abdominal examination was normal. Per speculum examination revealed approximately 2 cm x 1 cm mass protruding through the cervical os and the external os is seen as a rim around the polypoidal mass, and it is not bleeding on touch. Per vaginal examination also revealed the same findings: the cervix felt like a rim around the mass, and vaginal

fornices were free of tumor. On rectal examination, rectal mucosa and bilateral parametrium are free of tumor. Endometrial and endocervical biopsy done at some other hospital is suggestive of endocervical adenocarcinoma, IHC positive for P16, P53 and negative for ER. She had been further evaluated at our institute, MRI imaging showed well-defined T1 hypo intense, T2 heterogenous lesion measuring 6.3x3.2 cm was noted distending the endometrial cavity and endocervical canal with myometrial shining, restriction on DWI and corresponding low ADC value, the lesion showed heterogenous post contrast enhancement suggestive of Endometrial carcinoma. As there is a discrepancy between HPE and imaging, biopsy was done once again. Biopsy from the growth, endocervical and endometrial regions and HPE were suggestive of carcinosarcoma, probably endometrial origin. She underwent Extrafascial hysterectomy, bilateral salpingoophorectomy with omentectomy and retroperitoneal lymph node dissection. Intraoperatively she had minimal ascites which was sent for cytology, and was positive for malignant cells. Her postoperative period was uneventful. Macroscopically, the cut section of the uterus showed an exophytic growth grey-white-to-grey-brown-tumor measuring 4.5x5cm extending less than half of the myometrium. The rest of the specimen was normal. Microscopically, it was suggestive of carcinosarcoma FIGO grade 3, there was no cervical stromal invasion (Fig a, b). However, lymphovascular space invasion was present. Bilateral tubes, ovaries and momentum were unremarkable. Her pelvic lymph nodes were involved by a tumor. FIGO staging is stage IIIC. Further plan of management is discussed at our multidisciplinary tumor board and planned for adjuvant chemotherapy with carboplatin and paclitaxel for 6 cycles once in three weeks.

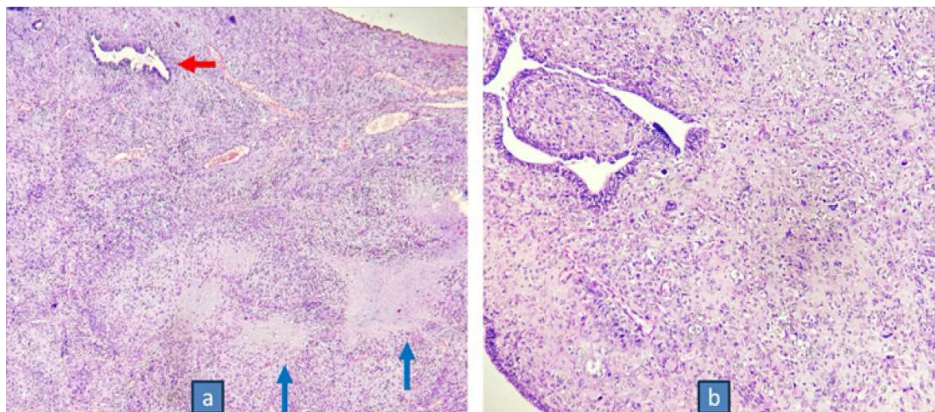


Fig. a: Microphotograph showing tumor with predominantly sarcomatous areas with cartilaginous matrix differentiation (blue arrows) and focal glandular differentiation (red arrow) (H&E, X40)

Fig. b: Microphotograph in higher power showing tumor with atypical glands and sheets of mesenchymal tumor cells (H&E, X400)

Brief Note

Histopathology slides revealed a tumor Composed of the glandular and mesenchymal differentiation. The glands are lined by atypical cells with minimal stratification and the mesenchymal areas are composed of sheets of polygonal to spindle shaped cells with focal cartilaginous differentiation (Fig. a, b).

DISCUSSION

Endometrial carcinosarcoma is a rare and aggressive high-grade endometrial carcinoma, accounting for 5% of all uterine malignancies and nearly 20% of non-endometrioid endometrial cancer. Endometrial carcinosarcoma is responsible for 15% of deaths from uterine malignancies.⁶ Carcinosarcoma of the uterus is usually seen among postmenopausal women. The risk factors for carcinosarcoma includes pelvic exposure to irradiation, obesity, nulliparity, exposure to the human papillomavirus or exogenous estrogen, history of tamoxifen therapy, black race. These tumors are associated with a poor prognosis. Carcinosarcomas have a monoclonal origin from a common multidirectional progenitor stem cell. These neoplasms are derived from the Müllerian epithelium's single stem cells, which undergo metaplasia or dedifferentiation resulting in the sarcomatous elements.⁷ It is diagnosed at an advanced stage more often compared to other endometrial cancers. The stage at diagnosis follows a bimodal distribution: 40–50% of cases are early stage (International Federation of Gynecology and Obstetrics (FIGO) I–II) and 50–60% are advanced (FIGO III–IV). Up to 30–40% of patients present with lymph node metastases at diagnosis, and 10% have distant metastatic spread, especially in the lungs. Over 60% of patients with apparently early-stage disease at the time of initial diagnosis due to occult metastatic spread, these tumors are upstaged following comprehensive surgical evaluation. The prognosis remains poor despite the multimodal treatment strategy (surgery, platinum-based chemotherapy, radiotherapy). The median overall survival is less than 2 years, and the 5-year overall survival rate is less than 30% (about 50% and 20% in early and advanced stages, respectively). In early stage disease, the 5-year recurrence rate is 45% and 5-year related mortality of 50%. The average age of the patients at the time of diagnosis is 67 years.⁷ The most common symptom of this malignancy is post-menopausal bleeding or spotting, discharge per vagina, abdominal pain and these are similar to endometrial adenocarcinoma. These tumors are a

rapidly growing fleshy polypoidal mass protruding through the cervix into the vaginal canal. Diagnosis is made by biopsy from the endometrium or from the polypoidal mass. In this case, the age of the patient at the time of diagnosis is 66 years, presented with postmenopausal bleeding. On examination, a polypoid fleshy mass is seen through the cervical os protruding into the vaginal canal. Imaging techniques such as ultrasonography, CT scan of the abdomen and thorax or MRI of the pelvis are useful for staging and metastasis workup. Endometrial carcinosarcoma is now considered as a primary endometrial carcinoma, its treatment is similar to that of other nonendometrioid high-grade endometrial cancer, as per ESGO/ESTRO/ESP and the National Comprehensive Cancer Network (NCCN) guidelines.^{8,9} The main stay of treatment is combined multimodal approach surgery, chemotherapy and/or radiotherapy. Surgical management is by extrafascial hysterectomy, bilateral salpingoophorectomy with retroperitoneal pelvic lymph node dissection with infracolicomentectomy. Peritoneal cytology is not mandatory as it is not a cancer staging factor, but it can be useful as a risk factor for tailoring the adjuvant treatment.^{8,10} In our patient, sampling of endometrium and polypoidal mass revealed carcinosarcoma, and on further work up MRI is suggestive of endometrial carcinoma. Then she underwent hysterectomy with bilateral salpingoophorectomy, retroperitoneal lymph node dissection with infracolicomentectomy. Peritoneal cytology is positive for malignant cells. Histopathology of the hysterectomy specimen showed carcinosarcoma with lymph node metastasis. Based on the results from the GOG-232B and GOG-261 trials, it is recommended that carboplatin/paclitaxel doublet is the preferred first-line treatment for endometrial carcinosarcoma, given the non-inferiority and the better toxicity profile, compared with ifosfamide/paclitaxel. Based on the results of several trials, recently immunotherapy (with or without tyrosine kinase inhibitor) is emerging as the standard treatment modality after the failure of platinum-based chemotherapy. Pembrolizumab plus lenvatinib represents the preferred treatment for non-endometrioid endometrial cancer.

The majority of endometrial carcinosarcomas share molecular and genomic similarities with high-grade serous ovarian carcinoma and serous endometrial carcinoma, pmutations such as TP53 (60–97%), FBXW(10–44%), PPP2R1A(11–30%), HER2 (9–18%) serous-like mutations are common. Whereas the minority resembles the endometrioid

counterpart, such as ARID1A (10–25%), KRAS (8–15%), PTEN (10–50%), and PIK3CA (20–40%) are less frequent.¹¹ The analysis of The Cancer Genome Atlas (TCGA) Research Network and the Proactive Molecular risk classifier for Endometrial cancer (ProMisE) classification, four novel molecular endometrial cancer subgroups were identified.¹² The new classification includes POLE/ultramutated (POLE mutated), microsatellite- instable/hypermuted (MSI-H), copy-number-high/TP53-abnormal (P53-abn), and copy-number-low/TP53-wild-type or non-specific molecular profile endometrial cancers. The TCGA study included only the endometrioid and serous histotypes, while limited data is known regarding less common endometrial cancer histotypes, such as endometrial carcinosarcoma.¹³ A meta-analysis of four studies (231 patients) reported the pooled prevalence of the TCGA groups among endometrial carcinosarcomas 5.3% POLE, 7.3% MSI-H, 73.9% p53-abnormal, and 13.5% non-specific molecular profile. The majority of endometrial carcinosarcoma (73.9%) are classified within the serous like, p53-abn risk group (which accounts for 5–15% of endometrial cancers and resembles type II endometrial cancers). These tumors are characterized by advanced stage at diagnosis, late onset, mutant like/abnormal p53 immunohistochemical staining, low mutational burden (<10 mutations per megabase), aggressive behavior, high risk of early relapse, and a dismal prognosis. POLE mutated endometrial carcinosarcoma showed an excellent prognosis similar to that of POLE mutated endometrioid endometrial cancers, supporting their inclusion in the same low-risk category for treatment purposes. On the other hand, the prognosis of p53-abn and non-specific molecular profile endometrial carcinosarcoma is worse than that of their endometrioid/serous counterparts. Where as MSI-H/dMMR tumors are unclear and remains to be clarified.⁶

REFERENCES

1. Anupama R, Kuriakose S, Vijaykumar DK, Pavithran K, Jojo A, Indu RN, Sheejamol VS. Carcinosarcoma of the uterus-a single institution retrospective analysis of the management and outcome and a brief review of literature. *Indian J Surg Oncol.* 2013 Sep;4(3): 222-8. doi: 10.1007/s13193-012-0206-7. Epub 2013 Jan 27. PMID: 24426726; PMCID: PMC3771046.
2. Adachi, Y., Nonogaki, H., Minamiguchi, S., Li, M., & Ikehara, S. (2016). Carcinosarcoma of the uterus: A case report. *Molecular and Clinical Oncology*, 4, 571-573. <https://doi.org/10.3892/mco.2016.744>.
3. McCluggage WG. Malignant biphasic uterine tumours: carcinosarcomas or metaplastic carcinomas? *J Clin Pathol.* 2002 May;55(5):321-5. doi: 10.1136/jcp.55.5.321. PMID: 11986333; PMCID: PMC1769650.
4. Menczer J. Review of Recommended Treatment of Uterine Carcinosarcoma. *Curr Treat Options Oncol.* 2015 Nov;16(11):53. doi: 10.1007/s11864-015-0370-4. PMID: 26374341.
5. Jaime Prat, 'Nomonde Mbatani Uterine sarcomas. *International Journal of Gynecology & Obstetrics* pages: S105-S110 Volume 131 Issue S2 First Published online: 11 October 30, 2018 <https://doi.org/10.1002/ijgo.12613>.
6. Bogani G, Ray-Coquard I, Concin N, *et al.* *Int J Gynecol Cancer* 2023;33:147-174.
7. Tuan HX, Duc NM, Tri CM, Quyen HD, Dung PX. Carcinosarcoma of uterus. *Radiol Case Rep.* 2023 Jan 15;18(3):1297-1301. doi: 10.1016/j.radcr.2022.12.070. PMID: 36684637; PMCID: PMC9851838.
8. Concin N, Planchamp F, Abu-Rustum NR, *et al.* European Society of Gynaecological Oncology quality indicators for the surgical treatment of endometrial carcinoma. *Int J Gynecol Cancer* 2021;31:1508-29.
9. Abu-Rustum NR, Yashar CM, Bradley K, *et al.* NCCN Guidelines® insights: uterine neoplasms, version 3.2021. *J Natl Compr Canc Netw* 2021;19:888-95.
10. Matsuzaki S, Klar M, Matsuzaki S, *et al.* Uterine carcinosarcoma: contemporary clinical summary, molecular updates, and future research opportunity. *Gynecol Oncol* 2021;160:586-601.
11. Raffone A, Travaglino A, Raimondo D, *et al.* Uterine carcinosarcoma vs endometrial serous and clear cell carcinoma: a systematic review and meta-analysis of survival. *Int J Gynaecol Obstet* 2022;158:520-7.
12. Travaglino A, Raffone A, Raimondo D, *et al.* Prognostic value of the TCGA molecular classification in uterine carcinosarcoma. *Int J Gynaecol Obstet* 2022;158:13-20.
13. Cancer Genome Atlas Research Network, Kandoth C, Schultz N, *et al.* Integrated genomic characterization of endometrial carcinoma. *Nature* 2013;497:67-73.