

# Role of SWCR Guidelines in the Management of Hand Injury

Dripta Ramya Sahoo<sup>1</sup>, Ravi Kumar Chittoria<sup>2</sup>, Barath Kumar Singh P<sup>3</sup>

## How to cite this article:

Dripta Ramya Sahoo, Ravi Kumar Chittoria, Barath Kumar Singh P/Role of SWCR Guidelines in the Management of Hand Injury/Indian Journal of Medical & Health Sciences. 2022;9(2):57-63.

## Abstract

Society for Wound Care and Research was founded with the aim of promoting practice of better wound care and research. The society carries out academic, clinical, research and social activities in a calculated manner aimed at improving wound healing. SWCR guidelines has 4 components with the acronym SWCR where S stands for systematic analysis of patient and wound, W for wound bed preparation, C for clinical decisions and R for repair, reconstruct & rehabilitate. Hand injury is a commonly seen and a leading cause of work related disability. Appropriate wound management and meticulous reconstruction followed by rehabilitation in a systematic manner is of utmost importance in these patients to improve quality of life and return to work in them. Injuries of the hand are particularly challenging from the view point of healing and reconstruction as they require restoration of both functionality and aesthetics. These difficulties can be overcome by systematically approaching the wound through SWCR guidelines. This review article provides a summary of the benefits of using SWCR guidelines in the management of hand injuries.

**Keywords:** Hand injury; SWCR; Guidelines; Management.

## INTRODUCTION

Hand injuries attribute to between 6.6 and 28.6% of all musculoskeletal injuries and thereby

pose a common challenge with regards to healing and reconstruction.<sup>1-7</sup> Patients with hand injuries are most often treated as outpatients as they tend to be vitally stable but in certain cases with higher debilitation, in patient stay has been warranted. Early evaluation and management are of utmost importance towards regaining functionality as well as on the aesthetic ground. Most of the people affected are middle aged workers who are economically active and restoration of functionality has a tremendous impact on their quality of lives.<sup>1-8</sup> These patients require a meticulous approach from their presentation, evaluation to reconstruction and restoration of functionality. These problems have been successfully tackled by systematically approaching the wound with SWCR guidelines

**Author Affiliation:** <sup>1</sup>Junior Resident, <sup>3</sup>Senior Resident, Department of Plastic Surgery, <sup>2</sup>Professor & Head of IT Wing and Telemedicine, Department of Plastic Surgery & Telemedicine, Jawaharlal Institute of Postgraduate Medical Education and Research, Pondicherry 605006, India.

**Corresponding Author:** Ravi Kumar Chittoria, Professor & Head of IT Wing and Telemedicine, Department of Plastic Surgery & Telemedicine, Jawaharlal Institute of Postgraduate Medical Education and Research, Pondicherry 605006, India.

**E-mail:** drchittoria@yahoo.com

**Received on:** 10.10.2022

**Accepted on:** 03.11.2022

(Fig. 1).<sup>9-11</sup> As per these guidelines, the patient is first systematically evaluated with through history, including all factors that could impact wound healing and reconstruction, followed by detailed examination of the wound to plan appropriate management. Appropriate investigations are also included in this first step. Following this, the next aim of wound bed preparation is sorted. The

hybrid reconstruction ladder approach is taken into account here where novel tissue regenerative techniques compliment traditional practices in wound bed preparation.<sup>11-13</sup> Then, clinical decisions are then made taking into account patient factors and patient's response to administered therapies. Finally, repair, reconstruction with either flaps or grafts and rehabilitation come into play.

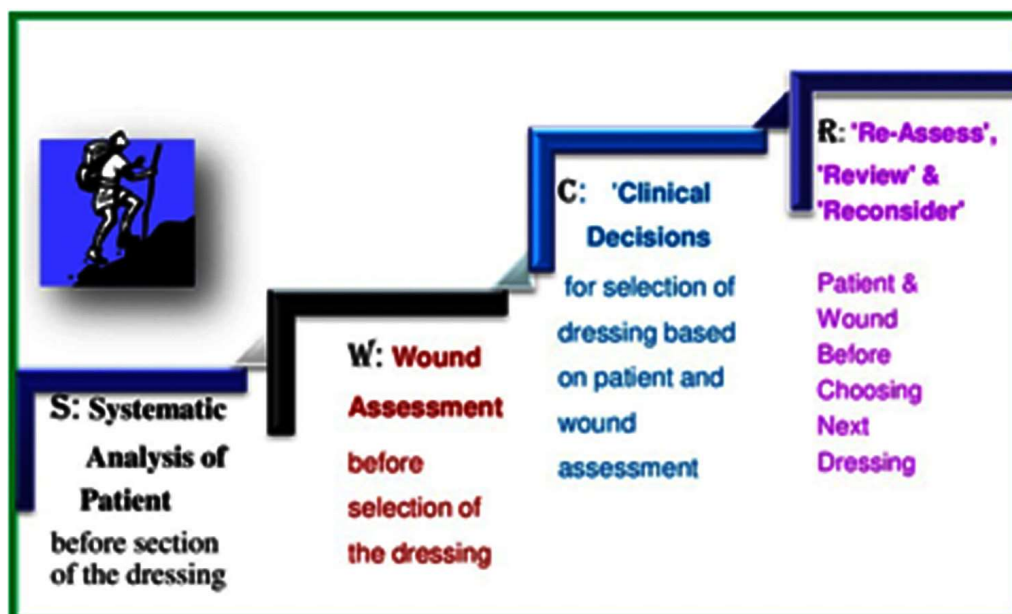


Fig. 1: SWCR guidelines

## MATERIALS AND METHODS

This study was done at JIPMER hospital after obtaining approval of departmental scientific and ethics committee. Informed consent was obtained from the patient. This case report is on a 45-year-old male, a known case of major depressive disorder on antidepressants, who presented with post traumatic necrotic ulcer over palmar aspect of right hand of size 4 x 4 cm. The injury was sustained by self fall from a two wheeler causing injury to right palm. He presented a month later with a patch over his right palm (Fig. 2). Detailed history was taken with special consideration about comorbidities which would impact wound healing. Examination of the wound was done and necrotic patch was identified over the wound. He then underwent wound debridement of the patch as the initial step for wound bed preparation (Fig. 3). Novel regenerative techniques like Autologous Platelet rich Plasma (APRP) (Fig. 4), low level laser therapy (Fig. 5), collagen scaffold dressing, vit D and sucralfate dressing (Fig. 6) and negative pressure wound therapy (Fig. 7) were done to accentuate wound bed preparation.

Imaging of right hand was done suggesting no features of osteomyelitis. Patient was treated with appropriate antibiotics as per culture and

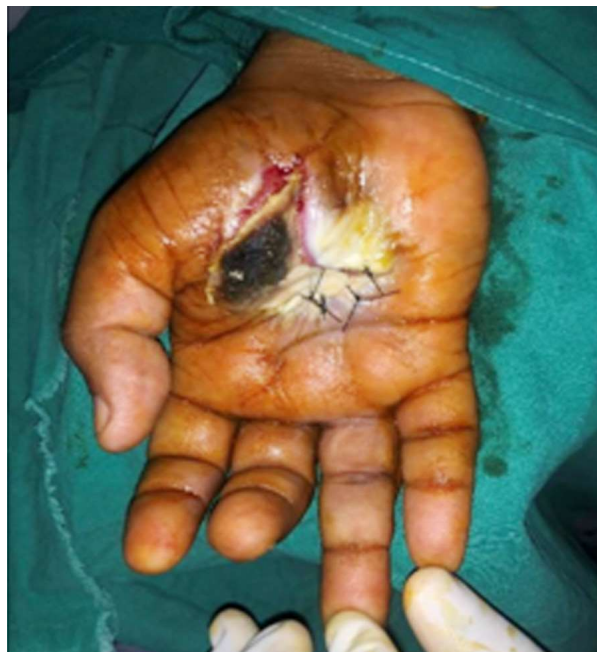

Fig. 2: Wound at presentation

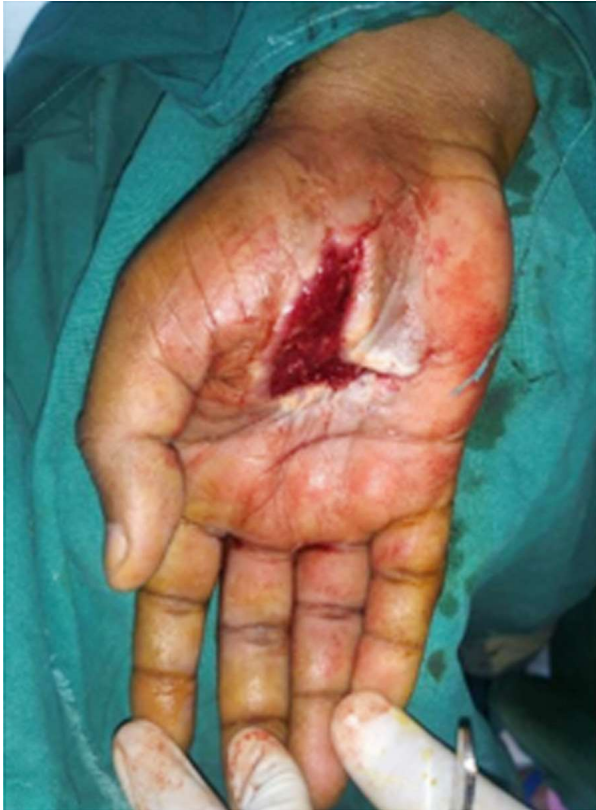

Fig. 3: Wound after debridement

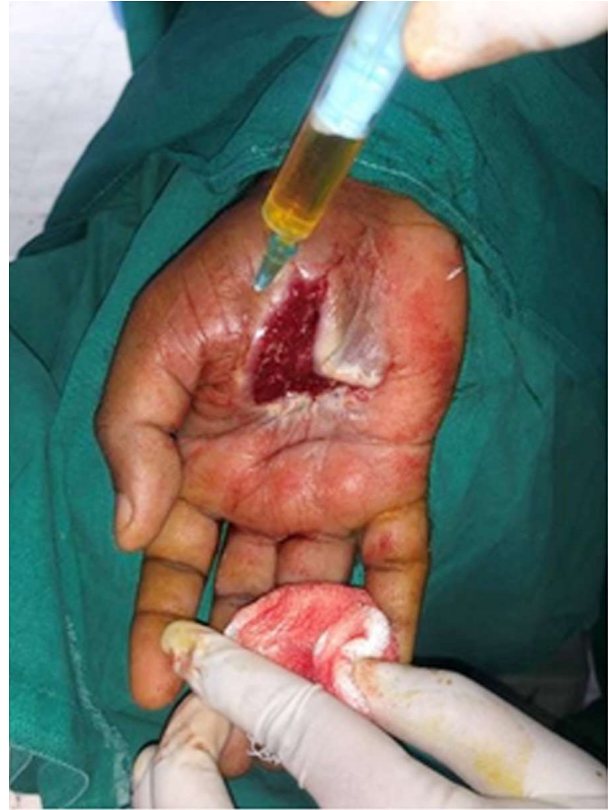

Fig. 4: APRP therapy

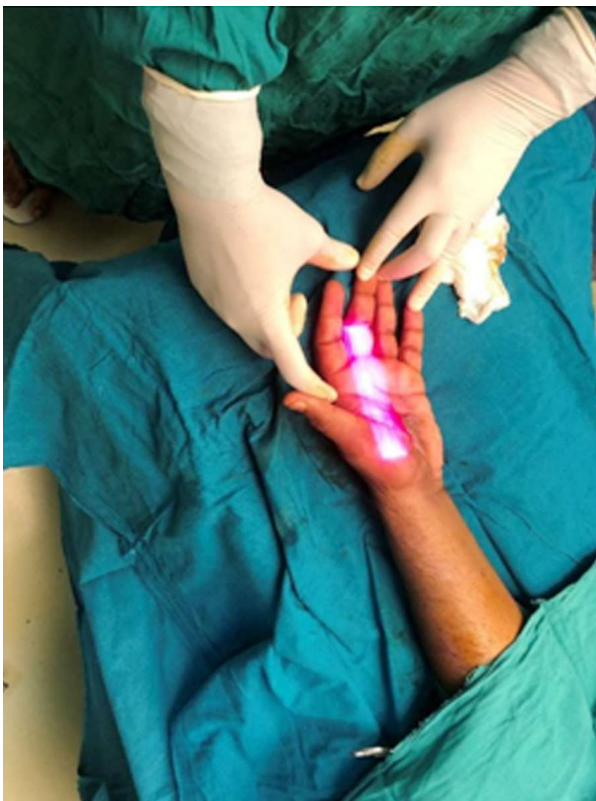


Fig. 5: Low level laser therapy

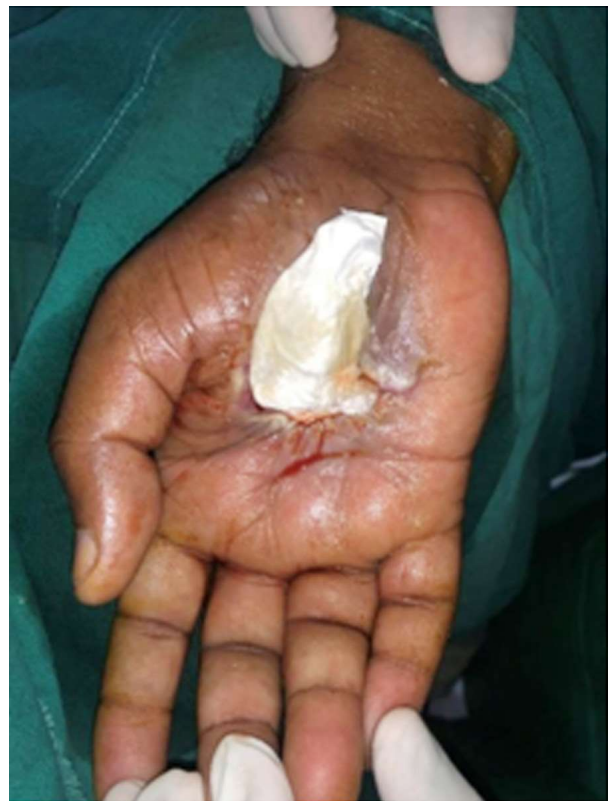

Fig. 6: Vitamin D and sucralfate dressing with collagen scaffold

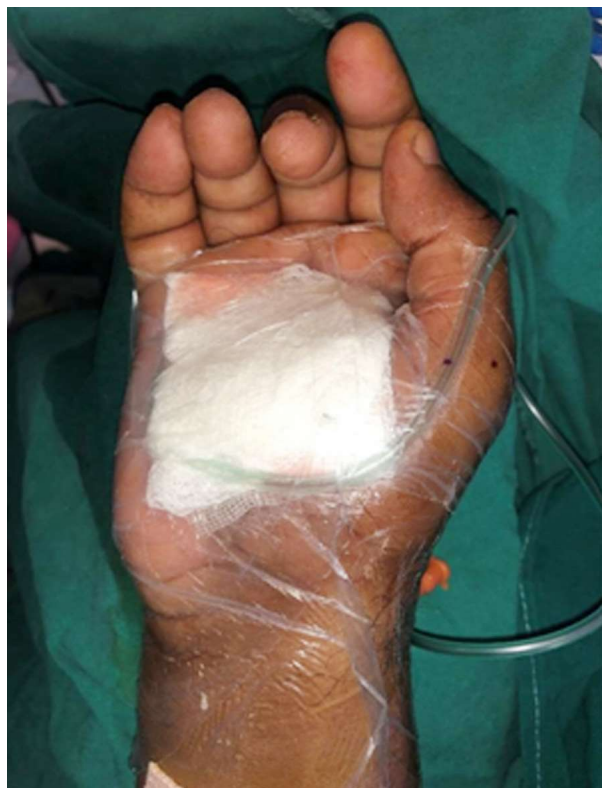

Fig. 7: Negative pressure wound therapy

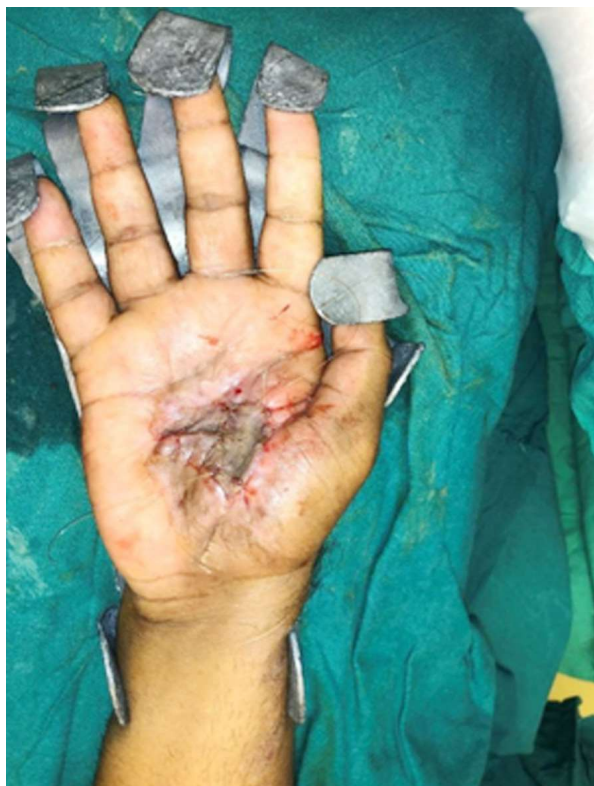

Fig. 9: Skin grafting done

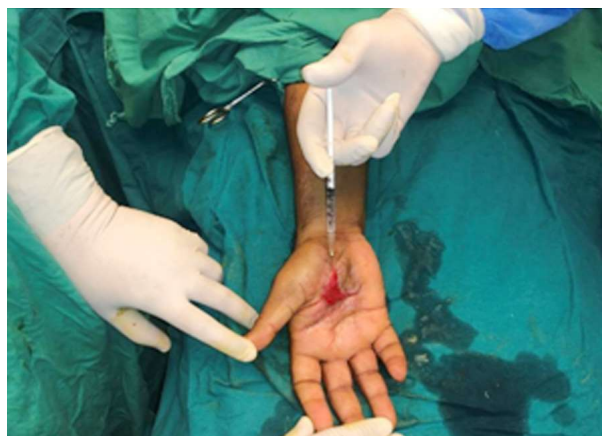

Fig. 8: Wound bed before grafting

sensitivity. Following this the wound showed good granulation and contraction (Fig. 8). The patient was planned for split skin grafting following a sterile culture. Split skin grafting was done over the raw area and satisfactory graft take was noted (Fig. 9). Patient was discharged and donor site healed well.

## RESULTS

In the above mentioned case study, SWCR guidelines played significant role in approach to the patient, wound bed preparation and reconstruction. Post procedure patient developed no complications

and good graft take was noted (Fig. 10). Patient was successfully discharged. Application of this systematic approach not only improved wound healing and reconstruction process, but also ensured good compliance from the patient.

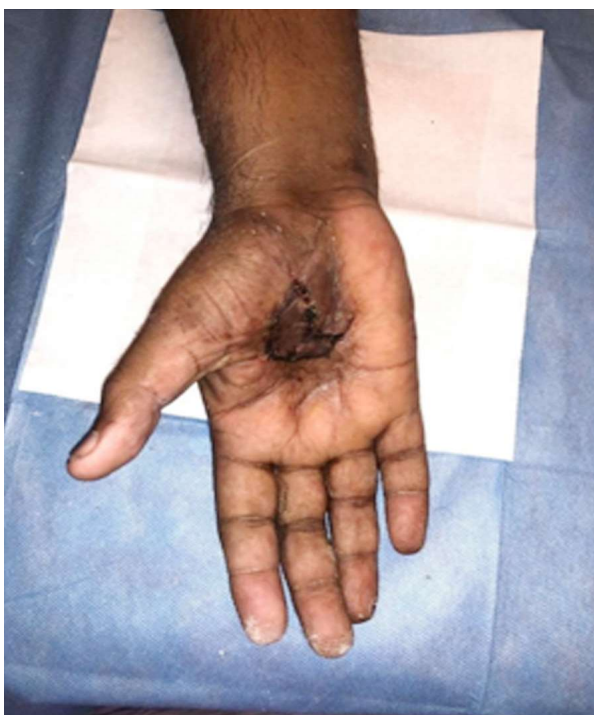

Fig. 10: Day 7 post skin graft

## DISCUSSION

The hand is a complex organ with mechanical and sensory components which work seamlessly to give rise to the function of the hand. Prehension is a term used for this integration of components: feeling, which is transfer of information from the environment to the brain, and response, the manipulation of objects. Loss or damage to any component in the system results in suboptimal functioning of the hand thereby making management of hand injuries a therapeutic challenge. Restoration of functionality and repair of hand injuries thereby requires a systematic approach.<sup>15-17</sup>

The Society for Wound Care and Research was founded in the year 2006 to promote practice of better wound care through a guideline based approach. The society promoted research and also tried to improve community outreach towards better wound care.<sup>9-11</sup> SWCR guidelines are applicable to all chronic wounds irrespective of aetiology. This systematic approach has a significant role in hand injuries.

### *The components of these guidelines include:*

- Systematic assessment of the patient and wound
- Wound bed and patient preparation
- Clinical decisions
- Repair, Reconstruction and Rehabilitation

### *Systematic assessment of the Patient and Wound*

A precise clinical assessment of the patient is the first step in this guideline based approach. A history of comorbidities and medications is important when wound healing is considered. Three essential questions that need to be asked include the time of injury, mechanism and the environment in which the injury occurred, which could suggest possible contaminants in the wound. Next, examination of the patient as a whole, to assess nutritional status followed by examination of wound is done. Triangle of wound assessment (TOWA) is a subjective tool that is used for clinical assessment of wound. It does so in 3 components wound bed, wound edge and peri wound skin. In wound bed, presence of exudate, infection/inflammation and non-viable tissue are noted. Wound edge is examined for undermining, sloping and granulation. Peri-wound skin is inspected to look for maceration, discoloration and excoriation.

Reliable wound healing instruments for periodic assessment of wound healing like Bates Jensen Wound Assessment Tool (BJWATS)<sup>17</sup>, Design tool, Wound Healing Scale (WHS),<sup>18</sup> Sassing Scale (SS), Sussman Wound Healing Tool (SWHT)<sup>19</sup> with ability to document changes in wound status over time may also be used.

### *Wound Bed and Patient Preparation:*

Wound bed preparation is of prime importance before any reconstructive procedure is planned. Along with traditional debridement, novel tissue regenerative techniques are also employed in this process.<sup>12-14</sup> There is an acronym 'TIMERS' which addresses the pathophysiological abnormalities underlying chronic wounds.<sup>20</sup>

T- Tissue management

I - Inflammation and infection control

M - Moisture control

E - Epithelialization

R - Regenerative therapies

S - Social factors like transportation, food, shelter.

### *Tissue management*

Debridement of devitalised tissue is the first step in wound bed preparation and is performed methodically from skin, subcutaneous tissue, muscle to bone while preserving nerves and intact vessels and tendons. This should create unquestionably healthy surgical margins for each tissue. A good debridement sets the stage for clear reconstruction goals and prevents post-operative complications such as ongoing tissue necrosis and infection that require repeated debridement.

Wound debridement also plays an important role in reducing the levels of bacterial biofilms, which are tightly attached to components of the extracellular matrix, surfaces of bones, surfaces of orthopaedic implants in the chronic wound beds.

### *Infection & Inflammation Management*

Presence of warmth, erythema, tenderness and purulent discharge points towards local infection. This is often controlled with local antimicrobials that do not harm normal cells like super oxidized solution or nano crystalline silver/ colloidal silver/ ionic silver.<sup>19</sup> In case systemic infection is suspected, appropriate management with antibiotics is necessary.

### **Moisture Management**

Excess moisture causes maceration whereas dryness causes tissue death. Optimal balance of moisture is of utmost importance in wound healing. Moisture is managed with appropriate dressing. Excess moisture in the wound needs compression bandages, highly absorbent dressings or Negative Pressure Wound Therapy, Vacuum Assisted Closure (VAC) or Limited Access Dressing (LAD) whereas dry wounds need moisture holding dressings like hydrogels.<sup>22</sup>

### **Edge of the wound Management**

Observation of a healthy sheet of epithelial cells migrating from the edge of a chronic wound is the most sensitive indicator of the effectiveness of the previous three components. This is achieved by proper debridement of undermined or calloused edges to obtain healthy epithelisation.

### **Regenerative therapies**

In the above case, novel regenerative therapies like Autologous Platelet rich Plasma (APRP), low level laser therapy (LLLT), collagen scaffold dressing, vit D and sucralfate dressing and negative pressure wound therapy were effectively employed. Dry collagen acts as a scaffold for tissue regeneration.<sup>22,23</sup> Platelets act as regulators of inflammation, angiogenesis, cell migration, and proliferation with the release of various growth factors and anti-inflammatory cytokines which is thought to help in faster and better healing of the wounds. Autologous platelet rich plasma (APRP) has growth factors which when injected in the wound site or sprayed, act at the intracellular level to bring about cell proliferation and healing of a wound.<sup>24</sup> LLLT is claimed to increase collagen synthesis, decrease inflammation and has a positive impact on scar remodeling. Negative Pressure Wound Therapy involve removal of exudates and infectious materials and contraction of wound margin. NPWT has been shown to be safe and effective in post debridement wounds.<sup>25</sup>

### **Social factors**

Access to medical facility, good nutrition and appropriate environment also play a vital role in healing of wounds.

### **Clinical decisions**

Optimisation of medical conditions like diabetes

mellitus, hypothyroidism along with physical factors which hinder wound healing like devitalised tissue or foreign body, is of importance in management of hand injuries.

### **Repair, Reconstruction and Rehabilitation**

Repair and reconstruction first require skeletal stabilisation. Following that, appropriate soft tissue cover is established either by graft or flap.<sup>14-16</sup> Hand injuries involve multiple tissue planes that heal by fibrosis. Adhesions and loss of gliding planes through scarring impair tendon function and joint motion. Nerve repairs have partial recovery, which is caused by axonal entrapment at the site of repair and loss of axons caused by fascicular mismatch. These problems need to be anticipated and rehabilitative measures need to be initiated as early as possible. Occupational therapist needs to be involved in formulating a plan that is safe to ensure maximal functional recovery ensuring good quality of life and return to work.<sup>8</sup>

## **CONCLUSION**

Hand injuries require restoration of mechanical, sensory functionalities while maintaining aesthetics and thereby pose a therapeutic challenge. As described in this case, the SWCR guidelines easily understood with the acronym SWCR (systemic analysis, wound bed preparation, clinical decisions, repair, reconstruction and rehabilitation) are effective in wound preparation and reconstruction of hand injuries.

**Conflicts of interest:** None

**Authors' contributions:** All authors made contributions to the article

**Availability of data and materials:** Not applicable.

**Financial support and sponsorship:** None.

**Consent for publication:** Not applicable

## **REFERENCES**

1. Gaul JS. Identifiable costs and tangible benefits resulting from the treatment of acute injuries of the hand. *J Hand Surg Am.* 1987; 12(5 Pt 2):966-70.
2. Burke FD, Dias JJ, Lunn PG, Bradley M. Providing care for hand disorders: trauma and elective. *J Hand Surg Br.* 1991; 16(1):13-8.
3. Trybus M, Lorkowski J, Brongel L, Hladki W. Causes and consequences of hand injuries. *Am J Surg.* 2006; 192(1):52-7.

4. De Putter CE, Selles RW, Haagsma JA, Polinder S, Panneman MJM, Hovius SER, et al. Health-related quality of life after upper extremity injuries and predictors for suboptimal outcome. *Injury*. 2014; 45(11):1752-8.
  5. Zárate-Ramírez JG, Espinosa-Gutiérrez A. ¿Cuánto valen las lesiones de la mano? *Acta Ortop Mex*. 2013; 27(5):345-349.
  6. Ootes D, Lambers KT, Ring DC. The epidemiology of upper extremity injuries presenting to the emergency department in the United States. *Hand (NY)*. 2012; 7(1): 18-22.
  7. Grivna M, Eid HO, Abu-Zidan FM. Epidemiology of isolated hand injuries in the United Arab Emirates. *World J Orthop*. 2016; 7(9):570-6.
  8. Wen Hsuan Hou, Ching Chi Chi, Heng Lien Lo, Yun Yun Chou, Ken N Kuo, Hung Yi Chuang. Vocational rehabilitation for enhancing return to work in workers with traumatic upper limb injuries. *Cochrane Database of Systematic Reviews* 2017, Issue 12.
  9. Briggs M, Nelson EA. Topical agents or dressings for pain in venous leg ulcers. *Cochrane Database Syst Rev*. 2003;1:CD001177.
  10. Abbade LP, Lastória S. Venous ulcer: epidemiology, physiopathology, diagnosis and treatment. *Int J Dermatol*. 2005;44(6):449-56.
  11. Mathes SJ, Nahai F. *Reconstructive Surgery: Principles, Anatomy & Technique*. Vol. 2. New York: Churchill Livingstone; St. Louis: Quality Medical; 1997.
  12. Gottlieb LJ, Krieger LM. From the reconstructive ladder to the reconstructive elevator. *Plast Reconstr Surg*. 1994;93:1503-4.
  13. Mohapatra, Devi Prasad M.Ch.; Thiruvoth, Friji Meethale M.Ch. *Reconstruction 2.0: Restructuring the Reconstructive Ladder, Plastic and Reconstructive Surgery: March 2021 - Volume 147 - Issue 3 - p572e-3e*.
  14. Lahiri A. Managing Mutilating Hand Injuries. *Clin Plastic Surg*. 2019; 46:351-7.
  15. Midgley RD, Entin MA. Management of mutilating injuries of the hand. *Clin Plast Surg* 1976;3(1):99-109.
  16. Moran SL, Berger RA. Biomechanics and hand trauma: what you need. *Hand Clin* 2003;19(1): 17-31.
  17. Wu W, Naim JO, Lanzafame RJ. The effect of laser irradiation on the release of bFGF from 3T3 fibroblasts. *Photochem Photobiol*. 1994;59(2):167-70.
  18. Vinck EM, Cagnie BJ, Cornelissen MJ, Declercq HA, Cambier DC. Increased fibroblast proliferation induced by light emitting diode and low power laser irradiation. *Lasers Med Sci*. 2003;18(2):95-9.
  19. Frigo L, Fávero GM, Lima HJ, Maria DA, Bjordal JM, et al. Low-level laser irradiation (InGaAlP-660 nm) increases fibroblast cell proliferation and reduces cell death in a dose-dependent manner. *Photomed Laser Surg*. 2010;28(Suppl 1):151-6.
  20. Basso FG, Oliveira CF, Kurachi C, Hebling J, Costa CA. Biostimulatory effect of low-level laser therapy on keratinocytes in vitro. *Lasers Med Sci*. 2013;28(2):367-374.
  21. Sureshbabu A, Okajima H, Yamanaka D, Shastri S, Tonner E, Rae C, et al. IGFBP-5 induces epithelial and fibroblast responses consistent with the fibrotic response. *Biochem Soc Trans* 2009;37:882-5.
  22. Vedder NB, Wei FC, Mardini S, eds. *Problem analysis in reconstructive surgery: Reconstructive ladders, elevators, and surgical judgment*. In: *Flaps and Reconstructive Surgery*. 2017;2nd ed. Toronto: Elsevier; 1-5.
  23. Turner NJ, Badylak SF. Biologic scaffolds for musculotendinous tissue repair. *Eur. Cell Mater*. 25, 130-143(2013).
  24. Tenenhaus M, Rennekampff HO. Surgical advances in burn and reconstructive plastic surgery: new and emerging technologies. *Clin. Plast. Surg*. 39(4), 435-443(2012).
  25. Saurabgupta et al. Effect Of Low Level Laser Therapy (Lllt) On The Severity Of Post-Burn Immature Scars: A Randomized Control Study. *International Journal of Clinical And Diagnostic Research* Volume 8, Issue 1, Jan-Feb 2020.
-