

CASE REPORT

Full Mouth Rehabilitation in a 3-Year-Old Female Child with Repaired Tetralogy of Fallot: A Case Report

Agrawal Pratiksha¹, Verma Preeti², Dubey Shashi³, Bokde Aditi⁴**HOW TO CITE THIS ARTICLE:**

Agrawal Pratiksha, Verma Preeti, Dubey Shashi, et al. Full mouth rehabilitation in a 3-Year-Old Female child with Repaired Tetralogy of Fallot: A Case Report. Ind J Anesth Analg. 2026; 13(2): 95-98.

ABSTRACT

Introduction: Tetralogy of Fallot (TOF) is a common congenital cyanotic heart disease. Despite successful surgical repair, patients remain at increased risk of complications during future surgeries, especially in procedures which predispose to infective endocarditis.

Case Report: A 3-year old female patient, suffering from chronic irreversible pulpitis was posted for a full mouth rehabilitation surgery under general anesthesia. She has history of tetralogy of Fallot (TOF) repair at 22 months of age. Current clinical and echocardiographic findings showed no major abnormalities. She underwent successful oral surgery under general anesthesia with due precautions and utmost care maintaining stable hemodynamic parameters peri-operatively.

Conclusion: This case highlights the successful perioperative management of a child with repaired TOF undergoing full mouth rehabilitation. Comprehensive preoperative evaluation, appropriate antibiotic prophylaxis, and tailored anesthetic technique contributed to a smooth outcome.

Key Messages: (Provide appropriate messages of about 35-50 words to be printed in centre box):

Anaesthetic management of patients with corrected congenital cardiac diseases requires specific and tailor-made approach taking into consideration the

AUTHOR'S AFFILIATION:

¹ Associate Professor, Department of Anaesthesiology and Pain Medicine, Pt. JNM Medical College and BRAM Hospital, Raipur, Chhattisgarh.

² PG Resident, Department of Anaesthesiology and Pain Medicine, Pt. JNM Medical College and BRAM Hospital, Raipur, Chhattisgarh.

³ PG Resident, Department of Anaesthesiology and Pain Medicine, Pt. JNM Medical College and BRAM Hospital, Raipur, Chhattisgarh.

⁴ PG Resident, Department of Anaesthesiology and Pain Medicine, Pt. JNM Medical College and BRAM Hospital, Raipur, Chhattisgarh.

CORRESPONDING AUTHOR:

Agrawal Pratiksha, Associate Professor, Department of Anaesthesiology and Pain Medicine, Pt. JNM Medical College and BRAM Hospital, Raipur, Chhattisgarh.

E-mail: dr.pratiksha.agrawal@gmail.com

Received : 27-01-2026

Accepted : 28-02-2026



anatomical and physiological variations of disease, corrective surgery and ongoing medications. Team approach involving a cardiologist, surgeon, paediatrician and anaesthesiologist is essential for successful outcome.

KEYWORDS

- Tetralogy of Fallot • Congenital cyanotic heart disease • Maxillofacial surgery
- anaesthetic management

INTRODUCTION

Tetralogy of Fallot (TOF) is the most common cyanotic congenital heart disease characterized by the presence of a ventricular septal defect, overriding aorta, right ventricular outflow tract obstruction and right ventricular hypertrophy.¹ With availability of advanced medical care there has been substantial improvement in prognosis and a 25-year transplant free survival after TOF repair is up to 94.5%.² This increases the number of patients with corrected heart diseases presenting for non-cardiac surgeries during different phases of life. Despite correction of the primary defect, perioperative risks remain high due to potential residual cardiac defects, altered physiology, associated congenital anomalies and susceptibility to infective endocarditis (IE). Any surgery in these patients demands a personalized anesthesia approach taking into consideration the medical and surgical history of the patient. Dental procedures, though minor, warrant careful consideration in these patients. Also, sparsity of literature describing the anesthetic risk poses a challenge in planning the management of such cases.

Case Report

A 3-year-old female, weighing 12.5 kg presented to oral and maxillofacial surgery department with complain of pain and swelling in the upper gums with history of occasional pus and blood discharge from left side. She was diagnosed with left chronic irreversible pulpitis and early childhood caries. The patient was scheduled for full mouth rehabilitation under general anesthesia. The child had a history of TOF, diagnosed at 3 months of age. It was repaired at 22 months of age with right ventricle-pulmonary artery conduit and patent ductus arteriosus ligation. Since then, she has been taking Tab. Aspirin 25 mg daily. As per history and physical examination the child was conscious and active. There was no history of cyanotic spells post-surgery, with

normal growth and developmental milestones. On physical examination vital signs were HR 100 beats/minute (regular rhythm), blood pressure 90/60 mmHg, SpO₂ 98% on room air. No cyanosis, clubbing, or any signs of heart failure were seen. Airway examination demonstrated a mouth opening of 3 finger breadth with MPG grade II. Cardiovascular examination revealed normal S1, S2 with a pansystolic murmur (possibly a flow murmur). No abnormalities were detected in any other organ systems. Complete blood count, liver function tests and renal function tests were within normal limits. ECG was suggestive of right axis deviation and right bundle branch block. Recent echocardiogram showed no residual shunt, right ventricular outflow tract (RVOT native) pressure gradient: 26 mmHg, conduit gradient: 18mmHg, trivial pulmonary regurgitation with good biventricular function. After thorough history and examination and cardiology consultation, patient was planned for a full - mouth rehabilitation under general anesthesia. She was started on IE prophylaxis Inj. Amoxiclav 200 mg IV TDS.

Patient was kept Nil per Oral (NPO) for 6 hours (solids), 2 hours (clear fluids). After a written informed consent from parents IV access was secured and Inj. Amoxiclav 200 mg was administered 30 minutes prior to surgery. Standard ASA monitoring with a precordial stethoscope was attached and baseline vital parameters were recorded. She was premedicated with Injection midazolam 0.6 mg, Injection Glycopyrrolate 0.06 mg and Injection Fentanyl 25mcg. After pre-oxygenation with 100% O₂ for 3 min, general anaesthesia was induced with Injection Etomidate 10 mg IV and Injection vecuronium 1.2 mg IV. Airway was secured with a 4.5mm internal diameter oral, cuffed, south - facing RAE endotracheal tube and a well lubricated oral pack was placed. Anesthesia was maintained with Oxygen, air, sevoflurane and "top-up" doses of Vecuronium. The patient

was adequately hydrated with 300 ml of Ringer lactate. Duration of the procedure was 3Hrs. The child remained hemodynamically stable throughout procedure. There were no episodes of hypoxia, hypotension, or arrhythmias during this period. A paracetamol suppository (125 mg) was inserted for post-operative pain relief. Reversal was done with Injection Glycopyrrolate 0.12 mg IV and Injection Neostigmine 0.6 mg IV. Patient was extubated after proper oral suctioning and monitored in HDU for 24 hr. Inj. Fentanyl (1mcg/kg) IV was administered when VAS score was more than 4. Antiemetics and antibiotics were continued as per schedule and the patient was discharged on 3rd post-operative day.

DISCUSSION

Around one in every 125 live births is affected by congenital heart disease (CHD). Out of these, approximately 10% of cases are attributed to Tetralogy of Fallot (TOF).³ Surgical correction is typically performed in infancy or early childhood. As medical field is advancing, many adults and children with repaired congenital anomalies present for a variety of surgical procedures during their lifetime. Early diagnosis and easy accessibility to healthcare enables timely correction of complex congenital heart diseases allowing

the affected children lead a normal, healthy life. While complete repair greatly improves outcomes, vigilance is necessary due to potential residual effects, neurodevelopmental sequelae or conduction abnormalities.⁴ Hence irrespective of the surgery, a complete cardiorespiratory and neurological evaluation becomes necessary during the pre-anesthetic check-up. Understanding the corrective procedure performed and its impact on normal physiology is essential in guiding the peri-operative management. Dental surgeries can cause transient bacteremia, making IE prophylaxis a prerequisite drug therapy. Continuation of ongoing Aspirin therapy is usually recommended; however, any drug modification should be guided by opinion of treating cardiologist. Avoidance of hypoxia, hypercarbia, acidosis and dehydration in the peri-operative period is crucial to prevent increase in pulmonary vascular resistance.⁵ Choice of induction agent is guided by residual cardiac defect and hemodynamics of the patient. Sevoflurane-based anesthesia with controlled ventilation is generally well tolerated. Adequate post-operative analgesia is essential for a smooth post-operative course, stable hemodynamics and calm, composed patient. It can be achieved by NSAIDS (Paracetamol, Diclofenac, Ketorolac, Etc.) or opioids (e.g. Fentanyl) as per requirement.

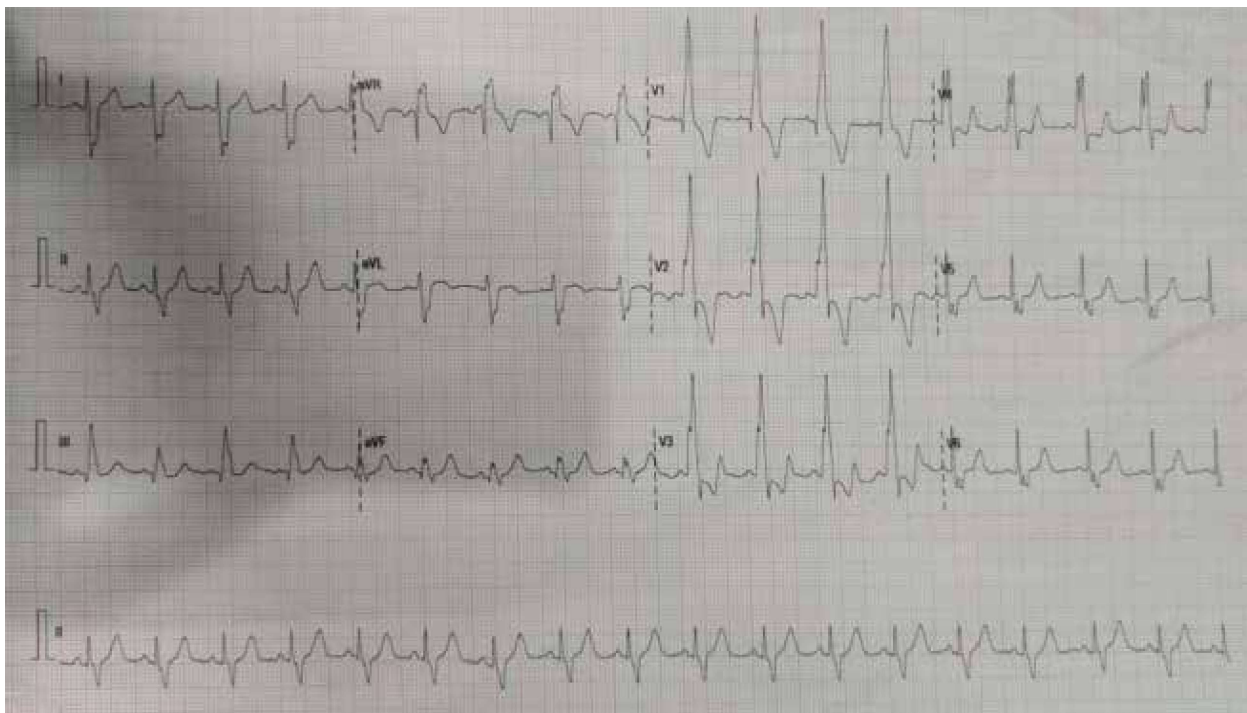


Figure 1: 12-lead ECG showing right axis deviation and right bundle branch block

CONCLUSION

This case highlights the successful perioperative management of a child with repaired TOF undergoing full mouth rehabilitation. Comprehensive preoperative evaluation, appropriate antibiotic prophylaxis, and tailored anesthetic technique contributed to a smooth outcome. Such cases emphasize the importance of multidisciplinary coordination between pediatricians, anesthesiologists, cardiologists, and dental surgeons.

REFERENCES

1. Wilson R., Ross O., Griksaitis M.J. Tetralogy of Fallot. *BJA Educ.* 2019; 19(11): 362-369. doi:10.1016/j.bjae.2019.07.003.
2. Smith C.A., McCracken C., Thomas A.S., Spector L.G., St Louis J.D., Oster M.E., *et al.* *JAMA Cardiol.* 2018 Dec 19; 4(1): 34-41. doi:10.1001/jamacardio.2018.4255.
3. White M.C., James M.P. Anaesthetic management of children with congenital heart disease for non-cardiac surgery. *Contin Educ Anaesth Crit Care Pain.* 2012; 12(1): 17-22. doi:10.1093/bjaceaccp/mkr049.
4. Mercer-Rosa L. and Favilla E. (2024) Neurodevelopment in patients with repaired tetralogy of Fallot. *Front. Pediatr.* 2024; 12:1137131. doi: 10.3389/fped.2024.1137131
5. Verma N., Madavi S., Jadhav J.A., Dash S., Chandak A. Anesthetic challenges in an infant with tetralogy of Fallot posted for non-cardiac surgery: a case report and literature review. *Cureus.* 2023; 15(10): e47327. doi:10.7759/cureus.47327. PMID: 38022008; PMCID: PMC10657144.
6. Miller R.D., Cohen N.H., Eriksson L.I., Fleisher L.A., Wiener-Kronish J.P., Young W.L., editors. *Miller's Anesthesia.* 9th ed. Philadelphia: Elsevier; 2020.