

Paratuberculosis (Johne's Disease): A Real Threat to Livestock and Livestock Owners

Rakesh Kumar¹, Venkataramireddy Balena¹, Manu Kurian Mathew¹,
Adya Prakash Rath², Saraswat Sahoo³, Subha Ganguly⁴

Abstract

Johne's disease (JD) is one of the important diseases of ruminants, which is capable of causing major economic losses to farmers in terms of decline in productivity. JD is very difficult to treat if once entered in livestock farms. It is a chronic granulomatous enteric infection of ruminants caused by *Mycobacterium avium* subsp. paratuberculosis (MAP). This organism was first reported by Johne and Frothingham in 1985. This infection is most often seen among domestic ruminants (cattle, sheep, goats, buffaloes and camels) as well as in wild ruminants. The disease has been reported in non-ruminants (pigs, horses, fox, lab animals) also.

Keywords: MAP; Diarrhea; Emaciation; Epitheloid Cells; Ruminants.

Introduction

This infection can also be transmitted through vertical route (in utero and infection through milk). Whatever is the route of infection but lesions are always seen in intestine. The critical age of the infection is 6 months (incubation period is 2 years). In lab animals no diarrhea and emaciation is evident, while in sheep and goats diarrhea is not seen but emaciation is one of the prominent sign. The intestinal lesions are characteristic of type III hypersensitivity. The lesions are mainly seen in

small intestine, but spread to colon and rectum also that's why rectal pinch and bowel wash is one of the reliable method for the detection of this *Mycobacteria*.¹

Three Strains are Mainly Seen in Different Animal Species:

Strains	Animal species
Cattle	Only cattle
Ovine	Sheep and Cattle both
Scottish (Chromogenic strain)	Sheep

AUTHOR'S AFFILIATION:

¹Division of Pathology, ICAR-IVRI, Izatnagar, Bareilly. ²Division of Pathology, LUVAS, Hisar, Haryana. ³Department of Animal Reproduction, Gynaecology & Obstetrics, OUAT, ⁴Department of Veterinary Microbiology, Arawali Veterinary College (Affiliated with RAJUVAS, Bikaner), Bajor, Sikar, Rajasthan, India.


CORRESPONDENCE AND REPRINT REQUESTS:

Subha Ganguly, Department of Veterinary Microbiology, Arawali Veterinary College (Affiliated with RAJUVAS, Bikaner), Bajor, Sikar-332001 Rajasthan, India.

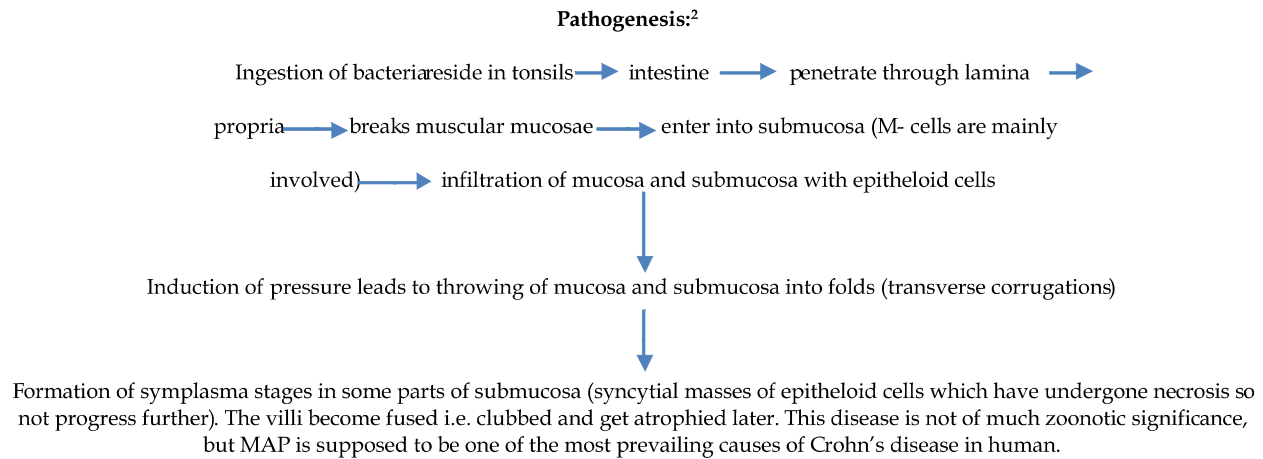
E-mail: ganguly38@gmail.com

Received on: 01.08.2024

Accepted on: 20.10.2024



Creative commons non-commercial CC BY-NC: This article is distributed under the terms of the creative commons attribution non-commercial 4.0 License (<http://www.creativecommons.org/licenses/by-nc/4.0/>) which permits non-commercial use, reproduction and distribution of the work without further permission provided the original work is attributed as specified on the Red Flower Publication and Open Access pages (<https://rfppl.co.in>)

*Pathogenesis:*²*Symptoms*³

- i. Diarrhea without blood and smell (pipe stem).
- ii. Emaciation with normal appetite, but body become staring and hide bound.

*Gross Lesions*⁴

- i. Thickening of ileal wall, 2-20 times more than normal.
- ii. Mucosa shows transverse brain like corrugations, not flattened on stretching (not seen in sheep and goats).
- iii. Earliest lesions are seen in ileocaecal valve.
- iv. Gelatinization of fat depots leads to emaciation.
- v. Intra-mandibular edema.
- vi. Swollen and juicy mesenteric lymph nodes.

*Microscopic Lesions*⁵

- i. In bovines no caseation, calcification and tubercle formation has been reported, while in sheep caseation and in 25% of the goats calcification is evident.
- ii. Infiltration of epitheloid cells, plasma cells, lymphocytes, eosinophils, symplasma stages and few langhans giant cells in intestinal mucosa and submucosa has been detected.
- iii. There is disappearance of villi and intestinal glands.
- iv. Mesenteric lymph nodes also show the presence of epitheloid cells, symplasma stages and giant cells.

- v. In later stages arteriosclerosis in intestinal blood vessels can be seen.
- vi. Lymphangitis of intestinal lymphatics can lead to knotty appearance.

*Diagnosis*⁶

The diagnosis of this infection can be made by demonstration of this organism in faeces by microscopy (acid fast staining of rectal pinch, bowel wash), faecal culture, LAT, intradermal johnin test, DNA probes, LAM-ELISA (lipoarabinomannan antigen-enzyme linked immunosorbent assay) and polymerase chain reaction. At necropsy, the pathognomonic lesions in intestine are quite informative to assess the disease condition. A major advantage of faecal culture test is that it can identify cattle 1-3 years prior to the appearance of clinical signs. So, it is a 100% specific and 100% sensitive test. The Herrold's egg yolk medium with mycobactin often used in culture for the detection of this bacteria. But intradermal johnin test is cheaper and more rapid test than faecal culture.

Treatment of this disease is not often indicated, but certain antimicrobials like isoniazid, rifampin and amikacin can be used. The animals treated with these antimicrobials should not be used for meat and milk consumption up to the period they are treated.

Differential Diagnosis

In cattle, JD must be differentially diagnosed from chronic fascioliasis, enzootic bovine leucosis, mucosal disease, copper deficiency, left abomasal

displacement, lipomatosis, salmonellosis, coccidiosis, yersiniosis and intestinal tumors. However this disease is mostly confused with tuberculosis (TB). But the diffuse nature of lesions, their confinement to intestinal mucosa and mesenteric lymph nodes and presence of innumerable acid fast bacilli helps to differentiate JD from TB.

Summary

JD leads to production losses in asymptomatic infected animals and there is no effective treatment for this disease. In recent years this organism has been identified in non-ruminant species also, including mammals and birds.

This bacterium is supposed to cause Crohn's disease in human beings, so also implicated as zoonotic infection. Due to the lack of effective vaccination and treatment, only the preventive control measures can decrease the prevalence of this infection.

References

1. Aduriz, J.J., Juste, R.A. and Cortabarría, N. Lack of mycobactin dependence of mycobacteria isolated on Middlebrook 7H11 from clinical cases of ovine paratuberculosis. *Vet. Microbiol.*, 1995; 45(2-3):21.
2. Aduriz A, Juste RA, Saez de Ocariz C. An epidemiologic study of sheep paratuberculosis in the Basque Country of Spain: serology and productive data. In: *Proceeding of the Fourth International Colloquium on Paratuberculosis*, Cambridge, 1994,p.19.
3. Brooks, BW, Robertson, RH, Corner, AH, et al. Evaluation of the serological response of sheep in one flock to *Mycobacterium paratuberculosis* by crossed immunoelectrophoresis. *Can. J. Vet. Res.*, 1988; 52(2):199.
4. Burnside, DM, Rowley, BO: Evaluation of an enzyme-linked immunosorbent assay for diagnosis of paratuberculosis in goats. *Am. J. Vet. Res.*, 1994; 55(4):465.
5. Carrigan, MJ, Seaman, JT: The pathology of Johne's disease in sheep. *Aust. Vet. J.*, 1990; 67(2):47.
6. Chakrabarti, A. *A Text book of preventive veterinary medicine*. Kalyani Publishers. 5th edition. 2012.