

# Dead Lifts and Death: Sudden Death due to Hypertrophic Cardiomyopathy in a Body Builder

Riya Gupta<sup>1</sup>, Haneil Larson Dsouza<sup>2</sup>, Sharada Rai<sup>3</sup>, Pavanchand Shetty<sup>4</sup>, Prateek Rastogi<sup>5</sup>, Jagadish Rao PP<sup>6</sup>

## How to cite this article:

Riya Gupta, Haneil Larson Dsouza, Sharada Rai, et al./Dead Lifts and Death: Sudden Death due to Hypertrophic Cardiomyopathy in a Body Builder. Indian J Forensic Med Pathol.2023;16(3):209-212.

## ABSTRACT

**BACKGROUND:** It is a well established fact that cardiac health and exercise go hand in hand. However, rigorous exercising regimens without proper cardiovascular screening can lead to catastrophic death in unsuspecting and otherwise healthy individuals. Among the underlying undetected cardiovascular conditions that need to be accounted for, especially in young adults, are hypertrophic cardiomyopathies.

**CASE DETAILS:** The deceased, a 33-year-old state level bodybuilder, was participating in a body building competition when he suddenly complained of dizziness and collapsed. The deceased appeared to have no significant findings on external examination. Internal examination, however, revealed that the heart was enlarged and weighed 698 g. On microscopic examination, ventricle sections showed enlarged myocytes with disarray and enlarged nuclei. The cause of death was ascertained to be due to complications of hypertrophic cardiomyopathy.

**IMPLICATIONS FOR CLINICAL PRACTICE:** Among the feasible options available in low and middle income countries, electrocardiography is an inexpensive method as a screening test, leading the way for using tools such as CMR, serum biomarkers and genetic testing if required.

**CONCLUSION:** Understanding the relationship between physical exertion and its effect on a hypertrophic heart is essential. The case presented brings to light the need for in-depth pre-competition screening of athletes. This is especially true since athletes are the one category of individuals where good health is taken for granted.

**KEYWORDS:** Hypertrophic cardiomyopathy; Bodybuilder; Sudden cardiac death.

**Author's Credentials:** <sup>1</sup>Medical Graduate, Department of Forensic Medicine, <sup>2,4,6</sup>Associate Professor, Department of Forensic Medicine and Toxicology, <sup>3</sup>Professor and HOD, Department of Pathology, <sup>5</sup>Professor and HOD, Department of Forensic Medicine and Toxicology, Kasturba Medical College, Manipal Academy of Higher Education, Manipal 576104, Karnataka, India.

**Corresponding Author: Haneil Larson Dsouza**, Associate Professor, Department of Forensic Medicine and Toxicology, Kasturba Medical College Mangalore, Manipal Academy of Higher Education, Manipal 576104, Karnataka, India.

**Email:** hanihere@gmail.com

**Received on:** 04-07-2023

**Accepted on:** 03-08-2023

## INTRODUCTION

It is a well established fact that cardiac health and exercise go hand in hand. A sedentary lifestyle is a major contributing factor to declining cardiovascular health, amongst other risk factors. This inactivity leads to the development and progression of cardiovascular disease. More importantly, regular exercise reduces blood pressure, increases insulin sensitivity, and produces a more favourable plasma

lipoprotein profile.<sup>1</sup> Physically active individuals may have a modest increase in life expectancy and a decreased risk of all cause mortality, which is effectively linked to decreased susceptibility to developing cardiovascular and respiratory diseases.<sup>2</sup> However, rigorous exercising regimens without proper cardiovascular screening can lead to catastrophic death in unsuspecting and otherwise healthy individuals.

Among the underlying undetected cardiovascular conditions that need to be accounted for, especially in young adults, are hypertrophic cardiomyopathies. According to the cohort study Cardia (Coronary Artery Risk Development in Young Adults) conducted using standard echocardiography, hypertrophic cardiomyopathy was prevalent in every 1 in 500 persons.<sup>3</sup> However, a recent U.S. study claims the prevalence is about 1:30,000 (0.03%).<sup>4</sup> Previously, the autosomal dominant transmission of HCM was not accounted for, bringing the prevalence to 1:200 (0.5%) or even greater.<sup>5</sup>

Here is a prime example of an unfortunate sportsman with an unknown underlying cardiomyopathy who succumbed to his disease.

#### CASE DESCRIPTION

The deceased, a 33-year-old state level bodybuilder, was participating in a bodybuilding competition when he suddenly complained of dizziness and collapsed. The practice of dehydrating oneself to “make weight” could not be established in this case.

He could not be resuscitated and was therefore shifted to a tertiary care hospital. Despite the quick transfer, the doctors declared the person “brought dead”. Given the sudden unnatural nature of the death, a police inquest was conducted, and the body was sent for autopsy.

On autopsy, externally, no specific findings were present. Internal examination, however, revealed that the heart was enlarged and weighed 698g (Fig. 1) with a circumference of 36 cm. The left ventricular wall was hypertrophied, and the thickness was 3 cm. The right ventricular wall was 2.8 cm thick and was also hypertrophied. The apex was rounded, with the mitral valve measuring 12 cm and the tricuspid valve measuring 9 cm.

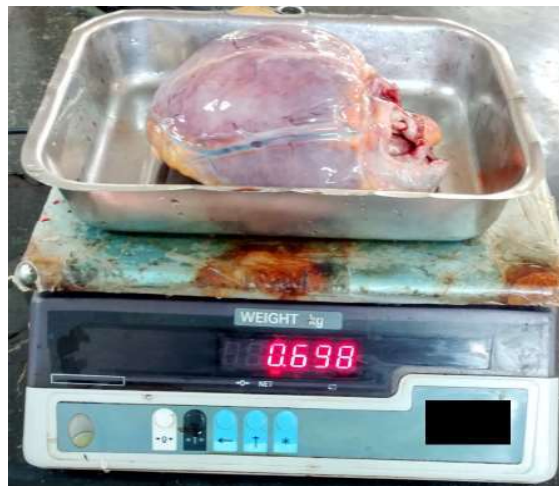

Fig. 1: Enlarged heart weighing 698 g.

On microscopic examination, ventricle sections showed enlarged myocytes with disarray and enlarged nuclei (Fig. 2 and 3). These findings are consistent with hypertrophic cardiomyopathy, and the cause of death was opined as “death due to complications of hypertrophic cardiomyopathy”.

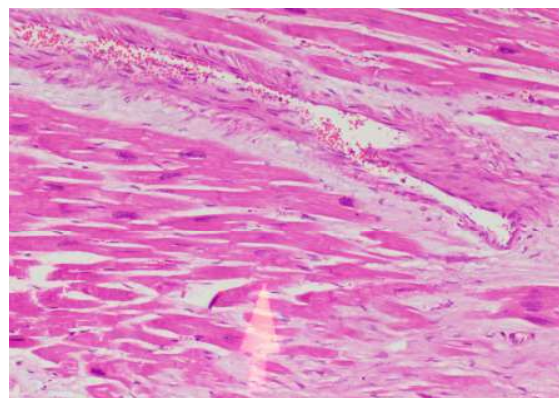


Fig. 2: Myocardium with fibrosis.

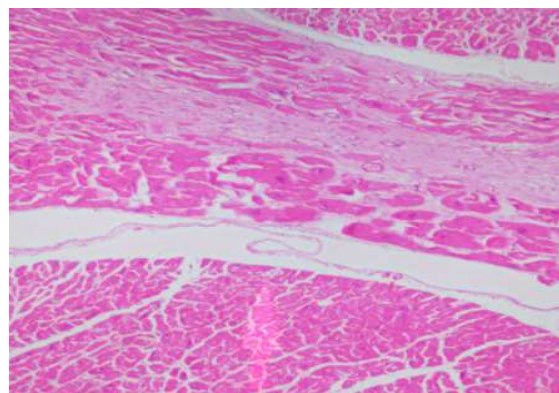


Fig. 3: Myocardial fibres with disarray.

---

**DISCUSSION**

---

Hypertrophic cardiomyopathy (HCM) is a common genetic disorder characterized by abnormal diastolic filling caused due to a poorly compliant left ventricular myocardium and myocardial hypertrophy.<sup>6</sup> There are several variants of HCM, including Mid cavity obstructive HCM, Mid cavity obstruction with LV apical aneurysm, Apical HCM, right ventricular obstruction, obstructive HCM in older adults, and end stage HCM.

In HCM, the left ventricular outflow tract obstruction is due to the mitral valve's systolic anterior movement or systolic anterior motion (SAM) make contact with the ventricular septum in phase of mid-systole. The mechanical resistance created by this exit of the blood from the heart causes a pressure differential between the left ventricle cavity and the aorta. In addition, during stress, there is diminished myocardial blood flow (i.e., "small vessel ischemia") consequent to an impairment in the vasodilatory capacity and diminished luminal cross-sectional area caused by structurally abnormal intramural coronary arterioles.

The histopathological findings in HCM include varying amounts of interstitial fibrosis intertwined among the myocytes, with hypertrophied myocytes arranged in a disorganized and chaotic fashion. Replacement fibrosis is also seen following myocyte cell death because of multiple small vessel ischemia and healing and repair mechanism.

Understanding the relationship between physical exertion and its effect on a hypertrophic heart is essential. The overall risk of acute coronary syndrome and atherosclerosis is reduced because of the positive pleiotropic effect from high intensity to moderate exercise, performed at repeated intervals.<sup>7</sup> This, however, is when the underlying heart is normal.

For an enlarged ventricle, during exercise, the catecholamine surge seen, interacts unfavourably with the core arrhythmogenic substrate, i.e., the enlarged ventricle itself in this case. Intense exercise can cause electrolyte imbalance, dehydration, hyperpyrexia, and increased platelet aggregation, further enabling ventricular fibrillation or tachycardia.<sup>8</sup>

The question now arises as to how to prevent such deaths. In one study, there was a drastic decline in the incidence of sudden cardiac death from 3.6/hundred thousand person years to 0.4/hundred thousand person years, representative of a ninety

percent reduction in sports related mortality with the use of ECG for pre-participation screening in a study conducted in Italy.<sup>9</sup> This simple, non-invasive procedure of an ECG, hence, has tremendous value in this context. In HCM, the ECG will show a large, inverted T wave.

Hence, a pre-participation assessment has proven beneficial when performed in competitive young athletes. The assessment consists of structured history taking and physical evaluation, and where required, an echocardiogram and electrocardiogram to identify the population at danger. Following this, supervised exercise training should be recommended, and lastly, resuscitative means should be readily accessible and available and applied in the rare event of an untoward cardiac incident.<sup>7</sup>

In athletes diagnosed with HCM, sports with surge action (sprinting and sports associated with it, such as basketball, football, hockey and other sports activities) are best avoided. Aerobic (not isometric) physical exertion is favoured. Physical activities should be performed in ideal or near-ideal environmental conditions. Replenishing fluids becomes very important in patients with HCM. In leisure sports activities (recreational activities), professional recommendations should be evaluated individually. These recommendations should consider the person's risk factors, particularly those predisposing to left ventricular outflow tract obstruction and ventricular arrhythmias. It is also essential to explain that even patients with hypertropia cardiomyopathy without all "classical" risk factors are not afforded safety from the risk of sudden cardiac death.<sup>9</sup>

---

**CONCLUSION AND IMPLICATIONS FOR CLINICAL PRACTICE**

---

The case presented brings to light the need for in-depth pre-competition screening of athletes. Non-invasive methods which do not use radiation can be used at the national level, such as Cardiac Magnetic Resonance (CMR) which provides an excellent view of the myocardium, but this test is expensive. However, the addition of electrocardiography is an inexpensive method as a screening test, leading the way for using tools such as CMR, serum biomarkers and genetic testing.<sup>4</sup> It is recommended that people with HCM should be excluded from all sports except low-intensity ones. Also, genetic counselling should be given to families of those with HCM and the deceased when autopsy findings reveal the cause of death as HCM.

## REFERENCES

1. **Nystoriak MA, Bhatnagar A.** Cardiovascular effects and benefits of exercise. *Frontiers in cardiovascular medicine*. 2018 Sep 28;5:135.
2. **Paffenbarger Jr RS, Hyde R, Wing AL, Hsieh CC.** Physical activity, all-cause mortality, and longevity of college alumni. *New England journal of medicine*. 1986 Mar 6;314(10):605-13.
3. **Maron BJ, Gardin JM, Flack JM, Gidding SS, Kurosaki TT, Bild DE.** Prevalence of hypertrophic cardiomyopathy in a general population of young adults: echocardiographic analysis of 4111 subjects in the CARDIA study. *Circulation*. 1995 Aug 15;92(4):785-9.
4. **Maron MS, Hellawell JL, Lucove JC, Farzaneh-Far R, Olivetto I.** Occurrence of clinically diagnosed hypertrophic cardiomyopathy in the United States. *The American journal of cardiology*. 2016 May 15;117(10):1651-4.
5. **Semsarian C, Ingles J, Maron MS, Maron BJ.** New perspectives on the prevalence of hypertrophic cardiomyopathy. *Journal of the American College of Cardiology*. 2015 Mar 31;65(12):1249-54.
6. **Kumar V, Abbas A, Aster J.** *Robbins & Cotran Pathologic Basis of Disease: South Asian Edition*. 1st ed. Vol. 1. Elsevier India; 1st edition (14 August 2014); 2014. 568-569 p.
7. **Vora A, Burkule N, Contractor A, Bhargava K.** Prevention of sudden cardiac death in athletes, sportspersons and marathoners in India. *Indian heart journal*. 2018 Jan 1;70(1):137-45.
8. **Chandra N, Bastiaenen R, Papadakis M, Sharma S.** Sudden cardiac death in young athletes: practical challenges and diagnostic dilemmas. *Journal of the American college of cardiology*. 2013 Mar 12;61(10):1027-40.
9. **Corrado D, Schimied C, Basso C, Borjesson M, Schiavon M, Pelliccia A, Vanhees L, Thiene G.** Risk of sports: do we need a pre-participation screening for competitive and leisure athletes?. *European heart journal*. 2011 Apr 2;32(8):934-44.

