

# Hybrid Lesion: Extrapulmonary Sequestration with Cystic Adenomatoid Malformation: A Rare Case Report

Sapna Patel<sup>1</sup>, Pallavi BR<sup>2</sup>, Sheela Devi CS<sup>3</sup>, Devi Sreelakshmi<sup>4</sup>

## How to cite this article:

Sapna Patel, Pallavi BR, Sheela Devi CS, *et al.* Hybrid Lesion: Extrapulmonary Sequestration with Cystic Adenomatoid Malformation: A Rare Case Report. Indian J Forensic Med Pathol.2024;17(3):207-210.

## Abstract

**Background:** 10-25% of bronchopulmonary sequestration comprises extralobar sequestration (ELS). ELS are usually found between the left lower lobe and diaphragm and rarely infra-diaphragmatically.

**Case Description:** 25 years old young female with 24 weeks of gestation was diagnosed with left supra adrenal mass in fetal anomaly scan. On fetal autopsy, the supra adrenal mass showed lung parenchyma with multiple cystic spaces which are lined by columnar to cuboidal cells. Bronchi and bronchioles were dilated. Skeletal muscle and cartilage were absent. Both grossly and microscopically, lungs and other organs were normal. Diagnosed as extralobar intraabdominal bronchopulmonary sequestration with cystic adenomatoid malformation suggestive of hybrid lesion. Hybrid lesion is a combination of bronchopulmonary sequestration (BPS) and congenital cystic adenomatoid malformation (CCAM).

**Clinical Relevance:** Diagnosis of hybrid lesion during pregnancy is important for prenatal counselling, fetal intervention and birth planning.

**Keywords:** Bronchopulmonary sequestration; Hybrid lesion; Supra adrenal mass; Fetus.

## INTRODUCTION

Bronchopulmonary sequestration (BPS) is a congenital abnormality of the lungs. It is an abnormal lung tissue which is non-functioning and not communicating with the tracheobronchial tree. It has aberrant vascular supply from systemic circulation and venous drainage varies. Of congenital pulmonary malformations, BPS represents 0.15-6.4%.<sup>1</sup> Based on the relationship of the aberrant lung parenchyma to the pleura, BPS is divided into intralobar sequestration (ILS) and extralobar

**Author's Credentials:** <sup>1</sup>Associate Professor, <sup>2</sup>Senior Resident, <sup>3</sup>Professor and Head of Department, <sup>4</sup>Post graduate, Department of Pathology, JSS Academy of Higher Education and Research, Mysuru 570 015, Karnataka, India.

**Corresponding Author:** Pallavi BR, Senior Resident, Department of Pathology, JSS Academy of Higher Education and Research, Mysuru 570 015, Karnataka, India.

**Email:** [pallubr@gmail.com](mailto:pallubr@gmail.com)

**Received on:** 02-07-2024

**Accepted on:** 20-08-2024

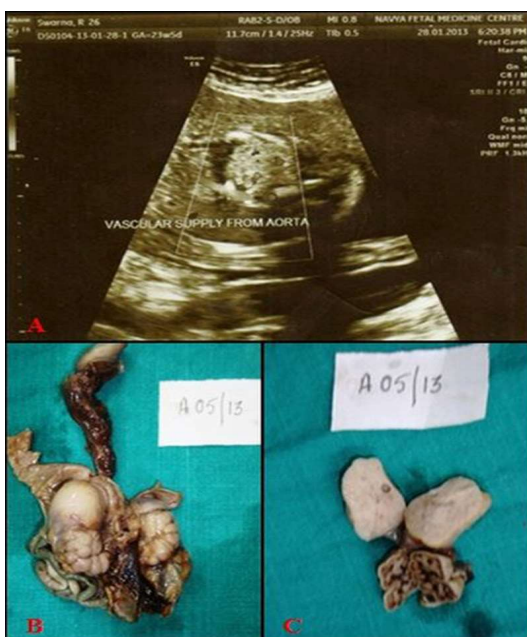

sequestration (ELS). ELS has its own visceral pleura.<sup>2</sup> The terminology hybrid lesion has been used to describe BPS in association with cystic pulmonary adenomatoid malformation (CPAM) and was introduced by DL Cass *et al.*<sup>3</sup>

We report a case of ELS coexistent with CPAM which had systemic blood supply from aorta in a fetus of 24 weeks of gestation.

## CASE REPORT

A 25 years old young female, gravida 2, para 1, living 1 with 24 weeks of gestation was detected with a left supra adrenal mass in fetal anomaly scan with vascular



**Fig. 1-A** -Left supra adrenal mass in fetal anomaly scan with vascular supply from aorta

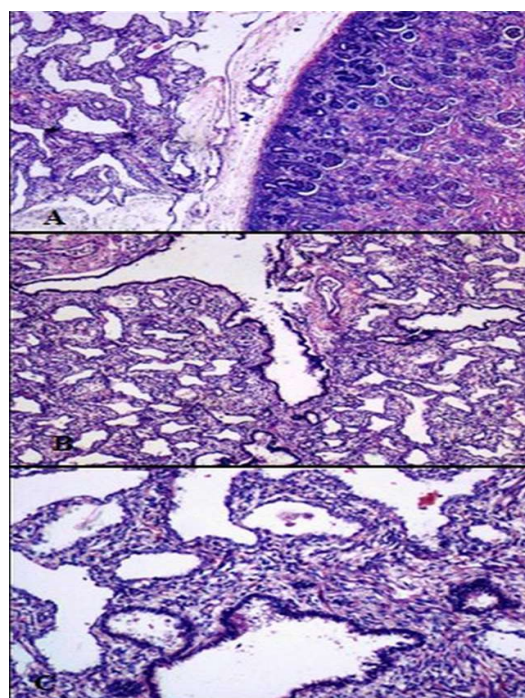
1-B, 1-C - Gross specimen showing homogenous mass, lobulated and cut surface of which shows multiple cysts

Congenital pulmonary abnormalities are seen in 1 in 10,000-35,000 live births.<sup>4</sup> It includes CPAM, bronchogenic cysts, bronchopulmonary sequestration and hybrid lesions. BPS includes 75-90% of ILS and ELS constitutes 10-25%. Abnormal connection to the gastrointestinal tract was seen in around 10% of cases.<sup>5</sup>

ELS are usually found between the left lower lobe and diaphragm<sup>6</sup> and rarely infra-diaphragmatically with male preponderance. ELS can occur in multiple sites.<sup>7</sup> Other reported uncommon sites being suprarenal, intra-diaphragmatic, intrapericardial and mediastinal. Intraabdominal sequestration is most often found in females (75%), presenting as a left retroperitoneal mass.

supply from aorta (Fig. 1-A). On fetal autopsy, the supra adrenal mass was noted. Grossly, mass was homogenous, lobulated measuring 4x3x2.5cms, cut surface of which showed multiple cysts measuring 3x2mm (Fig. 1-B and 1-C). Microscopically, cystic spaces which were lined by columnar to cuboidal cells. Bronchi and bronchioles were dilated (Fig. 2-A, 2-B, 2-C). Skeletal muscle and cartilage were absent. Both grossly and microscopically, lungs and other organs were normal. Diagnosed as hybrid lesion of extra lobar intraabdominal BPS with congenital cystic adenomatoid malformation.

## DISCUSSION



**Fig. 2:** Microscopy showed lung parenchyma with multiple cystic spaces lined by cuboidal to columnar cells. Bronchi and bronchioles were dilated

Our case was 24week old fetus with extra lobar sequestration in suprarenal region.

EPS is seen in association with diaphragmatic hernia, vertebral anomalies, broncho-pulmonary malformations, foregut duplication. Our case was a hybrid lesion as ELS was associated with CPAM.

The blood supply for BPS is from the systemic circulation, commonly from the thoracic or abdominal aorta. Venous drainage was seen into pulmonary veins, azygous vein, hemiazygos vein and in few cases directly into the right atrium or inferior venacava.<sup>8</sup> Though the gold standard to evaluate the blood supply in BPS is arteriography, in our case abdominal aorta was supplying

the sequestered lung. Embolization is one of the treatment options described. High rate of recurrences have been noted. Surgical resection is also described for ELS.<sup>9</sup>

### ***Prenatal diagnosis and management options of CPAM***

David M *et al.*, has discussed in detail about prenatal and postnatal management of CPAM.<sup>10</sup> Routine ultrasound (US) screening prenatally helps to detect CPAM. Farrugia MK *et al.*, showed the findings of resected specimen in suspected cases of CPAM was concordance in 61.5% of prenatal ultrasound and 65.4% with post-natal computed tomography.<sup>11</sup> The use of prenatal diagnosis of CPAM is to identify symptomatic neonates after birth. Antenatally, though magnetic resonance imaging (MRI) helps in volumetric and morphological evaluation of the foetal lung, US remains the investigation of choice for screening of CPAM.

MRI should be considered when US findings are doubtful. Since CPAM derive its blood supply from the pulmonary circulation and drains into pulmonary veins whereas BPS receive its blood

supply from systemic artery, color doppler US helps to differentiate between CPAM and BPS. Hydrops is one of the indication for prenatal intervention as it has a good prognosis.

Treatment options described are use of systemic steroids to mother, surgical procedures like open foetal surgery or decompression procedures. In macrocystic lesions, decompression is preferred either by US guided single needle thoracocentesis or thoracoamniotic shunt.<sup>13</sup> Open foetal surgery is indicated in microcystic lesions.<sup>14</sup> Systemic betamethasone has shown better effects in large microcystic CPAM.<sup>15-17</sup> Higby et al found systemic steroids given for lung maturation had resolution of a large CPAM.<sup>18</sup>

---

### CONCLUSION

---

Diagnosis of hybrid lesion during pregnancy is important for counselling, medical or surgical management and birth planning.

***Conflict of Interest:*** Authors declare no conflict of interest regarding the publication of this paper.

---

### REFERENCES

---

1. **Savic B, Birtel FJ, Tholen W, Funke HD, Knoche R.** Lung sequestration: report of 7 cases and review of 540 published cases. *Thorax* 1979; 34:96-101.
2. **Pryce DM.** Lower accessory pulmonary artery with intralobar sequestration of lung: a report of 7 cases. *J Pathol Bacteriol* 1946; 58:457-67.
3. **D.L. Cass, T.M. Crombleholme, L.J. Howell, P.W. Stafford, E.D. Ruchelli, N. S. Adzick,** Cystic lung lesions with systemic arterial blood supply: a hybrid of congenital cystic adenomatoid malformation and bronchopulmonary sequestration, *J. Pediatr. Surg* 1997; 32: 986-90.
4. **Durell J, Thakkar H, Gould S, Fowler D, Lakhoo K.** Pathology of asymptomatic, prenatally diagnosed cystic lung malformations. *J PediatrSurg* 2016; 51(2):231-5.
5. **Correia-Pinto J, Gonzaga S, Huang Y, Rottier R.** Congenital lung lesions underlying molecular mechanisms. *Semin Pediatr Surg* 2010; 19(3):171-9.
6. **Yang L, Yang G.** Extralobar pulmonary sequestration with a complication of torsion: a case report and literature review. *Medicine (Baltimore)* 2020; 99(29):e21104.
7. **Ryujin K, Akamine T, Miura N, et al.** An adult case of multiple extralobar pulmonary sequestrations in the thoracic and abdominal cavities. *Ann Thorac Surg* 2022; 113(1):e17-e20.
8. **Petty L, Joseph A, Sanchez J.** Case report: Pulmonary sequestration in an adult. *Radiol Case Rep* 2017; 13(1):21-3.
9. **Raemdonck D, Louw J, et al.** Treatment strategies for pulmonary sequestration in childhood: resection, embolization, observation? *Acta Cardiol* 2012; 67:629-34.
10. **David M, Lamas Pinheiro R, Henriques-Coelho T.** Prenatal and postnatal management of congenital pulmonary airway malformation. *Neonatology* 2016; 110:101-15.
11. **Farrugia MK, Raza SA, Gould S, Lakhoo K.** Congenital lung lesions: classification and concordance of radiological appearance and surgical pathology. *Pediatr Surg Int* 2008; 24: 987-91.
12. **Marshall KW, Blane CE, Teitelbaum DH, van Leeuwen K.** Congenital cystic adenomatoid malformation: impact of prenatal diagnosis and changing strategies in the treatment of the asymptomatic patient. *AJR Am J Roent- genol* 2000; 175:1551-4.
13. **Knox EM, Kilby MD, Martin WL, Khan KS.** In-utero pulmonary drainage in the management of primary hydrothorax and congenital cystic lung lesion: a systematic review. Ultra-

- sound *ObstetGynecol*2006; 28:726–34.
14. **Witlox RS, Lopriore E, Oepkes D.** Prenatal interventions for fetal lung lesions. *PrenatDiagn.* 2011; 31(7):628-36.
15. **Loh KC, Jelin E, Hirose S, Feldstein V, Goldstein R, Lee H.** Microcystic congenital pulmonary airway malformation with hydrops fetalis: steroids vs open fetal resection. *J Pediatr Surg* 2012; 47:36–39.
16. **Tsao K, Hawgood S, Vu L, Hirose S, Sydorak R, Albanese CT, et al.** Resolution of hydrops fetalis in congenital cystic adenomatoid malformation after prenatal steroid therapy. *J PediatrSurg*2003; 38:508–10.
17. **Curran PF, Jelin EB, Rand L, Hirose S, Feldstein VA, Goldstein RB, et al.** Prenatal steroids for microcystic congenital cystic adenomatoid malformations. *J PediatrSurg* 2010; 45:145–50.
18. **Higby K, Melendez BA, Heiman HS.** Spontaneous resolution of nonimmune hydrops in a fetus with a cystic adenomatoid malformation. *J Perinatol*1998; 18:308–10.
-