

## Role of Stencil in Wound Assessment

P Barath Kumar Singh<sup>1</sup>, Ravi Kumar Chittoria<sup>2</sup>

### How to cite this article:

P Barath Kumar Singh, Ravi Kumar Chittoria/Role of Stencil in Wound Assessment/Indian J Biol 2022; 9(1):14-16.

**Author's Affiliation:** <sup>1</sup>Senior Resident, <sup>2</sup>Professor & Registrar (Academic), Department of Plastic Surgery, Jawaharlal Institute of Postgraduate Medical Education and Research Institute, Puducherry 605006, India.

**Corresponding Author:** Ravi Kumar Chittoria, Professor & Registrar (Academic), Department of Plastic Surgery, Jawaharlal Institute of Postgraduate Medical Education and Research Institute, Puducherry 605006, India.

**E-mail:** drchittoria@yahoo.com

**Received date:** 02.03.2022

**Accepted date:** 09.05.2022

### Abstract

Wound assessment is the basis of the wound management process in the plastic surgery. The assessment of wound is done by clinical examination, measurement done with scale, video dermoscopy and radiological examination for the assessing the size and depth of the wounds. In this article we will assess the usefulness of the Stencil in the wound measurement.

**Keywords:** Stencil, Wounds, Assessment.

### Introduction

The measurement of the size of the wound helps in deciding the plan of treatment for the specific wounds. In wound cases ultimate goal to control the symptoms and prevent complications, rather than healing the wound. It is important to understand the pathological process of wound development in the patient for planning the treatment for the specific wounds. The detailed clinical examination should include history and duration of ulcer, associated comorbidities, examination of the ulcer along with the specific radiological investigations of the patient. There are various methods by

which wound can be measured like photographic record, comparison, ruler method, graph method, digital planimetry. In this article we will assess the usefulness of the stencil scale (figure 1) in measuring the area of the wounds.<sup>1</sup>

### Materials and Methods

The study was carried out in a tertiary care hospital in South India after receiving approval from departmental ethical committee. The subject was a 32-year-old male patient with a history of electrical burn 10years back following which he developed a non-healing ulcer on the back. After the initial




Fig. 1: Stencil for wound assessment

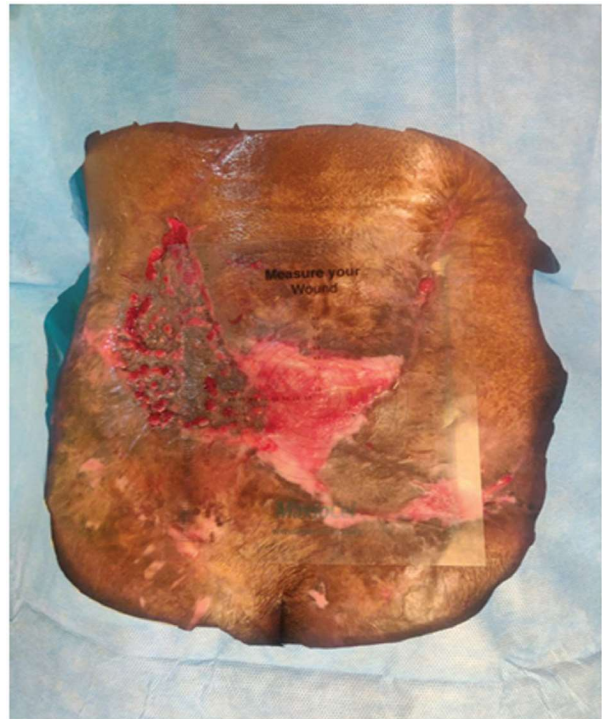

Fig. 2: Measurement of the wound with the stencil

routine investigation, the patient underwent a CT Dorsolumbar scan to rule out osteomyelitis. The ulcer on the back was excised and sent for histopathology to rule any malignant aetiology. After ruling out malignancy, patient underwent transposition flap for the raw area post excision. Post transposition distal part of the flap underwent necrosis for which debridement was done. The raw area post debridement was planned for further procedures for wound cover. The raw area was measured with the help of stencil (figure 2) with the markings in the X and Y axis and circular markings in the stencil will help in measuring the circumference of the irregular wound. The cost of the stencil is 200 Indian rupees easily available in all stationeries in Indian market.

## Results

Wound measurement is an important step in its management. Wound measurement gives an idea for deciding the current treatment efficacy and for changing the current treatment. There are various methods by which wound can be measured like photographic record, comparison, ruler method, graph method, digital planimetry.<sup>2</sup> The stencil scale used in our study is found to be useful in assessing the 2-Dimensional size of the wound as it is easy to measure the area of the wounds as it is transparent.

This method of wound measurement is very cost effective and it is reusable after sterilisation.

## Discussion

Wound measurement is an important part of management. Any change in wound area indirectly provides information about wound healing or response to current treatment. Continuation of ineffective treatment would prolong hospital stay and can be avoided by tracking the wound correctly. Therefore, objective technique of accurate measurement and documentation is needed for wound management. Traditionally wound measurement was done by photographic record<sup>3</sup>, comparison, ruler method, graph method. Clinical photography is being used by most of the plastic surgeon as a part of record keeping and tracking the progress of the disease wound. The methods of measurements of wounds include measuring the wound manually with inch tape, photographic methods which uses software for wound assessment.<sup>4,5</sup> The Stencil is relatively simple and easy method to measure the area of the wound.

## Conclusion

Wound measurement with the help of stencil provides easier assessment of wounds. This

method can be easily adaptable by other clinicians, cost effective than other methods. We need a study involving more patients to assess the validity of the study.

**Conflicts of interest:** None.

**Authors' contributions:** All authors made contributions to the article

**Availability of data and materials:** Not applicable.

**Financial support and sponsorship:** None.

**Consent for publication:** Not applicable

## References

1. Haghpanah S, Bogie K, Wang X et al. Reliability

of electronic versus manual measurement techniques. Arch Phys Med Rehabil. 2006; 87: 1396-402

2. Chitoria RK, Kumar P, Baljaj SP, Singh AK, Gupta DK. General clinical guidelines for wound management: redefining acronym SWCR. Journal of SWCR 2014;7(1): 2-7.
3. Shetty R, H.Sreekar, Lamba S et al. A novel and accurate technique of photographic wound measurement. Indian J Plast Surg. 2012 May- Aug; 45(2):425-429.
4. Haghpanah S, Sreekar, Lamba et al A novel and accurate technique of photographic wound measurement: Indian J Plast Surg. 2012May-Aug;45(2):425-429.
5. Majeske C. Reliability of wound surface area measurement. Phy Ther.1992;72:138-41

