

## A Rare Case of Hypercalcemia without any Underlying Disease

Saurabh Saini<sup>1</sup>, Abhishek Yadav<sup>2</sup>, Smriti Arora<sup>3</sup>, Kishalay Datta<sup>4</sup>

### How to cite this article:

Saurabh Saini, Abhishek Yadav, Smriti Arora *et al.* A Rare Case of Hypercalcemia without any Underlying Disease. Indian J Emerg Med. 2024;10(3):163-166.

### Abstract

Vitamin D supplements and calcium supplements are routinely supplements to infants and females in the Indian subcontinent. However, overdose of these medications can lead to life threatening hypercalcemia. We highlight the risk involved in self-medications of calcium supplements by the public, how various advertisements and publicity abet the consumption of these supplements without any proper medical supervision and how fatal the consumption of these “over the counter” supplements can cause.

**Keywords:** Hypercalcemia; Vitamin D; Calcium supplements; PTH.

### INTRODUCTION

Calcium supplements are being increasingly promoted by advertisements locally in the Indian subcontinent. Calcium, along with Vitamin D supplements, are easily available over the counter medications in the Indian subcontinent. There is non-conclusive evidence supporting the frequent administration of these supplements for achieving miraculous results.<sup>1</sup> In spite of less evidence for the actual outcome of these supplements, the promotion of these supplements are rampant through digital media and through prescriptions of doctors and nutritionists.<sup>1</sup> Wide scale promotion of calcium supplements, without thorough research, has led to various complications, toxicity of hypercalcemia which can sometimes be fatal.<sup>2</sup>

### CASE

A 58-year-old female was brought to the ED with complaints of spasms in her left hand with inability to open her fingers or grasp objects. As per her attendants, the patient had generalized weakness with lethargy for the last 6-8 months, but now, since the last 2 days, she is having “shock like” sensation in her body with sudden contractions in her hand. Her initial vitals were : pulse rate - 92/minute, blood pressure - 110/70 mmHg, respiratory rate - 16/minute, SpO<sub>2</sub> - 98 % on room air, random fingertip prick blood sugar - 187 mg/dL, GCS - E4V5M6 (15/15) with no focal neurological deficit. She was immediately diagnosed with a case of cerebrovascular accident. Immediate brain scan was done (magnetic resonance imaging) but there were no signs of cerebrovascular accident. The patient was now diagnosed to suffer from transient ischemic attack and the patient was admitted under the neurological team. Routine blood investigations were done with complete blood count, liver and kidney functions tests, serum electrolytes, serum calcium and magnesium levels, vitamin folate and B12.

The patient was found to have grossly elevated serum calcium levels, with all other blood investigations within normal range. Now, the diagnosis started revolving around hypercalcemia induced muscle weakness. The patient was

**Author's Affiliation:** <sup>1,2</sup>Resident, <sup>3</sup>Senior Resident, <sup>4</sup>HOD  
Department of Emergency Medicine, Max Super Speciality  
Hospital, Shalimar Bagh 110088, Delhi, India.

**Corresponding Author:** Abhishek Yadav, Resident,  
Department of Emergency Medicine, Max Super Speciality  
Hospital, Shalimar Bagh 110088, Delhi, India.

**E-mail:** [Abhiyadav2794@gmail.com](mailto:Abhiyadav2794@gmail.com)

**Received on:** 29-03-2024

**Accepted on:** 05-08-2024



This work is licensed under a Creative Commons  
Attribution-NonCommercial-ShareAlike 4.0.

transferred under the endocrinology team. Elevated serum calcium levels had raised many suspicious differentials like multiple myeloma, hyperparathyroidism. Relevant investigations were done (Fig. 1) as per medical literature to rule out differential like multiple myeloma, hyperparathyroidism. The chest x-ray was normal,

serum immunoglobulins were normal, bone marrow biopsy was normal to rule out multiple myeloma. There were no supporting diagnosis for hyperparathyroidism. Serum Vitamin D test was done which was found elevated and the diagnosis of Hypervitaminosis D.

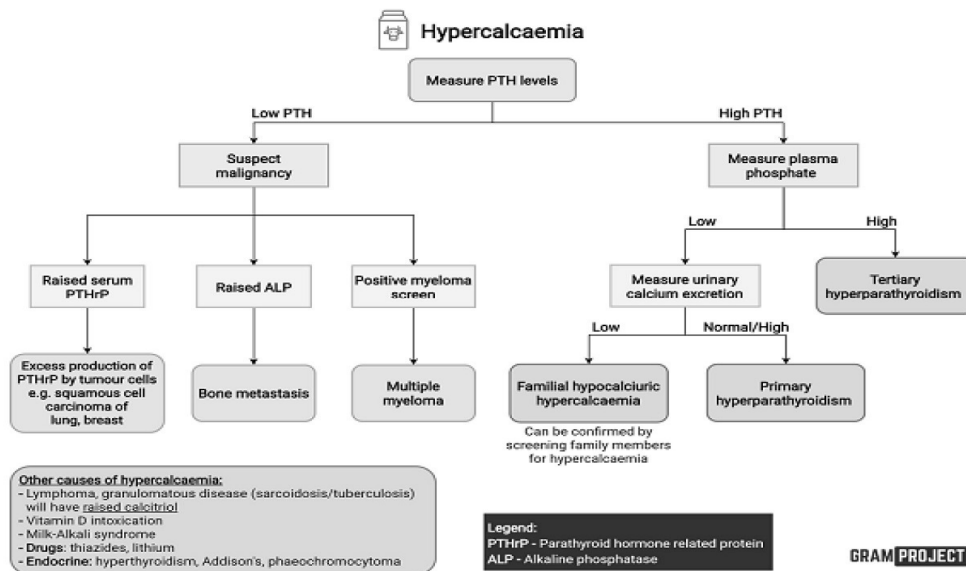


Fig. 1: (Source: Google Images, Gramproject and Medscape)

The patient and her attendants after deep enquiry for supplementation, had revealed the prescription by a neighboring pharmacist, who had given the medication of tablet Shelcal (calcium) and capsule D3 (vitamin D) over the last 4 months for

her general weakness. The patient was now started on aggressive hydration therapy, bisphosphonates and diuretics to reduce the load of serum calcium and vitamin D3, promoting the excretion of vitamin D3 and calcium.

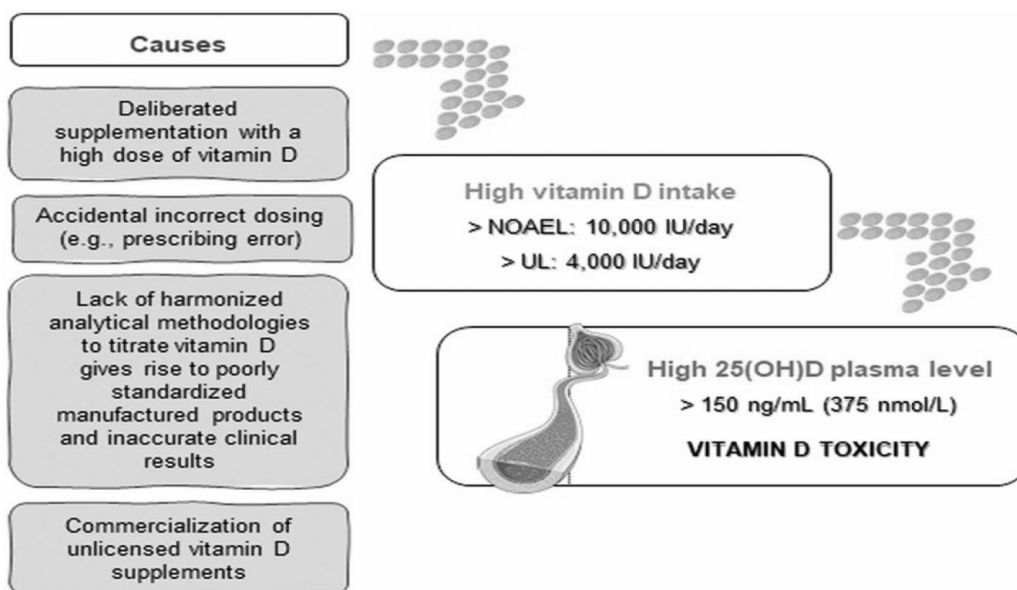


Fig. 2: (Source: Google Images and Medscape)

The patient's condition gradually improved and symptoms resolved after 10 days of intensive in-hospitalization therapy. The patient has discharged home in stable condition, warning about not to

take supplements without doctor consultation. The post discharge follow-up was satisfactory and the patient recovered well from the treatment by stopping all vitamin supplements.

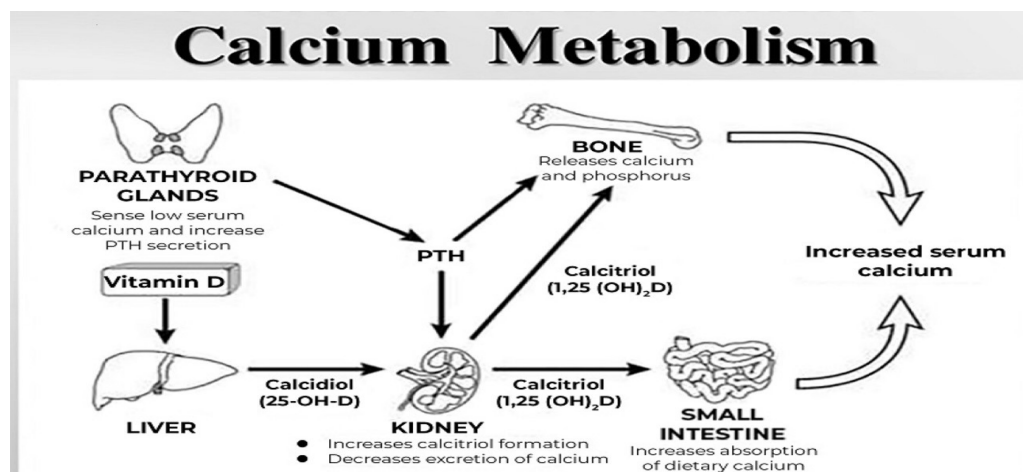


Fig. 3: (Source: Google Images, Harrison Principle of Internal Medicine)

## DISCUSSION

Our case report has highlighted a case of hypercalcemia with hypervitaminosis due to unsupervised unprescribed supplementation of calcium and vitamin D. The diagnosis was prolonged by the various non-specific symptoms of the patient. The symptoms were more relevant with other common etiologies like neoplasm. The lack of proper history by the patient and attendants led to delay in the proper treatment initiation in this patient. The lack of knowledge and facts regarding the over-the-counter usage of vitamins by the patients also played an important role in not disclosing this history to the medical team.

Vitamin D is a fat soluble vitamin, widely deposited in the adipose tissue. The half life of Vitamin D is 2 months, and thus, the symptoms of hypervitaminosis can last for many weeks.<sup>3</sup> Vitamin D plays a vital role in the metabolism of calcium (Fig. 2). The over usage of vitamin D supplements and calcium supplements can result in overdose of these elements in the body, leading to non-specific but fatal outcomes.

The various clinical manifestations of vitamin D intoxication are generally multisystemic and are largely derived from its resultant effects of hypercalcaemia. Neurological features include apathy, psychosis, depression, drowsiness, confusion, stupor, and coma. Cardiovascular effects can be hypertension, shortened QT interval,

ST-segment changes and bradyarrhythmias. Renal effects consist of dehydration, hypercalciuria, nephrocalcinosis and renal failure. GIT symptoms include abdominal pain, vomiting, constipation, anorexia, peptic ulcers and pancreatitis.<sup>4</sup>

Diagnosis of hypervitaminosis is through the estimation of levels of Vitamin D<sub>3</sub> and calcium in the blood. It is necessary to rule out other possible causes of hypercalcemia (Fig. 2) before setting up the diagnosis of hypervitaminosis induced hypercalcemia, provided there is no supportive evidence of exogenous vitamin supplementation in the patients.

The treatment modality is largely discontinuation of vitamin D and calcium supplementations, adequate hydration, establishing a low calcium-containing diet, steroid therapy and possible bisphosphonate therapy (agents that inhibit osteoclastic activities, thereby reducing serum calcium).<sup>5</sup> There is further requirement of educating the public and increasing awareness for consumption of these supplements only with proper guidance and with valid prescription of doctor or certified healthcare professional.

## CONCLUSION

The rampant consumption of vitamin and mineral supplements without any proper guidance by certified healthcare practitioners has various health hazards which may turn fatal at times. Excessive

advertisement of these products should be limited and public awareness should be improved for the consumption of these supplements. Not only vitamin D and calcium but also other such vitamins and supplements should be started by patients once it is advised by certified healthcare practitioners.

## REFERENCES

1. Guerra V, Neto OMV, Laurindo AF, Paula FJAD, Neto MM. Hypercalcemia and renal function impairment associated with vitamin D toxicity: case report. *Braz J Nephrol.* 2016;38(4):466-9.
2. Theodoratou E, Tzoulaki I, Zgaga L, Ioannidis JP. Vitamin D and multiple health outcomes: umbrella review of systematic reviews and meta-analyses of observational studies and randomized trials. *Bmj.* 2014;348:2035.
3. Ellis S, Tsiopanis G, Lad T. Risks of the 'Sunshine pill' - a case of hypervitaminosis D. *Clin Med* 2018;18:311-3. doi:10.7861/clinmedicine.18-4-311
4. Marcinowska-Suchowierska E, Kupisz-Urbańska M, Łukaszkiwicz J et al Vitamin D toxicity - a clinical perspective. *Front Endocrinol* 2018;9:550. doi:10.3389/fendo.2018.00550 pmid: <http://www.ncbi.nlm.nih.gov/pubmed/30294301>
5. Joshi R. Hypercalcemia due to hypervitaminosis D: report of seven patients. *J Trop Pediatr* 2009;55:396-8. doi:10.1093/tropej/fmp020 pmid: <http://www.ncbi.nlm.nih.gov/pubmed/19339514>