

REVIEW ARTICLE

# A Rare Case of Traumatic Neuroma of the Median Nerve

Libni D Angel<sup>1</sup>, J. Thanka<sup>2</sup>

## ABSTRACT

### INTRODUCTION

Traumatic neuromas are considered as pseudotumors caused due to reactive proliferation of the neural tissue. Due to trauma of the nerve, a process of degeneration at the distal end and regeneration at the proximal end occurs. Histopathological examination is essential for making a diagnosis of traumatic neuroma along with clinical and radiological correlation.

### Author's Credentials:

<sup>1</sup>Tutor, <sup>2</sup>Professor, Department of Pathology, Sree Balaji Medical College and Hospital, Chennai 600044, Tamil Nadu, India.

### Corresponding Author:

**J. Thanka**, Professor, Department of Pathology, Sree Balaji Medical College and Hospital, Chennai 600044, Tamil Nadu, India.

Email: [thanka7paul@gmail.com](mailto:thanka7paul@gmail.com)

Received on: 30.06.2022

Accepted on: 02.10.2022

KEYWORDS | NEUROMA; PSEUDOTUMOR; TRAUMA.



### How to cite this article:

Libni D Angel, J. Thanka/A Rare Case of Traumatic Neuroma of the Median Nerve. *Indian J Forensic Med Pathol.*2022;15(4):289-291.

## INTRODUCTION

Traumatic neuromas are Pseudotumors also known as amputating neuromas.<sup>1</sup> It can occur in any part of the body.<sup>2</sup> The main symptom of a traumatic neuroma is pain, especially severe neuralgia. It usually presents as a firm, round, slow growing, palpable and painful nodule. After digital amputation, 6% of people will develop a neuroma. Clinically it can mimic soft tissue tumors and diagnosis depends upon histopathological examinations that show a haphazard arrangement of nerve bundles. The present case report, is about a rare manifestation in a 26-year-old male with swelling and pain in the right index finger.

### *Clinical presentation clinical history and findings*

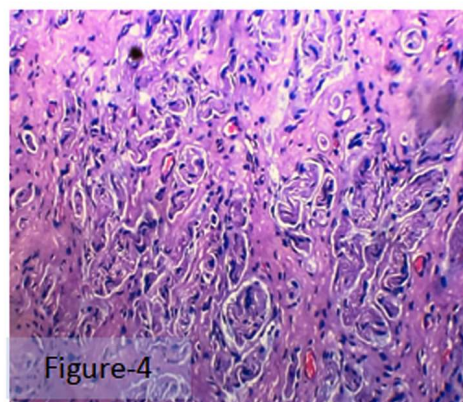
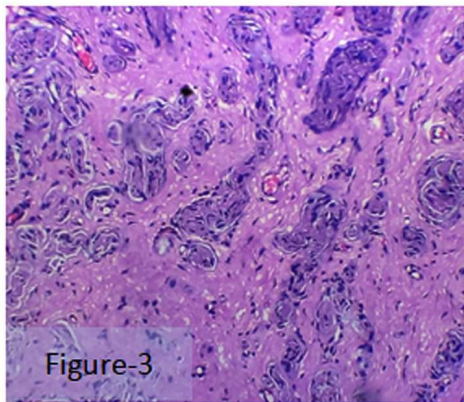
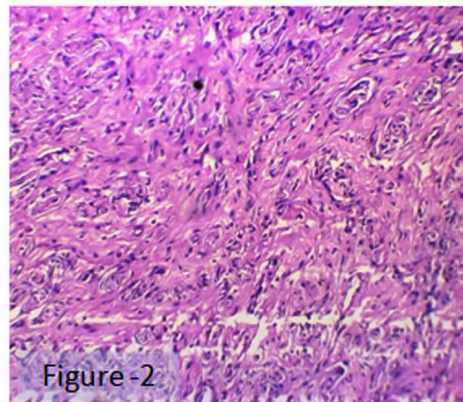
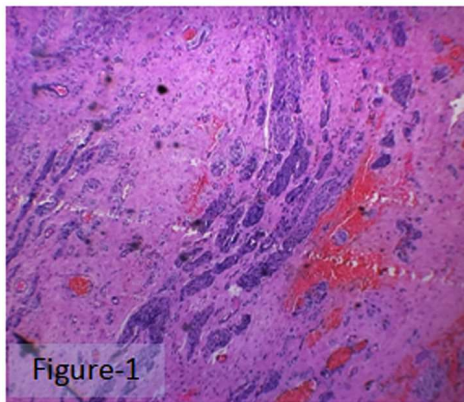
A 26 year old male came to our hospital with complaints of swelling and pain in the right index finger for 2 months. The swelling was initially small in size and gradually increased associated with pain. On external examination, a swelling measuring 2x1 cm which is firm in consistency and tender on palpation. The patient had a prior right wrist injury from an accident that occurred six months back.

### Investigation

MRI was done for the patient which showed a focal fusiform swelling measuring 27x9 mm of the median nerve with disorganized fascicles noted at the level of the distal radius. The swelling is proximal to the carpal tunnel and seen continuous with proximal and distal aspects of the median nerve.

### Histopathological Findings

Excision of soft tissue with neuroorrhaphy and tendon repair was done and sent for histopathological examination. Grossly received three grey black soft tissue bits largest measuring 1.5x1x0.5cm and the smallest measuring 1x0.7 cm. Microscopically, haphazard proliferation of the nerve fascicles enveloped in collagen was noted with areas of fibrosis, hemorrhage, and congested blood vessels.



**Fig. 1:** Microscopic features from soft tissue biopsy shows haphazard proliferation of nerve fascicles enveloped in collagen, H&E magnification 4x, **Fig. 2:** H & E magnification 10x, **Fig. 3 & 4** H&E magnification 40x.

### DISCUSSION

Traumatic neuromas are considered as pseudotumors caused due to reactive proliferation of the neural tissue. The history of trauma is needed for the diagnosis of traumatic neuroma. The pathology is due to damage of the axons leading to primary cause for the development of traumatic neuroma. The pattern of injury described

as Wallerian degeneration.<sup>3</sup> Within a day of injury, fragmentation of the distal axons occurs along with separation of the myelin sheaths and breakdown into spherical structures. The Macrophages get activated and participate in the removal of axonal and myelin debris. At the site of transection, the process of regeneration starts with the formation of a growth cone and new branches from the stump of the proximal axon. Following this process, the

Schwann cells control the sprouting axons. Continuous shearing of these sprouting axons removes the misguided branches. Around the regenerating axons, the Schwann cells form new myelin sheaths. A successful repair process is only when the transected ends are closely approximated. A failure of the outgrowing axons to find their distal target can produce a “pseudotumor” termed traumatic neuroma. With progression, the damage tends to out do the repair mechanism, resulting in progressive loss of axons.

For traumatic neuromas, the histopathological differential diagnosis comprises of Neurofibromas, mucosal neuromas, palisading neuromas, and neurovascular Hamartomas. The Neurofibromas can have fibrous connective tissue and non-capsulated lesion similar to that of the traumatic neuroma, the differentiating feature is abundant, and the haphazard arrangement of axons seen in traumatic neuroma but not in neurofibroma which has mast cells and nuclei with wavy in nature.<sup>4</sup> The mucosal neuromas have a very similar appearance to the increased nerve bundles. But there will be no inflammatory

cells in a fibrous connective tissue background as that of traumatic neuroma.<sup>5</sup> The palisading neuroma forms nerve bundles with spindle cells showing a palisading arrangement in a circumscribed margin, but there is an absence of fibrous connective tissue and inflammatory cells compared to traumatic neuroma.<sup>6</sup> Neurovascular hamartomas show poorly circumscribed masses that are tightly packed in a loose matrix and are free of inflammation.<sup>7</sup>

---

#### CONCLUSION

The diagnosis of Traumatic Neuroma is important for patient management. Proper history, clinical examination and finally histopathology is important to distinguish it from other soft tissue painful tumors.

Traumatic neuromas are rare. In this article, we highlight histopathology and differential diagnosis which is very important and useful for the proper treatment of the patient.

---

**Conflict of Interest:** Nil

**Source of Funding:** Nil

**Acknowledgement:** Nil

---

#### REFERENCES

- Eguchi T, Ishida R, Ara H, Hamada Y, Kanai I.** A diffuse traumatic neuroma in the palate: a case report. *Journal of medical case reports.* 2016 Dec;10(1):1-5.
- Yang JR, Wang CJ, Kao WB, Wang YL.** Traumatic neuroma of bilateral mental nerve: a case report with literature review. *2010 Sep 1;21(3):252-260.*
- Foltán R, Klíma K, Špačková J, Šedý J.** Mechanism of traumatic neuroma development. *Medical hypotheses.* 2008 Oct 1;71(4):572-576.
- Chander V, Rao RS, Sekhar G, Raja A, Sridevi M.** Recurrent diffuse neurofibroma of nose associated with neurofibromatosis Type 1: a rare case report with review of literature. *Indian journal of dermatology.* 2015 Nov;60(6):573.
- Lee MJ, Chung KH, Park JS, Chung H, Jang HC, Kim JW.** Multiple endocrine neoplasia type 2B: early diagnosis by multiple mucosal neuroma and its DNA analysis. *Annals of dermatology.* 2010 Nov;22(4):452.
- Koutlas IG, Scheithauer BW.** Palisaded encapsulated ('solitary circumscribed') neuroma of the oral cavity: A review of 55 cases. *Head Neck Pathol.* 2010;4:15-26.
- Allon I, Allon DM, Hirshberg A, Shlomi B, Lifschitz-Mercer B, Kaplan I.** Oral neurovascular hamartoma: a lesion searching for a name. *J Oral Pathol Med.* 2012;41:348-353.