

■ ORIGINAL ARTICLE

Determination of Gender Divergences of Maxillary Sinuses Measurements in Computed Tomographic Scans of Kerala Population

Vyshnav R¹, Tina Sharma², Priyakanksha Mishra³

ABSTRACT

INTRODUCTION

The challenging forensic procedure of corpse identification is required by law authorities and social norms. It is very crucial to compare the post-mortem and antemortem medical information in cases where the bodies are severely damaged and beyond recognition. However, conventional identification techniques might not have been effective, especially though there have been substantial post-mortem alterations. In unidentifiable skeletons, gender has long been determined from either the skull, pelvic or long bones with an epiphysis and a metaphysis. In the present study, attempt has been made to determine gender divergences from axial and coronal computed tomographic scan (CT) of maxillary sinus in Kerala population. A total of 40 individuals including 20 male and 20 female, visiting the Outpatient Department of the Koyilli Hospital, Kannur were included as the study subjects. The dimensions of right and left maxillary sinuses of 40 subjects from plain CT were measured using Radiant DICOM software. Statistical analysis was completed with independent student t-test and general descriptive analysis with SPSS software. Gender determination using height, length, width of the maxillary sinus on both sides showed statistically insignificant results but in case of left volume and left anterior posterior height of maxillary sinus the p-value was found to be significant at 95% of confidence level. So, the present study concludes that left volume of maxillary sinus and left anteroposterior height showed statistically significant results which can be considered in determining and screening corpses on the bases of maxillary sinus computed tomographic records.

KEYWORDS | FORENSIC SCIENCE; FORENSIC MEDICINE; GENDER DETERMINATION; FORENSIC ANTHROPOLOGY; POSTMORTEM IDENTIFICATION; MAXILLARY SINUS.

Author's Credentials:

¹M.Sc. Student, ²Assistant Professor, ³Research Scholar, Department of Forensic Science, Chandigarh University, Punjab 140413, India.

Corresponding Author:

Tina Sharma, Assistant Professor, Department of Forensic Science, Chandigarh University, Punjab 140413, India.

Email: shaematina1989@gmail.com

Received on: 20.07.2022

Accepted on: 28.10.2022



How to cite this article:

Vyshnav R, Tina Sharma, Priyakanksha Mishra/Determination of Gender divergences of Maxillary Sinuses measurements in Computed Tomographic Scans of Kerala Population. *Indian J Forensic Med Pathol.*2022;15(4):281-287.

INTRODUCTION

Post Mortem identification is one of the most important and necessary forensic procedure. Post mortem identification can be

done by comparing the antemortem records of certain body parts like skull, teeth, bones, maxillary sinus. However, skull, bone or teeth

may get badly tampered due to decomposition and are difficult to be used for identification.¹⁻³

In such cases Maxillary sinus plays a vital role in identification as they remain intact even if other parts are decomposed. Maxillary sinus is located in the maxillary bone and are the two air filled spaces which have considerable changes in size between both left and right maxillary sinus.³⁻⁵ Sinus develops rapidly and attain maximum growth by the age of 20. Previous studies indicate that 95 percent of the adults have the frontal sinuses and thus can be considered as a potential part of the skull for the classification.⁵⁻¹⁰

Radiography is one of the standard procedures in identification of individuals. Computer Tomography (CT) is widely used in forensic to identify unknown individuals mainly in cases of fragmented or decomposed body as they provide sequence of cross-sectional images of interior of the body. Studies indicates that Computer Tomography (CT) could be an excellent method for imaging and are used for analyzing maxillary sinus. The anthropometric measurements of maxillary sinus alone can even be used for gender determination if the other body parts are not found or are fragmented, burned or decomposed.¹¹ Even though some population shows changes in frequencies, it is estimated that more than 90 percentage of individuals have frontal sinus and even the sinus characteristics of twins are different. Therefore, sinus can be of a great potential part for gender determination.¹²

Identification of the characteristics of a corpse such as age, gender etc. are an essential procedure in forensic examination. However, the identification is very difficult in certain cases where the body might have completely mutilated or decomposed due to various reasons. In such cases of forensic examination anthropometric measurements plays a vital role in identification of an individual.¹⁴⁻¹⁶ Maxillary sinus is an important part which can be used for determination of gender by measuring and examining the morphometric measurements of the sinus, therefore sinus plays a major role in forensic examination as they can be used to confirm the gender of an individual even after death along with other methods such as

determining gender from pelvis, long bones or by examining dental documents. Here, in this paper, the attempt has been made to determine the gender divergences from the maxillary sinus measurements of CT samples of human skulls by calculating the Medio lateral (ML) and Anterior posterior (AP) measurements of the maxillary sinus. Here, in this paper, the attempt has been made to determine the gender divergences from the maxillary sinus measurements of CT samples of human skulls by calculating the Medioblateral (ML) and Anterior posterior (AP) measurements of the maxillary sinus. So, in the present study, attempt has been made to determine gender from 40 samples of CT scans with Coronal and Axial view.

MATERIALS AND METHODS

The study was conducted in 38 samples which includes 19 Males and 19 female participants. The samples were collected from the population of Kerala, India. CT scan samples of maxillary sinus from coronal, axial as well as sagittal plane was collected from the Hospital and were examined in Radiant DICOM viewer software. Using the software ML and AP measurements of both left and right maxillary sinus of coronal view were taken and AP of both left and right axial view were taken and recorded and documented. The measurements were taken from the first to last particular points in the sinus while keeping the maxillary sinus in the possible widest position. The measurements taken proceeded to statistical analysis in order to determine the gender with help of independent student t-test using SPSS (Statistical package for the social science) software.

The null hypothesis (H_0) and alternative hypothesis (H_1) of the Independent Samples t Test is as follows:

H_0 : There is no significant differences in Sizes of ML (Medio Lateral), AP (Anterior Posterior), APH and Volume of Maxillary sinus of male and female computed tomographic scans.

H_1 : There is significant differences in Sizes of ML (Medio Lateral), AP (Anterior Posterior), APH and Volume of Maxillary

sinus of male and female computed tomographic scans.

respectively, and in the case of females, it was 2.1984, 3.2621, 3.1574. The volume calculated according to Sahlstr and Johnson formula depicted the volume of the right maxillary sinus for males to be 13.3231 and for females, it turns out to be 11.7353 as shown in Table 1 and Fig. 1.

RESULTS AND DISCUSSION

The mean values of the right side maxillary sinus AP (width), ML (depth), and AP (height) in males are 2.3000, 3.5320, and 3.1240,

Table 1: Showing descriptive statistics of the left and right side of maxillary sinus dimensions of the male and female in Kerala population

Group Statistics						
	Gender	N	Mean	Std. Deviation	Std. Error Mean	
MLR	Male	20	2.3000	.57099	.12768	
	Female	19	2.1984	.57429	.13175	
APR	Male	20	3.5320	.46141	.10317	
	Female	19	3.2621	.66617	.15283	
APRH	Male	20	3.1240	.59464	.13296	
	Female	19	3.1574	.61878	.14196	
VR	Male	20	13.3231	6.41673	1.43482	
	Female	19	11.7353	5.09617	1.16914	
MLL	Male	20	2.4685	.53059	.11864	
	Female	19	2.3316	.56364	.12931	
APL	Male	20	3.6050	.41160	.09204	
	Female	19	3.3879	.67307	.15441	
APLH	Male	20	3.6410	.37492	.08384	
	Female	19	3.1532	.63559	.14582	
VL	Male	20	32.9007	10.67908	2.38792	
	Female	19	25.8756	11.06580	2.53867	

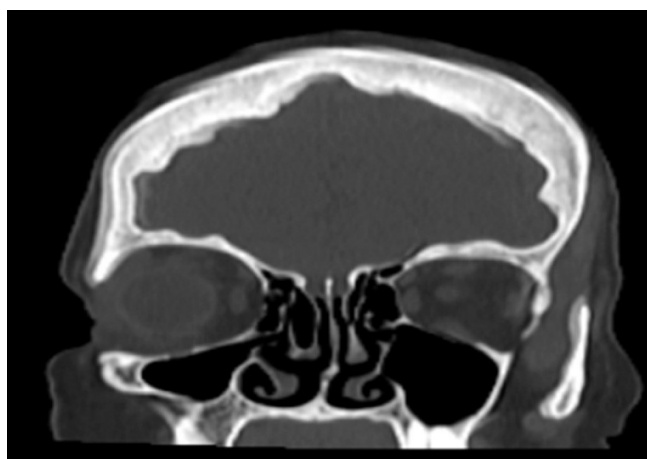


Fig. 1: CT scan image of maxillary sinus axial view

Sex determination using height, length, width, and volume of the maxillary sinus on the right side showed statistically insignificant results with $P > .05$ as shown in Table 2.

Table 2: Showing Statistical results of Maxillary sinus with left volume

		Independent Samples Testa									
		Levene's Test for Equality of Variances		t-test for Equality of Means							
		F	Sig.	t	df	Significance		Mean Difference	Std. Error Difference	95% Confidence Interval of the Difference	
						One-Sided p	Two-Sided p			Lower	Upper
MLR	Equal variances assumed	.574	.453	.554	37	.292	.583	.10158	.18344	-.27010	.47326
	Equal variances not assumed	-	-	.554	36.874	.292	.583	.10158	.18347	-.27020	.47336
APR	Equal variances assumed	3.870	.057	1.477	37	.074	.148	.26989	.18270	-.10028	.64007
	Equal variances not assumed	-	-	1.464	31.874	.077	.153	.26989	.18440	-.10577	.64556
APRH	Equal variances assumed	.129	.722	-.172	37	.432	.865	-.03337	.19430	-.42706	.36032
	Equal variances not assumed	-	-	-.172	36.687	.432	.865	-.03337	.19450	-.42758	.36085
VR	Equal variances assumed	.428	.517	.853	37	.200	.399	1.58787	1.86191	-2.18472	5.36045
	Equal variances not assumed	-	-	.858	35.901	.198	.397	1.58787	1.85084	-2.16617	5.34191
MLL	Equal variances assumed	.275	.603	.781	37	.220	.440	.13692	.17521	-.21809	.49193
	Equal variances not assumed	-	-	.780	36.534	.220	.440	.13692	.17549	-.21881	.49265
APL	Equal variances assumed	5.569	.024	1.222	37	.115	.229	.21711	.17762	-.14278	.57699
	Equal variances not assumed	-	-	1.208	29.531	.118	.237	.21711	.17976	-.15026	.58447
APLH	Equal variances assumed	5.703	.022	2.938	37	.003	.006	.48784	.16607	.15136	.82433
	Equal variances not assumed	-	-	2.900	28.878	.004	.007	.48784	.16820	.14378	.83191
VL	Equal variances assumed	.052	.821	2.018	37	.025	.051	7.02508	3.48199	-.03010	14.08026
	Equal variances not assumed	-	-	2.016	36.714	.026	.051	7.02508	3.48525	-.03856	14.08873

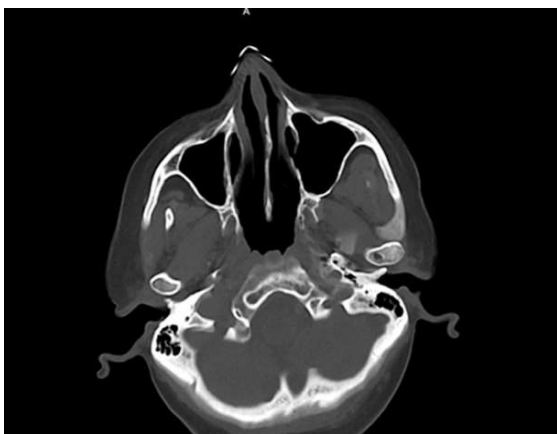


Fig. 2: CT Scan image of sinus of coronal view

The mean values of the left side of maxillary sinus ML (Depth), AP (Width), and AP (Height) in males are 2.4685, 3.6050, and 3.6410, respectively, and in the case of females, it was 2.3316, 3.3879, and 3.1532. The volume calculated according to Sahlstrand-Johnson formula depicted the volume of the left side of the maxillary sinus for males to be 32.9007 and for females, it turns out to be 25.8756 shown in Table 1 and Fig. 1 Sex determination using height, length, and width of maxillary sinus on the left side showed statistically insignificant results with $P > 0.05$ as shown in Table 2. But the left volume and Anteroposterior height showed statistically significant results with $P < 0.05$. In the present study, the measurements of the maxillary sinus AP (width), ML (depth), and AP (height) and volume was evaluated.

SIGNIFICANT PARAMETERS

An independent sample t test was conducted to compare the gender divergences in APLH parameters of left male and female computed tomographic scans. The levene's test for equality of variance it was observed that the value of significance was lesser than 0.05 that suggests mean of equal variances not assumed. There were significant differences [$t(37) = 2.9, p = 0.004$] in scores for Males ($M = 3.64, SD = 0.37$) and Female ($M = 3.15, SD = 0.63$). The magnitude of the differences in the means (mean difference = 0.48, 95% CI: 0.14 to 0.83) was significant. Hence, H1 was supported. Similarly, In case of volume of left maxillary sinuses of male and female

computed tomographic scans. The levene's test for equality of variance it was observed that the value of significance was greater than 0.05 that suggests mean of equal variances assumed. There were significant differences [$t(37) = 2.018, p = 0.025$] in scores for Males ($M = 32.90, SD = 10.67$) and Female ($M = 25.87, SD = 11.06$). The magnitude of the differences in the means (mean difference = 7.02, 95% CI: 0.30 to 14.08) was significant. Hence, H1 was supported.

INSIGNIFICANT PARAMETERS

An independent sample t test was conducted to compare the gender divergences in ML of right maxillary sinuses of male and female computed tomographic scans. The levene's test for equality of variance it was observed that the value of significance was greater than 0.05 that suggests mean of equal variances assumed. There were no significant differences [$t(37) = 0.554, p = 0.292$] in scores for Males ($M = 2.30, SD = 0.570$) and Female ($M = 2.19, SD = 0.574$). The magnitude of the differences in the (mean difference = 0.101, 95% CI: 0.27 to 0.473) was very small. Hence, H1 was not supported. In case of AP of right maxillary sinuses of male and female computed tomographic scans. The levene's test for equality of variance it was observed that the value of significance was greater than 0.05 that suggests mean of equal variances assumed. There were no significant differences [$t(37) = 1.47, p = 0.074$] in scores for Males ($M = 3.53, SD = 0.46$) and Female ($M = 3.26, SD = 0.66$). The magnitude of the differences in the (mean difference = 0.269, 95% CI: 0.10 to 0.64) was very small. Hence, H1 was not supported. In case of APH of right maxillary sinuses of male and female computed tomographic scans. The levene's test for equality of variance it was observed that the value of significance was greater than 0.05 that suggests mean of equal variances assumed. There were no significant differences ($t(37) = 0.432, p = 0.432$) in scores for Males ($M = 3.12, SD = 0.59$) and Female ($M = 3.15, SD = 0.61$). The magnitude of the differences in the (mean difference = 0.33, 95% CI: 0.42 to 0.36) was very small. Hence, H1 was not supported. In case of Volume of right maxillary sinuses of male and female computed tomographic scans. There were no significant differences [$t(37) = 0.853,$

p=0.20] in scores for Males (M=13.32, SD = 6.4) and Female (M=11.73, SD=5.09). The magnitude of the differences in the (mean difference=1.58, 95% CI:2.1 to 5.3) was very small. Hence, H1 was not supported. Similarly, in case of ML of left maxillary sinuses of male and female computed tomographic scans. The levene's test for equality of variance it was observed that the value of significance was greater than 0.05 that suggests mean of equal variances assumed. There were no significant differences [t (37)=0.781, p=.220] in scores for Males (M=2.46, SD=0.53) and Female (M=2.33, SD=0.56). The magnitude of the differences in the (mean difference=0.136, 95% CI:0.21 to 0.49) was very small. Hence, H1 was not supported. Similarly, In case of AP of left maxillary sinuses of male and female computed tomographic scans. The levene's test for equality of variance it was observed that the value of significance was greater than 0.05 that suggests mean of equal variances assumed. There were no significant differences [t (37) = 2.9, p=0.115] in scores for Males (M=3.6, SD =0.41) and Female (M=3.30, SD=0.67). The magnitude of the differences in the (mean difference=0.217, 95% CI:0.15 to 0.58) was very small. Hence, H1 was not supported.

DISCUSSION

Gender determination from maxillary sinus plays a major role in forensic procedures. It has been reported that the size of maxillary sinus of female was found to be smaller than that of male, The accuracy rate of the right and left maxillary sinus measurements together was 69.4% in females and 69.3% in males, with a mean of 69.3%.¹¹ Another study indicated that the maxillary sinus exhibits anatomic variability between different ethnic groups and genders², it is also reported that Volumetric analysis revealed that European crania had larger maxillary sinuses than Zulu crania and male crania had larger maxillary sinuses than females.¹ Another study indicates that the mean area in males was 1.7261 cm² with a standard deviation of 0.2364 and in females was 1.3424 cm² with a standard deviation of 0.2369. The mean perimeter in males was 5.2885 cm, whereas the mean perimeter in females was 4.3901 cm. Hence, showing

males have a larger area and perimeter when compared with females.¹⁰ It is also reported in a study that comparison of X-ray images can be undertaken in an objective way by quantifying the probability of identity even under circumstances where the comparative images were made under different conditions such as rotation.¹⁷⁻¹⁹ In a study of computed tomography measurements of different dimensions of maxillary and frontal sinuses, it is observed that mean value of sinus volume was 15.7±5.3 cm³ and significantly larger in males than in females (P = 0.004) and there was no significant relation between the volume of maxillary sinus with age or side.³ It has been reported in a study of Evaluation of foramen magnum in gender determination using helical CT scanning that the reconstructed CT image can provide valuable measurements for the FM and could be used for sexing when other methods are inconclusive.^{13,16} In a study of sex determination in Egyptian population using MDCT of maxillary sinuses indicated that Cephalo-caudal and size of the left maxillary sinuses by MDCT may be useful to support gender determination in Egyptians (accuracy rate 70.8% for males). However, further studies on gender determination from the maxillary sinuses are needed.¹⁵ In a study of using maxillary sinus for gender determination using a thin slice multidetector computed tomography assisted morphometric study they observed that the values of male sinuses were significantly higher than female values (P <0.001).²⁰ In the present study of maxillary sinuses only the left volume of maxillary sinuses showed significant results whereas the right side volume showed insignificant results. The present study therefore validated the left volume parameter to be considered as appropriate measure to gender of an individual.

CONCLUSION

The findings of the present study suggests that the volume of the left maxillary sinuses can help to determine gender. According to the present study, length, width, and height of the maxillary sinus were used for gender determination on both sides, they proved statistically insignificant results, whereas when left maxillary sinus volume was considered,

the p-value was significant at 95% of confidence levels Hence, this study concludes that left maxillary sinus volume and left anterior posterior height revealed statistically significant results which can be considered when determining the gender of corpses using maxillary sinus computed tomography records. It also supports the use of computed

tomography as a reliable method for assessing different dimensions of the maxillary sinuses.

Conflict of Interest: Nil

Source of Funding: Nil

Acknowledgement: Nil

REFERENCES

1. **Sidhu, R., Chandra, S., Devi, P., Taneja, N., Sah, K., & Kaur, N.** Forensic importance of maxillary sinus in gender determination: A morphometric analysis from Western Uttar Pradesh, India. *European Journal of General Dentistry*. 2014; 3(01), 53-56.
2. **Fernandes, C. L.** Forensic ethnic identification of crania: the role of the maxillary sinus—a new approach. *The American journal of forensic medicine and pathology*. 2014; 25(4), 302-313.
3. **Sahlstrand-Johnson, P., Jannert, M., Strömbeck, A., & Abul-Kasim, K.** Computed tomography measurements of different dimensions of maxillary and frontal sinuses. *BMC medical imaging*. 1992; 11(1), 1-7.
4. **Reichs, K. J.** Quantified comparison of frontal sinus patterns by means of computed tomography. *Forensic science international*. 1993; 61(2-3), 141-168.
5. **Zhen, S., Ma, X., Lu, B., Ming, S., Lin, K., Zhao, L., Zhou, W.** Supercapacitor electrodes based on furan-EDOT copolymers via electropolymerization. *International Journal of Electrochemical Science*. 9(12), 2014: 7518-7527.
6. **Teke, H. Y., Duran, S., Canturk, N., & Canturk, G.** Determination of gender by measuring the size of the maxillary sinuses in computerized tomography scans. *Surgical and radiologic anatomy*. 2007; 29(1), 9-13.
7. **Wind, J., & Zonneveld, F. W.** Computed Tomography of an Australopithecus Skull (Mrs Pies): A New Technique. 1989:7518-7527.
8. **Uthman, A. T., Al-Rawi, N. H., & Al-Timimi, J. F.** Evaluation of foramen magnum in gender determination using helical CT scanning. *Dentomaxillofacial Radiology*. 2012; 41(3), 197-202.
9. **Ariji, Y., Ariji, E., Yoshiura, K., & Kanda, S.** Computed tomographic indices for maxillary sinus size in comparison with the sinus volume. *Dentomaxillofacial Radiology*. 25(1), 19-24.
10. **Sidhu, R., Chandra, S., Devi, P., Taneja, N., Sah, K., & Kaur, N.** Forensic importance of maxillary sinus in gender determination: A morphometric analysis from Western Uttar Pradesh, India. *European Journal of General Dentistry*. 2014; 3(01), 53-56.
11. **Teke, H. Y., Duran, S., Canturk, N., & Canturk, G.** Determination of gender by measuring the size of the maxillary sinuses in computerized tomography scans. *Surgical and radiologic anatomy*. 2007; 29(1), 9-13.
12. **Kanchan, T., & Rastogi, P.** Sex determination from hand dimensions of North and South Indians. *Journal of forensic sciences*. 2009; 54(3), 546-550.
13. **Uthman, A. T., Al-Rawi, N. H., Al-Naaimi, A. S., & Al-Timimi, J. F.** Evaluation of maxillary sinus dimensions in gender determination using helical CT scanning. *Journal of forensic sciences*. 2011; 56(2), 403-408.
14. **Eshak, G. A., Ahmed, H. M., & Gawad, E. A. A.** Gender determination from hand bones length and volume using multidetector computed tomography: a study in Egyptian people. *Journal of forensic and legal medicine*. 2011; 18(6), 246-252.
15. **Amin, M. F., & Hassan, E. I.** Sex identification in Egyptian population using Multidetector Computed Tomography of the maxillary sinus. *Journal of forensic and legal medicine*. 2012; 19(2), 65-69.
16. **Giacomini, G., Pavan, A. L. M., Altemani, J. M. C., Duarte, S. B., Fortaleza, C. M. C. B., Miranda, J. R. D. A., & De Pina, D. R.** Computed tomography-based volumetric tool for standardized measurement of the maxillary sinus. *PLoS one*. 2018; 13(1), e0190770.
17. **Riepert, T., Ulmcke, D., Schweden, F., & Nafe, B.** Identification of unknown dead bodies by X-ray image comparison of the skull using the X-ray simulation program Foxsis. *Forensic science international*. 2001; 117(1-2), 89-98.
18. **Quatrehomme, G., Fronty, P., Sapanet, M., Grévin, G., Bailet, P., & Ollier, A.** Identification by frontal sinus pattern in forensic anthropology. *Forensic science international*. 1996; 83(2), 147-153.
19. **Pirner, S., Tingelhoff, K., Wagner, I., Westphal, R., Rilk, M., Wahl, F. M., Eichhorn, K. W. (2009).** CT-based manual segmentation and evaluation of paranasal sinuses. *European archives of oto-rhino-laryngology*. 2009; 266(4), 507-518.
20. **Ekizoglu, O., Inci, E., Hocaoglu, E., Sayin, I., Kayhan, F. T., & Can, I. O. (2014).** The use of maxillary sinus dimensions in gender determination: a thin-slice multidetector computed tomography assisted morphometric study. *Journal of Craniofacial Surgery*. 2014; 25(3), 957-960.