

ORIGINAL ARTICLE

# Incidental Findings of Silent Liver Diseases in Autopsy: A Study at Tertiary Care Hospital

Niveditha. S<sup>1</sup>, Radha R. K<sup>2</sup>, Prathima. S<sup>3</sup>

## ABSTRACT

### INTRODUCTION

Autopsy survey of 80 cases of liver specimens over a period of 2 years done in Vydehi Institute of Medical Science and Research Center, Department of Pathology, Bangalore. Quite rightly liver is, called as “The custodian of milieu interior” Autopsy study is useful to monitor the cause of death and to plan medical strategy. The term “alcoholic liver disease” encompasses a spectrum of pathologic conditions ranging from isolated steatosis to established cirrhosis. Within this spectrum, varying degrees of inflammation, hepatocellular ballooning degeneration, hepatocyte necrosis, cholestasis, and fibrosis may be encountered. This article reviews the characteristic histologic features of the many forms of alcoholic liver disease.

### Author's Credentials:

<sup>1</sup>Final year Post Graduate, <sup>2</sup>Associate Professor, <sup>3</sup>Professor and HOD, Department of Pathology, Vydehi Institute of Medical Sciences and Research Centre, Bangalore 560066, Karnataka, India.

### Corresponding Author:

**Niveditha. S**, Final year Post Graduate, Department of Pathology, Vydehi Institute of Medical Sciences and Research Centre, Bangalore 560066, Karnataka, India.

**Email:** [bharathiraju9980@gmail.com](mailto:bharathiraju9980@gmail.com)

**Received on:** 25.06.2022

**Accepted on:** 28.09.2022

KEYWORDS | ALCOHOLIC STEATOHEPATITIS; ASH; NON ALCOHOLIC STEATOHEPATITIS; NASH; CIRRHOSIS; BENIGN SOLITARY CYST; BSC



### How to cite this article:

Niveditha. S, Radha R. K, Prathima. S/ Incidental Findings of Silent Liver Diseases in Autopsy: A Study at Tertiary Care Hospital. Indian J Forensic Med Pathol.2022;15(4):243-247.

### INTRODUCTION

Liver is vulnerable to a wide variety of metabolic, toxic, microbial and circulatory insults. In some instances, the disease is primary while in others the hepatic involvement is secondary to cardiac de-compensation, alcoholism or extra hepatic infections. They either go undiagnosed or are found incidentally during general health check-ups, investigations for other diseases, surgery or at autopsy. Quite

rightly liver is, called as “The custodian of milieu interior” Autopsy study is useful to monitor the cause of death and to plan medical strategy.<sup>1</sup>

Abnormal findings in liver autopsy can be fatty change, hepar lobatum, glycogen storage disease, acute phosphorus poisoning, hemosiderosis, syphilis, actinomycosis, infarcts, cloudy swelling, tuberculosis, acute

passive hyperemia, chronic passive hyperemia, amyloidosis, abscess, hydatid cyst, malignancy, cirrhosis and acute yellow atrophy.<sup>3</sup>

These diseases can be seen as “silent liver disease” in the histological findings during autopsy. Alcohol abuse generally leads to three pathologically distinct liver diseases; these are fatty liver, hepatitis and alcoholic cirrhosis. Any one or all the three can occur at the same time, in the same patient.<sup>4</sup>

The underlying causes of chronic liver diseases vary in different geographic areas and are based on various factors such as socioeconomic status, life style, diet, local or regional infections and other endemic diseases.<sup>5</sup>

**MATERIAL AND METHODS**

Eighty specimens of liver of the deceased, irrespective of age and sex, received over a period of 2 years, in the Department of Pathology, Vydehi institute of medical science and research centre, Bangalore, were examined grossly as well as microscopically. Postmortem examination being done in our institution are usually, cases of road/railway accidents, drowning, hanging and poisoning. Liver specimens were mostly received as a part of examination of multiple viscera. In each case, important information regarding age, sex, clinical findings, food habit, alcoholic usage, suspected cause of death and post mortem findings were obtained from post mortem papers. Gross examination of the liver specimen was done with regards to the weight, surface, capsule, color, consistency, etc. Formalin fixed liver tissues stained with Hematoxylin and Eosin (H & E) were examined under the microscope. The findings of the examination were recorded and analysed. Autolytic changes were seen in the specimens as they are brought by the police & reach pathology department/histopathology laboratory quite late.

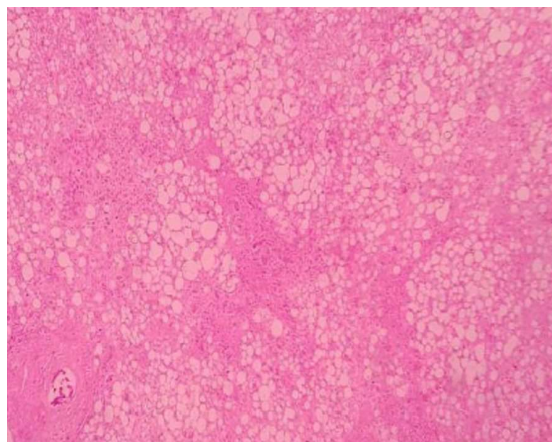
**RESULTS**

During the study, 80 cases were evaluated, out of which 68(85%) were males and 12(15%) were females.

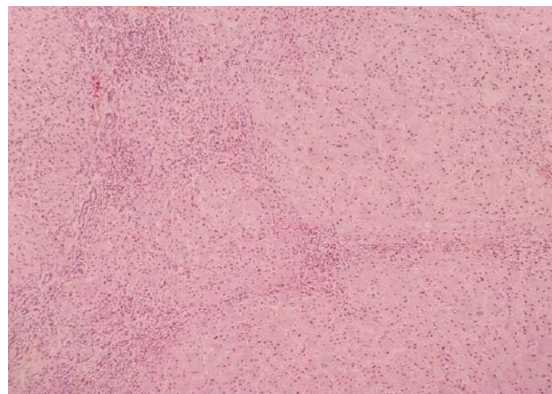**Table 1:** Histopathological findings

Histopathology	No. of cases	Percentage
Fatty change	36	45%
Chronic venous congestion	25	31.2%%
Normal	7	8.7%
Cirrhosis	4	5%
Autolysed	4	5%
Hepatic steatosis	3	3.7%
Benign solitary cyst	1	1.2%
Total	80	100%

Out of 80 specimens, 36 (45%) showed fatty change (Fig. 1), followed by Chronic venous congestion 25 (31.2%) cases, normal 7(8.7%) cases, cirrhosis 4(5%) cases (Fig. 2), autolysed 4(5%) cases, Hepatic steatosis 3(3.7%) case (Fig. 3) and 1 (1.2%) with Benign solitary cyst (Fig. 4).



**Fig. 1:** Section showing small and large fat droplets in fatty liver H & E X40



**Fig. 2:** Section showing regeneration parenchymal nodule surrounded by bands of fibrous tissue in cirrhosis H & E X100

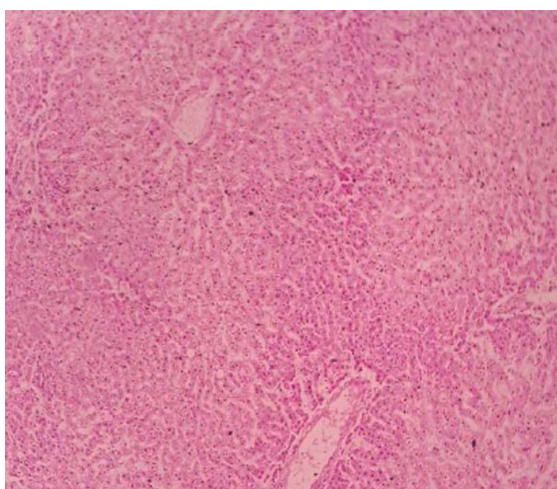


Fig. 3: Section showing Mallory-Denk bodies H & E

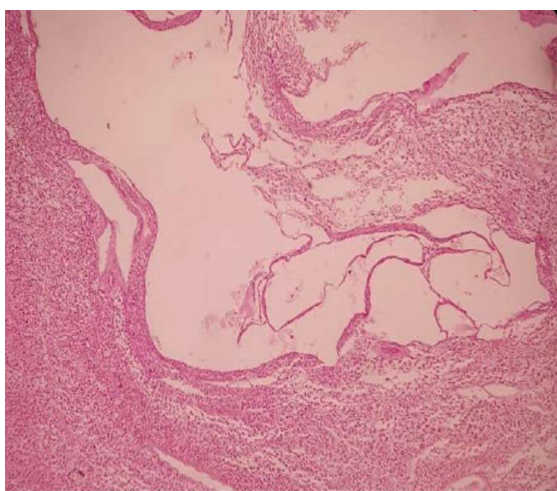


Fig. 4: Section showing cyst lined by flat epithelium H & E X40

Table 2: Age and sex wise incidence of all the cases.

Age group (years)	Male (%)	Female (%)	Total (%)
<20	6(8.8)	2(16.6)	8(10)
20-30	17(25)	3(25)	20(25)
31-40	25(36.7)	4(33)	29(36.2)
41-50	7 (10.3)	1(8.3)	8(10)
51-60	8(11.7)	1(8.3)	9(11.2)
61-70	2(2.9)	0(0)	2(2.5)
71-80	3(4.4)	1(8.3)	4(5)
Total	68(100)	12(100)	80(100)

Table 3: Sex wise distribution of all the cases.

Histopathology	Male (%)	Female (%)	Total (%)
Fatty change	28 (45.9)	8(42.1)	36 (45)
Chronic venous congestion	18(29.5)	7(36.8)	25(31.2)
Normal	4(6.5)	3(15.7)	7(8.7)
Cirrhosis	4(6.5)	0(0)	4(5)
Autolysed	3(4.9)	1(5.2)	4(5)
Hepatic steatosis	3(4.9)	0(0)	3(3.7)
Solitary benign cyst	1(1.6)	0(0)	1(1.2)
Total	61(100)	19(100)	80(100)

### DISCUSSION

In the present study, maximum number of cases were seen in age group 31-40 (36.2%) years which was similar to studies conducted by Prashant R et al. and Behers A et al. i.e. 30.1% and 23.4% respectively.<sup>2,3</sup>

Liver diseases predominated in males in the present study (85%), comparable with the findings of, Singal P et al. (82.8%) and Sotoudehmanesh R et al. (86.7%).<sup>1,5</sup> This may be attributed to the fact that men are more prone to alcohol consumption.

Present study showed that fatty change (45%) was the most common silent liver disease which was similar to studies by Singal et al. (34%) and Prasant R et al. (30.1%).<sup>1,2</sup> This is because a large percentage of people in this region take alcohol which is major causative factor for developing fatty change. Regular intake of alcohol between 40-80 gm increases the liver weight and frequency of fatty changes in liver.

The understanding of hepatic steatosis has progressed considerably in recent years. Several studies have challenged previous assertions that macrovesicular steatosis is completely benign. They indicate that fatty liver of either alcoholic or non alcoholic etiologies can coincide with or lead to necro inflammation and fibrosis. Surprisingly, experimental studies have implicated steatosis itself as a direct cause of more advanced pathology. The mere presence of oxidisable fat within the liver is enough to trigger lipid peroxidation.

Nevertheless, many patients with steatosis never progress to necroinflammation or fibrosis. These observations led to the “two hit hypothesis”. In addition to steatosis (the first hit), development of steatohepatitis requires the presence of some other factors (second hit).<sup>6</sup>

Second most common finding of chronic venous congestion was seen in 25(31.2%) cases, which was also the second most common cause (27%) in a study by Singal P et al.<sup>1</sup> This could be due to the fact that CVC liver is the terminal end stage of death in most of the liver autopsies. Also referred to as acute hepatic ischemic necrosis, ischemic hepatitis, shock liver, congestive hepatopathy.

Cirrhosis is the end stage of many chronic liver diseases. This term refers to diffuse hepatic fibrosis with replacement of normal lobular architecture by parenchymal nodules separated by fibrous tissue.

Architectural changes are histologically best appreciated on a reticulin stain.<sup>6</sup> In our study, cirrhosis was seen in 5% which was comparable to the study by Prashant R. et al.<sup>2</sup> showing 2.44% cases having cirrhosis whereas Behera A et al showing 9.37%.<sup>3</sup>

In our study, 3 out of 4 cases (75%) had history of alcohol intake; of these all were males. 3 out of 4 cases (75%) showed micronodularity while remaining 1 (25%) showed mixed nodularity. Similar results were seen in a study by Majethia NK et al. who studied the pattern of liver cirrhosis in 118 autopsy patients.<sup>7</sup>

History of alcohol was seen in 83.25% of cases of which 95% were males. Among alcoholics, 48.4% showed micronodularity. Alcoholism contributes to an increase in chronic liver disease especially cirrhosis which is completely preventable by abstinence from alcohol.

In the present study, steatohepatitis was seen in 3(3.7%) cases. Kour B et al. reported 11(9.2%) of cases having hepatitis, while in a study of Singal et al. hepatitis was found in 9% cases. Steatohepatitis occurs in chronic alcoholics (alcoholic steatohepatitis or ASH) and also in patients who do not consume alcohol (non alcoholic steatohepatitis or NASH).

One of the case showed Benign solitary cyst 1.2% with the history of jaundice in a 26 year old male usually an incidental finding. Zhang XF et al observed solitary benign cyst in only 0.9%, which was lower compared to our study. The study also included 7(8.7%) normal liver specimens and 4(5%) autolyzed specimen.

In summary, asymptomatic fatty liver be the most common silent liver disease among the general population of this region followed by cirrhosis of liver, hepatitis and chronic venous congestion.

Autopsy is a magnificent learning tool in the hands of pathologists to study the histopathological spectrum of diseases which help to study the insitu process as well as rare incidental findings.

---

#### CONCLUSION

---

Silent liver diseases are very common amongst apparently healthy individuals. In this study asymptomatic fatty liver was the most common silent liver disease followed by chronic venous congestion.

Maximum cases were in the age group of 31-40 years with a Male : Female ratio of 6:1. If not detected early, some of these conditions may lead to serious outcomes.

Histopathology of fatty change which has progressed to cirrhosis of varying etiological factors can be studied in post-partum cases and helps undergraduates and postgraduates to understand the etiopathogenesis, gross and microscopic features of cirrhosis.

The study was conducted only on specimens collected from the mortuary and may not reflect the actual pattern of liver diseases. The use of autopsy findings in conjunction with other scientific methods and investigative techniques remains as valuable today as it was centuries ago, both in daily practice and for scientific endeavor.

---

#### KEYPOINTS

---

1. Liver is vulnerable to a wide variety of metabolic, toxic, microbial and circulatory insults.
2. Quite rightly liver is, called as “The

custodian of milieu interior” Autopsy study is useful to monitor the cause of death and to plan medical strategy.

3. Indicate that fatty liver of either alcoholic or non alcoholic etiologies can coincide with or lead to necroinflammation and fibrosis.
4. Cirrhosis is the end stage of many chronic liver diseases.
5. The use of autopsy findings in conjunction

with other scientific methods and investigative techniques remains as valuable today as it was centuries ago, both in daily practice and for scientific endeavor.

---

**Conflict of Interest:**

Nil

**Source of Funding:**

Nil

**Acknowledgement:**

Nil

---



---

**REFERENCES**

---

1. **Singal P et al:**  
*Incidental Findings in Autopsy Examination of liver: A study of 70 cases. Ann. Int. Med. Den. Res. 2017;3(3):PT30-PT32.*
2. **Prashant R et al:**  
*Incidental findings in autopsy examination of liver: a study at tertiary care hospital. Int J Community Med Public Health 2016;3:697-9.*
3. **Behera A et al:**  
*Liver autopsy study-incidental pathological findings. Trop J Path Micro 2017;3(4):390-395.*
4. **Kour B et al.**  
*Incidental findings in Autopsy Examination of Liver-A One Year Retrospective Study. Int J Health Sci Res. 2019;9(8):68-70.*
5. **Sotoudehmanesh R, Sotoudeh M, Asgari A, Abedi-Ardakani B, Tavangar SM, Khakinejad A et al.**  
*Silent Liver Diseases in Autopsies from Forensic Medicine of Tehran. Archives of Iranian Medicine 2006 Oct; 9(4):324-28.*
6. **Desmet V, Rosai J. Liver:**  
*Rosai and Akerman's Surgical Pathology. Vol 1. St louis, USA: Elsevier Mosby; 2004:925-940.*
7. **Majethia NK, Patil MV, Kalgutkar AD.**  
*A Histo-Pathological Study of Liver in 118 Cases of Cirrhosis. J Liver. 2016; 5:193.*
8. **These Neil D.**  
*Liver and Gallbladder. Robbins and Cotran pathologic Basis of Disease; Vol.2. South Asia Edition. Elsevier India; 2014:837-841.*
9. **Majethia NK, Patil MV, Kalgutkar AD.**  
*A Histo-Pathological Study of Liver in 118 Cases of Cirrhosis. J Liver. 2016; 5:193.*
10. **Thamil SR, Selvam V, Subramaniam PM.**  
*Common Silent Liver Disease In and Around of Salem Population: An Autopsy Study Journal of Clinical and Diagnostic Research. 2012; 6(2):20710.*
11. **Devi Ph. M, Myrthong B G, Meera Th., Nabachandra H.**  
*Pathological Findings of Liver in Autopsy Cases A Study at Imphal. J Indian Acad Forensic Med 2013; 35:206-10.*

