

A Orthopantomography Study of Age Estimation Based on Periodontal Ligament Visibility of Mandibular Third Molars in Chennai Population: An Aid in Forensics

Rangeela M.¹, Sreedevi Dharman²

How to cite this article:

Rangeela M., Sreedevi Dharman. A Orthopantomography Study of Age Estimation Based on Periodontal Ligament Visibility of Mandibular Third Molars in Chennai Population: An Aid in Forensics. Indian J Forensic Med Pathol.2023;16(4):253-259.

ABSTRACT

BACKGROUND: Forensic age determination has evolved to be intriguingly significant and relates to the challenges originating from globalisation as a result of a growing amount of foreign nationals with questionable birth date information and to identify victims who are unknown.

AIM: Aim of this research was to evaluate the estimation of age through visualisation of periodontal ligament (PDL) around fully mineralised lower third molars in the Chennai population, and also to assess the 18-year age threshold using PDL visibility.

MATERIALS AND METHOD: The research was a retrospective analysis that involved 100 OPGs (orthopantomographs) from the archives of the Department of Oral and Maxillofacial Radiology from 2021 to 2022 were analysed to determine PDL present around the mandibular third molars. Grading each mandibular third molar was done by two observers. IBM SPSS version 23 was used to statistically evaluate the gathered data.

RESULTS: Among 100 study subjects, the mean age group was found to be 24.2 years. The frequency distribution of age was inferred from that of the study participants, 15% were under the age of 18, and 85% were above the age of 18. Males and girls with both lower third molars on the left and right had grades of stage 1 (34%), stage 2 (31%), and stage 3 (20%) at the age of 18. The 18-year threshold can be established by using periodontal ligament visibility, according to our findings, starting from Stage 1. The relationship between the variables was examined using the Chi square test, which produced a very significant p value of 0.00.

CONCLUSION: Radiographic age evaluation was a simple, repeatable, non-invasive technique that can be applied to both living and deceased people. Our research indicated that less than 18 years old was the minimal age for Stage 0 in both males and females. At the onset of stages

Author's Credentials: ¹Research Associate, ²Reader, Department of Oral Medicine and Radiology, Saveetha Dental College and Hospitals, Saveetha Institute of Medical and Technical Sciences, Saveetha University, Chennai 600077, Tamil Nadu, India.

Corresponding Author: Sreedevi Dharman, Reader, Department of Oral Medicine and Radiology, Saveetha Dental College and Hospitals, Saveetha Institute of Medical and Technical Sciences, Saveetha University, Chennai 600077, Tamil Nadu, India.

Email: sreedevi@saveetha.com

Received on: 04-09-2023

Accepted on: 29-12-2023

1, 2, and 3, all males and females were at least eighteen years old. Stages 1, 2, or 3 indicate that the person is older than 18. The populace of Chennai would benefit from this innovative method of age estimation for use in forensics.

KEYWORDS: Age estimation; Periodontal ligament; Mandibular third molar; Forensic.

INTRODUCTION

Forensic age determination has evolved to be intriguingly significant and relates to the challenges originating from globalisation as a result of a growing amount of non-national individuals with uncertain information about their birth date and to identify unknown victims, calculating the age at death, identifying cluster victims, figuring out who qualifies for social benefits, and helping immigration services in the processing of undocumented immigrants.¹ Accurately determining the person's age is crucial when attempting to identify a deceased person.² Third-molar mineralization has frequently been employed as a technique for forensic age determination. Estimating age is required throughout both criminal and civil processes.³ Teeth eruption or formation can be used to gauge dental development. In contrast to eruption, which is a discontinuous and variable measurement influenced by a number of factors including dental caries, malnutrition, early loss of deciduous teeth, and malalignment, root formation is thought to be a more robust measure with a low coefficient of variation, high heritability, and resistance to environmental effects.⁴ Research on the growth and development of teeth benefits from knowledge of the time and sequence of tooth eruption. To determine a child's or adult's chronological age, several techniques are available.⁵

The primary radiographs of specific structures, such as the fusion of long bones, the epiphyseal union of the anterior iliac crest, the epiphyseal head, the fusion of the sphenoid bone with the basilar part of the occipital bone, and the medial extremity of the clavicle, are used to estimate age using skeletal maturity.^{6,7} The most frequently used techniques for determining chronological age are those that use an orthopantomograph or cephalometric radiograph to visualise dental development.⁸ The presence or absence of wisdom teeth, the age at which they erupt, the eruption's position and direction, and its timing are important factors, especially in forensic dentistry.⁹ With the exception of the third molars, most teeth have calcified and erupted after the early teen years. Therefore, the most important factor in determining age between the late teens and early twenties is the third molar's development.¹⁰ Thus, the evaluation of dental radiographs is capable of being easy and non-invasively used to staging a third molar. To describe the dental maturation process, several staging systems have been developed.¹¹ Olze *et al.* presented a technique for estimating dental age in the German population by visualizing the

PDL of the mandibular third molars from dental radiographs taken of patients between the ages of 15 and 40. The PDL visibility was classified into four stages from 0 (entirely visible in both roots) to 3 (visible in only part of one root). The chronological age for each grade of periodontal ligament visibility (PLV), along with the minimum age and suggested PLV, was reported in this study, which was useful in identifying individuals who were younger than 18 or who were between the ages of 18 and 21 years.¹² In another study, Timme *et al.* found that while the minimum age of periodontal ligament visibility stages was appropriate for males under the age of 21, but not for females, it was unable to distinguish between individuals under the age of 18.¹³

As a result, age estimation varied across different population groups and location, previous studies are reported in Germany¹², Chinese¹⁴, Portuguese¹⁵ and in India Mumbai.¹⁶ Studies were not available for the Chennai population. Therefore, the purpose of this study was to determine the 18-year age threshold using PDL visibility and to evaluate the estimation of age using visualizing the periodontal ligament around fully mineralized lower third molars in the Chennai population.

MATERIALS AND METHOD

100 orthopantomographs from the archives of Saveetha Dental College and Hospital's Department of Oral Medicine and Radiology in Chennai were screened for the visibility of PDL surrounding the mandibular third molars between the years of 2021 and 2022. This is a retrospective study.

Inclusion Criteria: Patients with fully mineralized mandibular third molars, ranging in age from 17 to 40 were included.

Exclusion Criteria: This study did not include any pathological conditions that could impede PDL visibility, radiographs that were faulty, or periapical pathology related to mandibular third molars, such as cysts and tumors.

Radiological evaluation of the third molars:

One hundred OPGs were assessed for the mandibular third molars on the left or right side. Two selected observers examined the radiographs. Scores were assigned to every mandibular third molar by observers. Olze *et al.* assigned the PDL visibility of third molars with full root formation including apical closure wherein four scores were given.¹² (Fig. 1)

Stages:

Stage 0: PDL is visible along the full length of all roots

Stage 1: PDL is invisible in one root from apex to more than half root.

Stage 2: PDL is invisible along almost the full length of one root or along part of the root in 2 roots or both.

Stage 3: PDL is invisible along almost the full length of 2 roots.

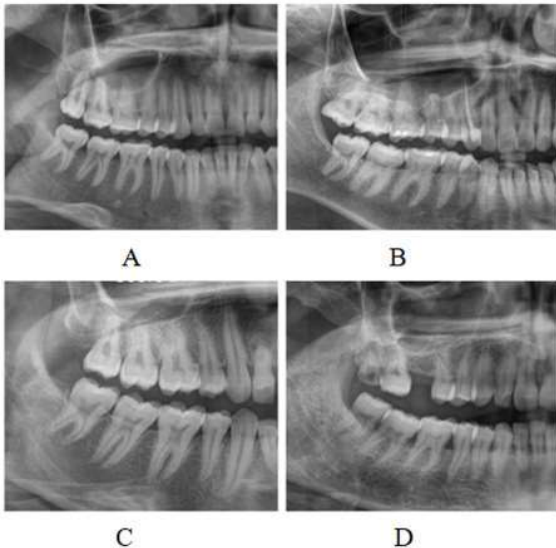


Fig. 1: The radiographic visibility in lower third molars is displayed by the OPG as follows: (A) Stage 0 (B) Stage 1 (C) Stage 2 (D) Stage 3.

STATISTICAL ANALYSIS

Orthopantomographs was assessed and cross-checked by 2 oral radiologists. Data was collected and compiled in an excel spreadsheet. IBM SPSS v23 software was used to perform statistical analysis on the data. To investigate the relationship between the various research variables, the chi square test was used. ANOVA test was performed to identify the mean of age in different populations.

RESULTS

Among 100 study subjects, the mean age group was found to be 24.2 years. 15% of the study participants were under the age of 18, and 85% were over the age of 18, according to the frequency distribution of age shown in Fig. 1. Hence, the above 18 years age group was reported higher in number. The gender distribution of the patients was reported as 59% were males and 41% were females shown

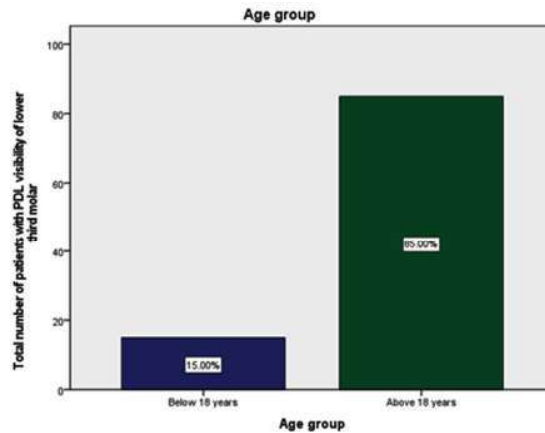


Fig. 1: The frequency distribution of age groups is displayed in a bar graph. The X-axis indicates the age group above or below 18 years. The percentage of people who reported to this study is shown on the Y-axis. Highest prevalence was among above 18 years of age group (green) and below 18 years were 15%.

in Fig. 2, Fig. 3 shows the periodontal ligament visibility frequency distribution. The vast majority of the study participants belonged to Stage 1 (34%) followed by Stage 2 (31%), Stage 3 (20%) and Stage 0 (15%). Fig. 4 shows the frequency distribution of the age group with PDL visibility stage. It was inferred participants below 18 years belong to stage 0 and stage 1, 2 and 3 was seen in above 18 years age group. Using the chi square test, the relationship between the variables was assessed, and a p value of 0.00 indicated that it was highly significant. Fig. 5 shows tooth number and PDL visibility stage. The most common third molars in stage 1 (18%) were lower left (38) and most common in stages 1 and 2 (16%) were lower right (38) molars. Chi-square was

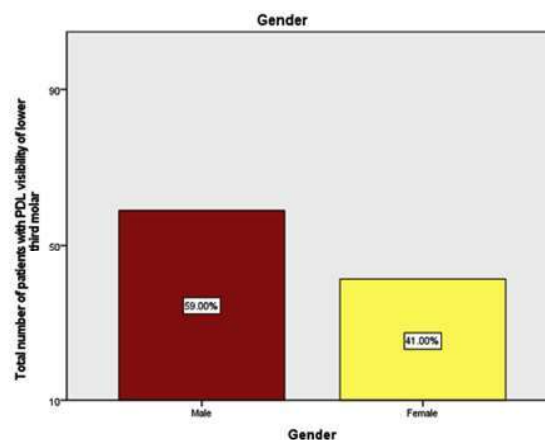


Fig. 2: The gender distribution is shown in a bar graph. Males are indicated by red, and females by yellow. Males (59%) made up the majority of the patients reported for the study, compared to females (41%).

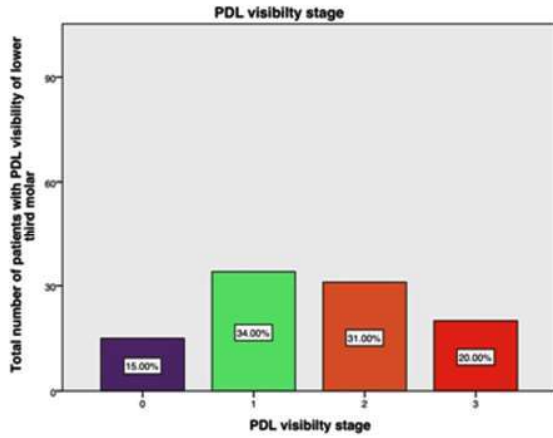


Fig. 3: The PDL visibility stage frequency distribution for each individual is displayed as a bar graph. Stages 0-3 are indicated by the X-axis. The percentage of participants in this study is indicated on the Y-axis. Highest prevalence was among stage 1 (light green) followed by stage 2 (orange) was 31%, stage 3 (red) was 20% and stage 0 (purple) was 15%.

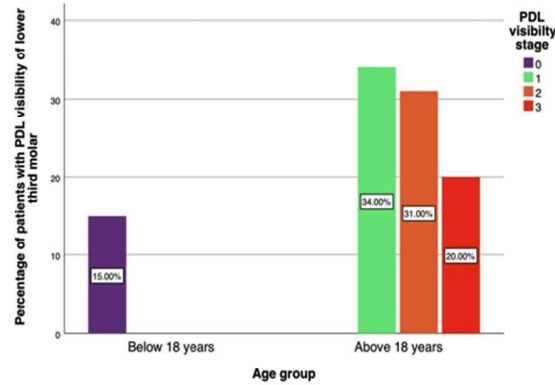


Fig. 4: Bar graph shows the age group and PDL visibility stage. The age group is shown on the X-axis, and the number of participants in our study is shown on the Y-axis. Stage 0 (purple) was seen only in individuals below 18 years (15%) and stage 1 (light green) was seen in the majority of the above 18 years old age group (34%) followed by stage 2 (orange) was 31% and stage 3 (vermillion) was 20%. Chi-square p value=0.00, was statistically significant.

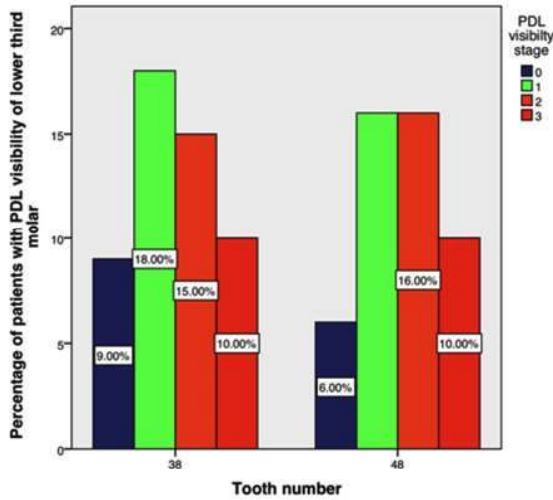


Fig. 5: The tooth number and PDL visibility stage are displayed in a bar graph. The tooth number is indicated on the X-axis, and the number of participants in our study is indicated on the Y-axis. The most common third molars in stage 1 (18%) were lower left (38) and most common in stages 1 and 2 (16%) were lower right (38) molars. The chi-square p-value of 0.01 indicated statistical significance.

statistically significant, with a p-value of 0.01. In stage 1, the lower right third molar (48) and lower left third molar (38), respectively, had the highest prevalence (18% and 16%). Statistics showed that the chi-squared p value=0.01 was significant.

In case of males, radiography visibility of 48 revealed the following results: The mean age was statistically significantly different for each stage category ($p < 0.01$), with the mean value being lowest in stage 0 and highest in stage 3. Stage 0 was

initially identified at the age of 17, with a mean age of 18. At the age of 19, stage 1 was noted, with a mean age of 22. Stage 3's first indication appeared at age 25, with a mean age of 37.4 years, while stage 2's first indication appeared at age 24, with a mean age of 33.5 years. (Table 1).

Table 1: Mandibular right third molar age and stages of radiographic visibility of the periodontal ligament in males.

PDL Visibility stage	N	Mean	Std. Deviation	Std. Error of Mean	Minimum	Maximum
0	2	18.00	1.414	1.000	17	19
1	8	22.00	2.976	1.052	19	29
2	12	33.50	7.740	2.234	24	48
3	7	37.43	11.253	4.253	25	39

In female cases, radiographic visibility of 48 produced the following outcomes: There was a statistically significant difference ($p < 0.01$) in the mean age between the Stage categories, with the mean values being highest in Stage 3 and lowest in Stage 0. At 17.4, the first indications of stage 0 were observed, with a mean age of 17.4 years. At age 20, stage 1 was first observed, with a mean age of 21.7 years. Stage 2 was first noticed at age 21, with a mean age of 33, and stage 3 was noticed at age 32, with a mean age of 39.3 years. (Table 2).

Table 2: Age and stages of the female mandibular right third molar's periodontal ligament's radiographic visibility.

PDL Visibility stage	N	Mean	Std. Deviation	Std. Error of Mean	Minimum	Maximum
0	5	17.40	.548	.245	17	18
1	7	21.71	1.604	.606	20	25
2	4	33.00	8.042	4.021	21	37
3	3	39.30	14.422	8.327	32	40

In male cases, radiographic visibility of 38 showed the following results: A statistically significant ($p < 0.01$) difference in mean age was observed between the Stage categories. At the age of 17, with a mean of 17.67 years, stage 0 was first observed. For Stage 1 the first observed age was 20 years with mean age 23.8 years. Stage 2 was noted at 30 years old, with a 35.1-year-old mean. In stage 3, the mean age was 38.25 years, and the first observed age was 34 years. (Table 3).

Table 3: Mandibular left third molar age and stages of radiographic visibility of the periodontal ligament in males

PDL Visibility stage	Mean	N	Std. Deviation	Std. Error of Mean	Minimum	Maximum
0	17.67	3	.577	.333	17	18
1	23.80	10	2.348	.742	20	28
2	35.11	9	4.457	1.486	30	36
3	38.25	8	9.004	3.183	34	39

In female cases, radiographic visibility of 38 produced the following outcomes:

A statistically significant difference was observed ($p < 0.01$). With a mean age of 17.8, the first appearance of Stage 0 occurred at 17 years old. Stage 1 was first observed at 17 years old, with a mean age of 17.8 years. In Stage 2, the mean age was 31.5 years, and the first recorded age was 28 years. The mean age for Stage 3 was 39.7 years, with the first observed age being 30 years (Table 4).

Table 4: Age and stages of the female mandibular left third molar's periodontal ligament's radiographic visibility.

PDL Visibility stage	N	Mean	Std. Deviation	Std. Error of Mean	Minimum	Maximum
0	6	17.83	.408	.167	17	18
1	8	21.13	1.808	.639	19	25
2	6	31.50	4.278	1.746	28	37
3	2	39.70	16.971	12.000	30	39

DISCUSSION

Teeth are frequently used to estimate age because they are preserved for a very long time after all other tissues and bones have disintegrated. A quick, repeatable, non-invasive technique that can be applied to both living and unidentified deceased individuals is radiographic age assessment.¹⁷

Age estimation is one of the most crucial tasks for a forensic department when birth records are not well kept. It is an optical phenomenon that the periodontal ligament vanishes.¹⁸ This could have a biological basis in which the membrane becomes so thin that radiographs cannot show it.¹⁹ The development of third molar roots is typically taken into account in forensic dentistry when estimating age, particularly when establishing the 18-year-old cut-off to distinguish between a person's status as a child or adult.²⁰

It was discovered that individuals under the age of eighteen, regardless of gender, exhibited stage 0. Males' right and left third molars showed signs of stage 1 onward when they surpassed the age of 18. It follows that if a person is discovered in any of the stages starting with Stage 1, they have achieved major status and are older than 18 years old. Our findings support the observations made by Sequeira *et al.*¹⁵ and Olze *et al.*¹²

The age range in our study was 17–40 years, whereas the age range in Demirjian *et al.*'s study was only 3–17 years, despite the fact that they presented a very good method for age estimation from the radiological appearance of the mandibular third molar.²¹ Timme *et al.*¹³ found that the minimum age for stages 2 and 3 was at least 21 years old in their investigation. Our study's results are consistent with this finding.

Another observation from our investigation was that, starting from stage 2, the participants were older than.²¹ Consequently, stage 2 could be applied to establish the 21-year-old cut-off point. Another significant age in forensics is 21. This is consistent with the findings of Guo *et al.*¹⁴ regarding the Chinese populace. But Sequeira *et al.* pointed out that in the Portuguese population, Stage 3 would fulfill this function, emphasizing the variation seen in various populations. Therefore, in order to increase prediction efficacy, it is recommended that this methodology be evaluated and used in particular populations.¹⁵

In both the left and right mandibular molars, there was a significant positive correlation ($p = 0.000$) between the periodontal ligament visibility

and chronological age. This was consistent with other research.²¹ Since the entire study depends on OPG observation a crucial step in standard forensic age estimation the same X-ray can be utilized to assess the third molars' periodontal ligament visibility.

In our study, strong positive association was observed between chronological age and the periodontal ligament visibility in right as well as left mandibular molars ($p = 0.000$). This was in accordance with other studies.²² The technique's benefit is that it will reduce costs and time spent without increasing radiation exposure.²³ Additionally, exhibits strong intra- and inter-observer agreement and is a straightforward methodology that is applicable on a regular basis.²⁴ There are certain restrictions associated with this technique. Specifically, third molars must have fully developed roots, be free of caries or other dental disease, and be fully erupted without being

impacted. Future research could make use of this and assess it.

CONCLUSION

In our study, both males and females had to be younger than 18 years old to be eligible for Stage 0. For both males and females, the minimum age at which Stages 1, 2, and 3 initially manifested was greater than 18. We can therefore conclude that a person should be older than eighteen if they exhibit Stages 1, 2, or 3. Third molar growth and calcification are unquestionably not the preferred development marker. Still, it makes sense because there aren't any other promising signs in the late teens and early twenties.

Conflict of Interest: Nil

Source of Funding: Nil

REFERENCES

- Schmeling A, Grundmann C, Fuhrmann A, Kaatsch HJ, Knell B, Ramsthaler F, Reisinger W, Riepert T, Ritz-Timme S, Rösing FW, Röttscher K.** Criteria for age estimation in living individuals. *International journal of legal medicine.* 2008 Nov;122:457-60.
- Yang Z, Geng K, Liu Y, Sun S, Wen D, Xiao J, Zheng Y, Cai J, Zha L, Liu Y.** Accuracy of the Demirjian and Willems methods of dental age estimation for children from central southern China. *International Journal of Legal Medicine.* 2019 Mar 5;133:593-601.
- Akshaya A, Arthanari A.** Dental Age Estimation of Lower Left Third Molar (38) Using Modified Willems Method in South Indian Population. *Journal of Research in Medical and Dental Science.* 2021 Oct;9(10):77-82.
- Caldas IM, Júlio P, Simões RJ, Matos E, Afonso A, Magalhães T.** Chronological age estimation based on third molar development in a Portuguese population. *International journal of legal medicine.* 2011 Mar;125:235-43.5.
- Pérez-Mongioli D, Teixeira A, Caldas IM.** The radiographic visibility of the root pulp of the third lower molar as an age marker. *Forensic science, medicine, and pathology.* 2015 Sep;11:339-44.
- Garamendi PM, Landa MI, Botella MC, Alemán I.** Forensic age estimation on digital x-ray images: medial epiphyses of the clavicle and 1st rib ossification in relation to chronological age. *J Forensic Sci.* 2011;56:S3-S12.
- Alex A, Mohanraj KG.** Morphological and morphometrical analysis of typical cervical vertebrae and their clinical implications. *Drug Invention Today.* 2019 Sep 15;12(9).
- Dharman S.** Assessment of Mandibular Condylar Morphology Using Digital Orthopantomogram in Chennai Population. *Indian Journal of Forensic Medicine & Toxicology.* 2020 Jul 1;14(3).
- Demirjian A, Goldstein H, Tanner JM (1973)** A new system of dental age.
- Ravikumar H, Arthanari A.** Dental Age Estimation of Upper Left Third Molar (28) Using Willems Method. *Journal of Research in Medical and Dental Science.* 2022 Jan;10(1):366-70.
- Kvaal SI, Kolltveit KM, Thomsen IO, Solheim T.** Age estimation of adults from dental radiographs. *Forensic science international.* 1995 Jul 28;74(3):175-85.
- Olze A, Pynn BR, Kraul V, Schulz R, Heinecke A, Pfeiffer H, Schmeling A.** Studies on the chronology of third molar mineralization in First Nations people of Canada. *International journal of legal medicine.* 2010 Sep;124:433-7.
- Timme M, Timme WH, Olze A, Ottow C, Ribbecke S, Pfeiffer H, et al.** The chronology of the radiographic visibility of the periodontal ligament and the root pulp in the lower third molars. *Sci Justice* 2017;57(4):257-61.
- Guo YC, Wang YH, Olze A, Schmidt S, Schulz R, Pfeiffer H, Chen T, Schmeling A.** Dental age estimation based on the radiographic visibility of the periodontal ligament in the lower third molars: application of a new stage classification. *International Journal of Legal Medicine.* 2020 Jan;134:369-74.
- Sequeira CD, Teixeira A, Caldas IM, Afonso A, Pérez-Mongioli D.** Age estimation using the radiographic visibility of the periodontal ligament in lower third molars in a Portuguese population. *Journal of clinical and experimental dentistry.* 2014 Dec; 6(5):e546.
- Vora S, Kardjokar F, Sansare K, Patankar S.** Age estimation based on radiographic visibility of periodontal ligament surrounding mandibular third molars-A retrospective study. *J Forensic Sci & Criminal Inves.* 2019;11(5):1-4.
- Nandita R, Arthanari A.** OPG and CBCT-A More Reliable Source for Human Identification? Perception Based Web Survey among Dentist. *Journal of Research in Medical and Dental Science.* 2022 Jan;10(1):120-8.
- Bosmans N, Ann P, Aly M, Willems G.** The application of Kvaal's dental age calculation technique on panoramic dental radiographs. *Forensic SciInt* 2005;153(2-3):208-12.

- 19. Agarwal N, Ahuja P, Sinha A, Singh A.** Age estimation using maxillary central incisors: A radiographic study. *J Forensic Dent Sci* 2012;4(2):97-100.
- 20. Sequeira CD, Teixeira A, Caldas IM, Afonso A, Pérez-Mongioli D.** Age estimation using the radiographic visibility of the periodontal ligament in lower third molars in a Portuguese population. *Journal of clinical and experimental dentistry*. 2014 Dec; 6(5):e546.
- 21. Demirjian A, Goldstein H, Tanner JM.** A new system of dental age assessment. *Hum Biol* 1973;45(2):211-27.
- 22. Karaarslan B, Karaarslan ES, Ozsevik AS, Ertas E.** Age estimation for dental patients using orthopantomographs. *European journal of dentistry*. 2010 Oct;4(04):389-94.
- 23. Garamendi P, Landa MI, Ballesteros J, Solano MA.** Reliability of the methods applied to assess age minority in living subjects around 18 years old: a survey on a Moroccan origin population. *Forensic science international*. 2005 Nov 10;154(1):3-12.
- 24. Orhan K, Ozer L, Orhan AI, Dogan S, Paksoy CS.** Radiographic evaluation of third molar development in relation to chronological age among Turkish children and youth. *Forensic science international*. 2007 Jan 5;165(1):46-51.

