

Role of Hybrid Reconstruction Ladder in Management of Necrotizing Fasciitis

Dhira Shobith Munipati¹, Ravi Kumar Chittoria², Barath Kumar Singh. P³

How to cite this article:

Dhira Shobith Munipati, Ravi Kumar Chittoria, Barath Kumar Singh. P/Role of Hybrid Reconstruction Ladder in Management of Necrotizing Fasciitis/International Physiology.2023;11(1):9-14.

Author Affiliation: ¹Junior Resident, ²Professor & Head, ³Senior Resident, Department of Plastic Surgery, Jawaharlal Institute of Postgraduate Medical Education and Research, Pondicherry 605006, India.

Corresponding Author: Ravi Kumar Chittoria, Professor & Head, Department of Plastic Surgery, Jawaharlal Institute of Postgraduate Medical Education and Research, Pondicherry 605006, India.

E-mail: drchittoria@yahoo.com

Received on: 09.12.2022

Accepted on: 12.01.2023

Abstract

Necrotizing fasciitis is an infection of subcutaneous tissue and fascia which may spread rapidly to deeper tissue and surrounding tissue which may cause damage to the tissue and present as a localized infection and fulminant septic shock with high mortality rate. Necrotizing fasciitis will undergo extensive wound debridement of the necrotic tissue which may create huge raw area with severe morbidity to the patient. A multidisciplinary team has successfully adopted advanced reconstructive methods combined with modalities from regenerative medicine to enhance the results of difficult reconstruction. These procedures, known as "Hybrid reconstruction ladder," combine conventional reconstruction techniques with regenerative medicine applications. This review article provides a summary of the benefits of using a hybrid reconstruction ladder to create a healthy wound bed and reconstruction in a case of necrotizing fasciitis

Keywords: Hybrid Reconstruction Ladder, Necrotizing Fascitis, Regenerative Medicine, Management.

INTRODUCTION

Necrotizing fasciitis is an infection of subcutaneous tissue and fascia which may spread rapidly to deeper tissue and surrounding tissue which may cause damage to the tissue and present as a localized infection and fulminant septic shock with high mortality rate.¹ Necrotizing fasciitis will undergo extensive wound debridement of the

necrotic tissue which may create huge raw area with severe morbidity to the patient. Due to large defects created by necrotising infection and serial debridement, hybrid reconstruction ladder gives a promising alternative for faster wound healing. The hybrid reconstruction model (Fig. 1) aids in maximizing the function while minimizing the disability and morbidity associated with traditional reconstruction. This review article provides a summary of the benefits of using a hybrid reconstruction ladder to create a healthy wound

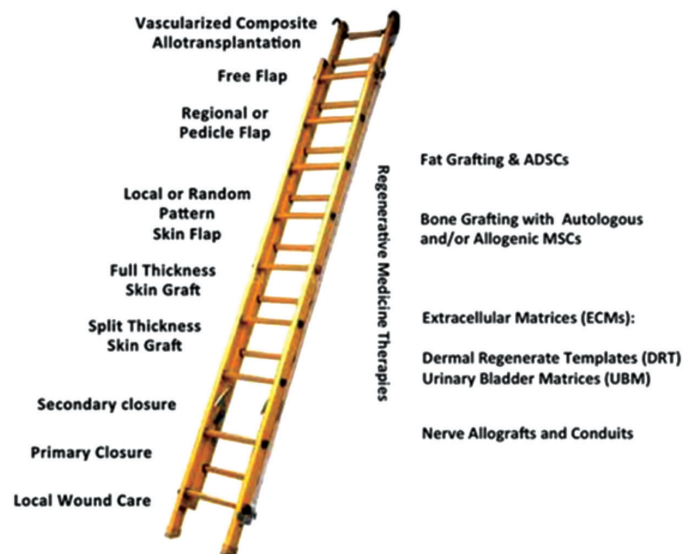

Fig. 1: Hybrid reconstruction ladder.

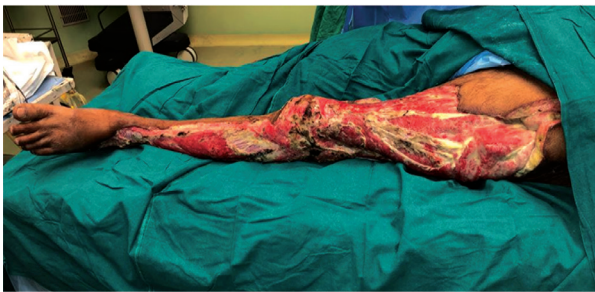

Fig. 2: Wound at Presentation.

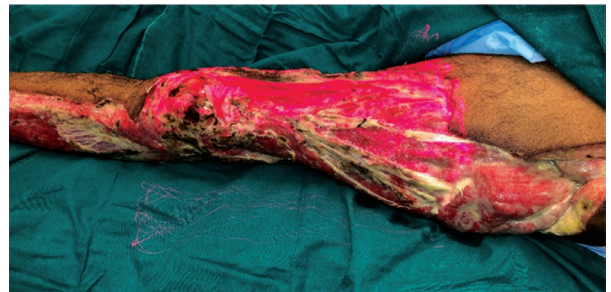


Fig. 3: Low-level laser therapy application.

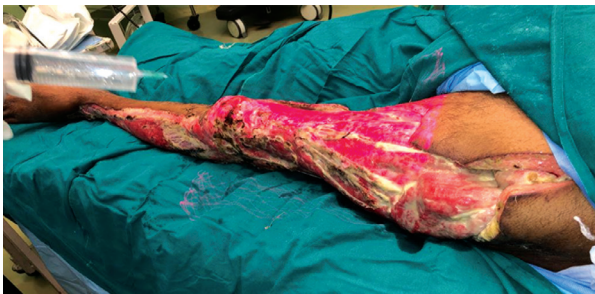

Fig. 4: 25 % Dextrose as prolotherapy.

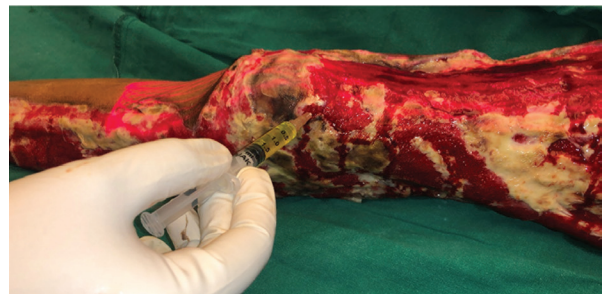

Fig. 5: Autologous Platelet Rich Plasma (APRP).

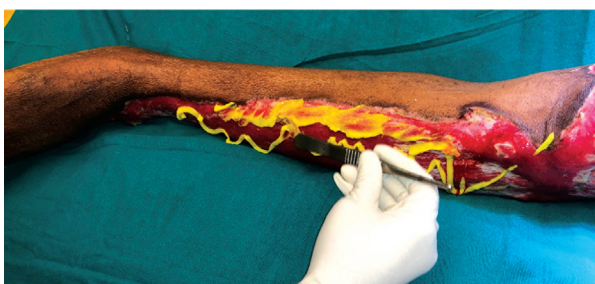

Fig. 6: Sucralfate application.

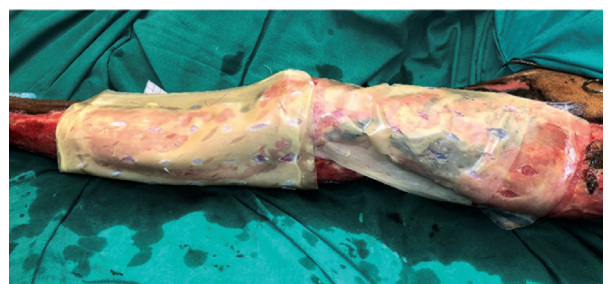


Fig. 7: Tri-layer Scaffold application (human amniotic membrane, dry collagen, silicone layer).

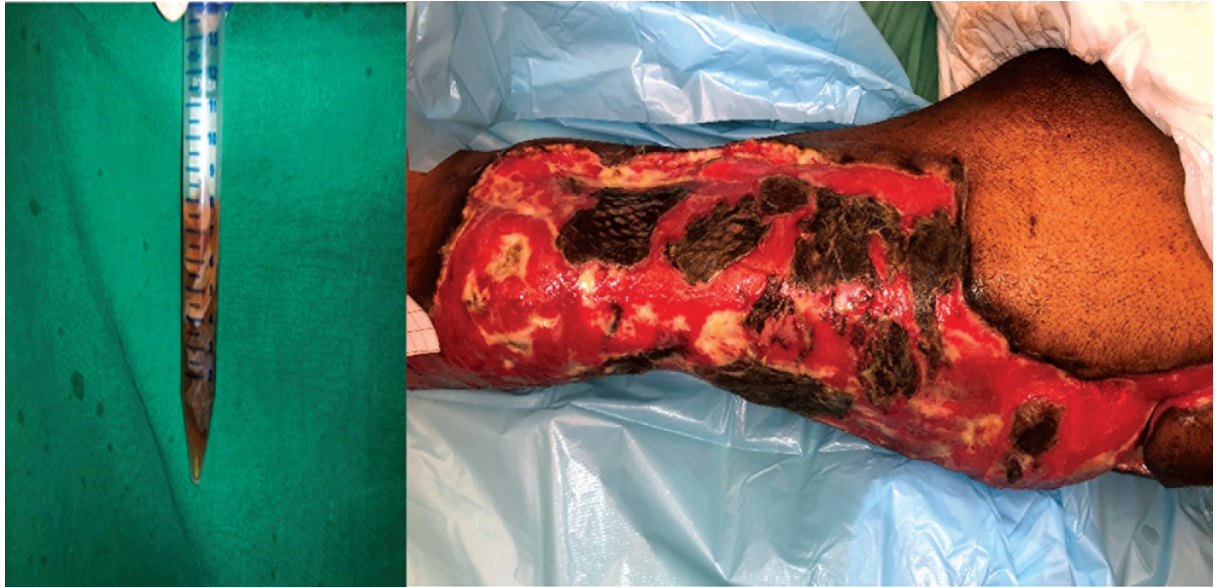

Fig. 8: Allograft application.

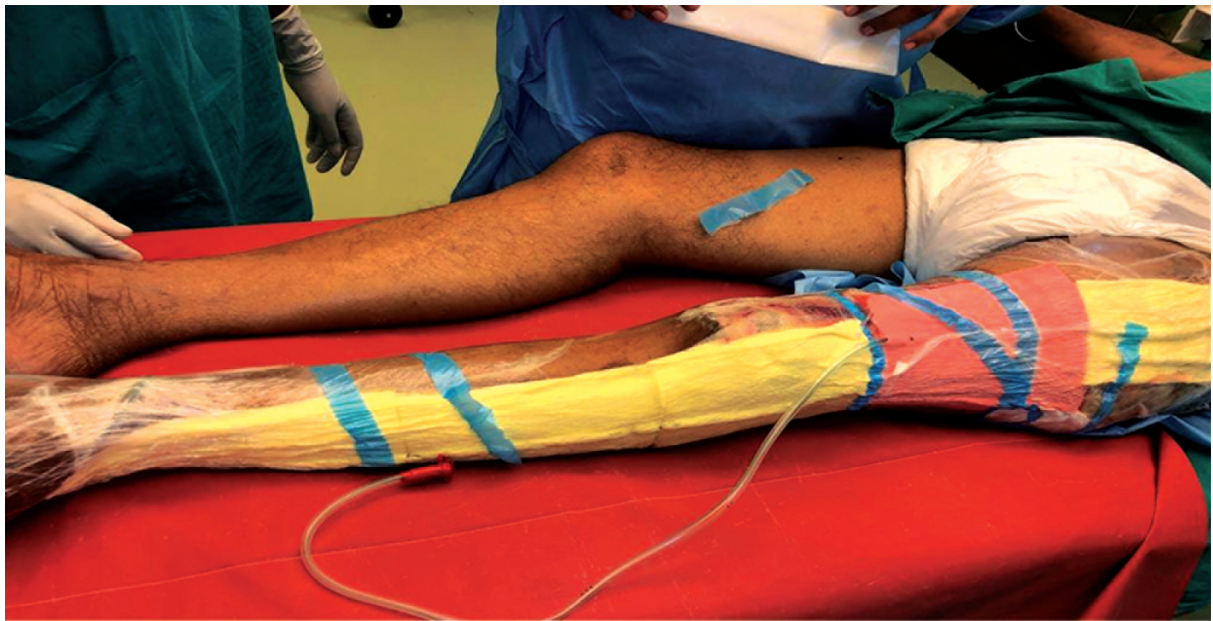

Fig. 9: Negative pressure wound therapy.

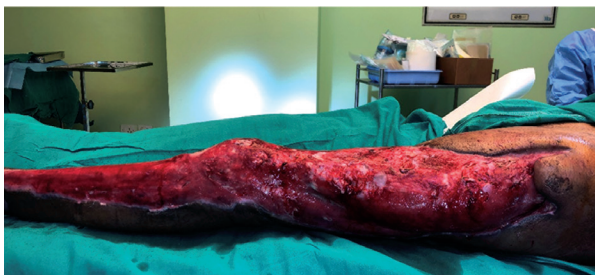

Fig. 10: Healthy wound bed

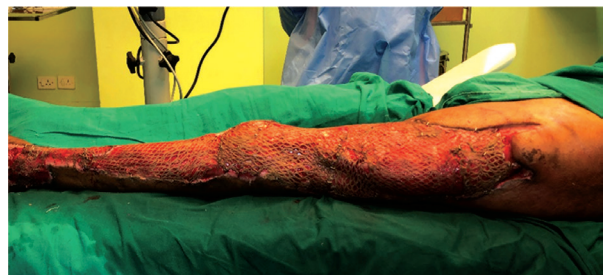

Fig. 11: Split skin grafting done

bed and reconstruction in a case of necrotizing fasciitis

MATERIALS AND METHODS

This study was conducted in the department of plastic surgery in a tertiary care center after obtaining the departmental ethical committee approval. Informed written consent was taken from the patient. The study is a prospective observational type done on a 60-year-old male with known co-morbidities including hypertension & coronary artery disease with ejection fraction of 25%. Patient presented with raw area (fig. 2) over left lower limb & perineum of one month duration. He was apparently well one month back when he developed multiple blebs over left lower limb & perineum which ruptured leaving raw area with rapid progression of wound infection with foul smelling discharge. He was diagnosed with clinically as a case of necrotizing fasciitis. He underwent multiple debridement in general surgery department after that he was referred to department of plastic surgery for further wound care. There are various modalities of regenerative therapies for wound care. Written informed consent was obtained from both the relatives and the patient. The wound bed was prepared with regenerative therapies to improve the healthy granulation tissue. Hydro jet debridement done to remove the unhealthy slime layer over the granulation tissue. Low level laser therapy, Prolotherapy, Autologous platelet rich plasma, Scaffold application, cyclical negative pressure wound therapy, Low level laser therapy, sucralfate application, allograft application (Fig. 3-9) was used in the preparation of wound bed and for better flap survival. The allograft skin was taken from the traumatic amputated upper limb in emergency from another patient and was stored. The graft was kept in tissue culture medium at 4 degrees Celsius and transferred to the recipient operation theatre. Fresh skin allograft was applied over the patient's wounds. The patient responded well to the allografting and did not develop hypovolemia, electrolyte abnormalities, or any wound infection during the course of treatment. After the wound bed preparation (Fig. 10), split skin graft from the right thigh was planned. Postoperatively skin graft was given low level laser therapy, Autologous platelet rich plasma (APRP) injection to improve the take of the skin graft.

RESULTS

In our case with the application of hybrid reconstruction ladder³, the wound bed was prepared effectively and reconstruction was done (fig. 11). The graft uptake was good. Patient was discharged successfully. No complications were noted.

DISCUSSION

Necrotizing fasciitis is a rare but life-threatening condition, with a high mortality rate (median mortality 32.2%) that approaches 100% without treatment. Numerous conditions are associated with this pathology, such as diabetes mellitus, immunosuppression, chronic alcohol disease, chronic renal failure, and liver cirrhosis, which can be conducive to the rapid spread of necrosis, and increase in the mortality rate. The diagnosis of NF is difficult and the differential diagnosis between NF and other necrotizing soft tissue infections more so. However, the clinician should do their utmost to secure the diagnosis of NF, as a delay in diagnosis can be fatal, and septic shock is inevitable if the disease remains untreated. The characteristic of NF is the clinical status change over time.^{1,2} The early clinical picture includes erythema, swelling, tenderness to palpation, and local warmth; once the infection develops, the infection site presents skin ischemia with blisters and bullae. The diagnosis of NF can be secured faster with the use of laboratory based scoring systems, such as the LRINEC score or the FGS score, especially in cases of Fournier's gangrene. However, the diagnosis is definitely established by performing explorative surgery at the infected site. Management of the infection begins with antibiotic treatment. In the majority of cases with NF (70–90%) the reasonable pathogens are two or more, suggesting the use of broad-spectrum antibiotics. The value of antibiotic treatment in NF is relatively low, and early and aggressive drainage and debridement is required. In NF of the extremities, the clinician should consider amputating the infected limb, although this will not reduce the risk of mortality. Finally, postoperative management of the surgical wound is important, along with proper nutrition of the patient.²

The reconstructive ladder was a term coined by plastic and reconstructive surgeons to describe

levels of increasingly complex management of soft tissue wounds. Theoretically, the surgeon would utilize the lowest part of the ladder that is, the simplest reconstruction technique to address a clinical reconstructive problem. The reconstructive surgeon would move up the ladder as a more complex or suitable method was required for a given reconstruction problem.³⁻⁵ In this case as the patient is a known case of Pressure sore involving bilateral gluteal region. A hybrid reconstructive ladder that augments the traditional reconstructive ladder with regenerative medicine modalities helps in improving unhealthy wound for better flap survival. There were improved outcomes at each step on the reconstruction ladder and these modalities may allow for the expansion of indications for each step on the reconstruction ladder. The reconstructive grid⁵ is a dynamic construct that takes into account the multiple reconstructive options available to the plastic surgeon. It also takes into consideration factors that help the reconstructive surgeon determine the best possible option to achieve the three reconstruction goals, namely, form, function, and aesthetics.⁶ The factors that aid the judgment of a reconstruction specialist, including wound complexity, surgeon skill, resources (and technology) available, and patient requests, form the boundaries of the reconstructive grid. The study effectively employed dermal regenerates, soft tissue regeneration techniques, biologic scaffolds in reconstruction. Low Level Laser Therapy (LLLT) is one of the proposed modalities to improve wound healing and scar quality. LLLT is claimed to increase collagen synthesis, decrease inflammation and has a positive impact on scar remodeling.⁷ Dry collagen was used as a scaffold for tissue regeneration of the wound bed for further intervention.⁸ Prolotherapy believe that the injection of hypertonic dextrose causes cell dehydration and osmotic rupture at the injection site that leads to local tissue injury that subsequently induces granulocyte and macrophage migration to the site, with release of the growth factors and collagen deposition.⁹ In vitro studies have shown that even concentrations as low as 5% dextrose have resulted in the production of several growth factors critical for tissue repair. Some of these growth factors include PDGF, TGF- β , EGF, b-FGF, IGF-1, and CTGF. Negative Pressure Wound therapy (NPWT) involve removal of exudates and infectious materials and contraction of wound margin. NPWT has been shown to be safe and effective in post debridement wounds.¹⁰ Hence NPWT was started, and size of the wound was measured at the time of change of dressing.

Platelets act as regulators of inflammation, angiogenesis, cell migration, and proliferation with the release of various growth factors and anti-inflammatory cytokines which is thought to help in faster and better healing of the wounds.¹¹ Autologous platelet rich plasma (APRP) has growth factors which when injected in the wound site or sprayed, act at the intracellular level to bring about cell proliferation and healing of a wound.¹²

The allograft limits wound infection and prevents protein, fluid and electrolyte loss from the wound decreasing the energy spent by the patient. It also reduces pain, improving the general welfare and psychological status of the patient and conserves autograft.¹³ The allograft skin has been used only for the cover of extensive burns wounds for wound bed preparation. Snyder et al. reported the use of allograft for the treatment of diabetic, venous, arterial, post traumatic, post scleroderma ulcers etc. The benefits noted by him include a substantial decrease in wound infection, desiccation and patient symptoms such as pain.

CONCLUSION

Wounds which are difficult to reconstruct and healing are approached effectively with hybrid reconstructive ladder. It helps in fastening the healing rate and the patient has good compliance with the regenerative therapy. The regenerative medicine plays a major role in the hybrid reconstructive ladder and it helps in rescue the patients when the reconstructive options for the patients are limited. Regenerative therapies provide the healthy environment for improving the survival of the flap.

Conflicts of interest: None

Authors' contributions: All authors made contributions to the article

Availability of data and materials: Not applicable

Financial support and sponsorship: None

Consent for publication: Not applicable

REFERENCES

1. Bonne SL, Kadri SS. Evaluation and Management of Necrotizing Soft Tissue Infections. *Infect Dis Clin North Am* 2017; 31:497.
2. Zaroff LI, Mills W, Duckett, JW, et al. Multiple uses of viable cutaneous homografts in the burned

- patient. *Surgery* 59:368, 1966.
3. Wong CJ, Niranjan N. Reconstructive stages as an alternative to the reconstructive ladder. *Plast Reconstr Surg.* 2008;121: 362e-363e.
 4. Erba P, Ogawa R, Vyas R, Orgill D. The reconstructive matrix: A new paradigm in reconstructive plastic surgery. *Plast Reconstr Surg.* 2010;126:492-298.
 5. Mohapatra, Devi Prasad M.Ch.; Thiruvoth, Friji Meethale M.Ch. Reconstruction 2.0: Restructuring the Reconstructive Ladder, Plastic and Reconstructive Surgery: March 2021 - Volume 147 - Issue 3 - p 572e-573e.
 6. Vedder NB, Wei FC, Mardini S, eds. Problem analysis in reconstructive surgery: Reconstructive ladders, elevators, and surgical judgment. In: *Flaps and Reconstructive Surgery*. 2017;2nd ed. Toronto: Elsevier; 1-5.
 7. Saurab gupta et al. Effect of Low-Level Laser Therapy (LLLT) On the Severity of Post-Burn Immature Scars: A Randomized Control Study. *International Journal of Clinical and Diagnostic Research* Volume 8, Issue 1, Jan-Feb 2020.
 8. Turner NJ, Badylak SF. Biologic scaffolds for musculetendinous tissue repair. *Eur. Cell Mater.* 25, 130-143 (2013).
 9. Freeman JW, Empson YM, Ekwueme EC, Paynter DM, Brolinson PG. Effect of prolotherapy on cellular proliferation and collagen deposition in MC3T3-E1 and patellar tendon fibroblast populations. *Transl Res* 2011; 158:132-139.
 10. Tenenhaus M, Rennekampff HO. Surgical advances in burn and reconstructive plastic surgery: new and emerging technologies. *Clin. Plast. Surg.* 39(4), 435-443 (2012).
 11. Borgquist O, Ingemansson R, Malmjö M. Wound edge microvascular blood flow during negative-pressure wound therapy: examining the effects of pressures from 10 to 175 mmHg. *Plast Reconstr Surg.* (2010) 125:502- 9.
 12. Salazar-Álvarez AE, Riera-del-Moral LF, García-Arranz M, Alvarez-García J, Concepción-Rodríguez NA, Riera-de-Cubas L: Use of platelet-rich plasma in the healing of chronic ulcers of the lower extremity. *Actas Dermosifiliogr* 2014;105: 597-604.
 13. Greenleaf G, Hansbrough JF. Current trends in the use of allograft skin for patients with burn and reflections on the future of skin banking in the United States. *J Burn Care Rehabil.* 1994; 15(5):428-431.
-