

Role of Closed Incision Negative Pressure Wound Therapy in Preventing Abnormal Scarring

Hari Narendhiran NE¹, Ravi Kumar Chitoria², Jacob Antony Chakiath³

How to cite this article:

Hari Narendhiran NE, Ravi Kumar Chitoria, Jacob Antony Chakiath/Role of Closed Incision Negative Pressure Wound Therapy in Preventing Abnormal Scarring/ J Surg.Nurs.2023;12(2):61-63.

ABSTRACT

Negative pressure wound therapy has revolutionised the way in which acute and chronic wounds are treated. The incision site is usually covered with an occlusive or semi occlusive covering after primary wound closure. It is thought that using closed incisional negative pressure wound therapy on surgical wounds improves wound healing by better distribution of shear stresses on wound edges and promoting the evacuation of wound fluids such as subcutaneous seroma and hematoma.

Keywords: Abnormal Scarring; Closed Incisional; Negative Pressure; Wound; Burn.

INTRODUCTION

Negative pressure wound therapy has revolutionised the way in which acute and chronic wounds are treated.^{1,2} The benefits of closed incisional negative pressure wound therapy (ciNPWT) on surgical wounds after vascular surgery, hip replacement, or amputations have been proven in several investigations.³⁻⁵ It is thought that using ciNPWT on surgical wounds improves wound healing by better distributing shear stresses on wound edges and promoting the evacuation of wound fluids such as subcutaneous seroma and hematoma.⁶⁻⁸ Furthermore, ciNPWT minimises wound dehiscence and possibility of germ entry

through its protective sealing.⁶ In this study, we are sharing our experience of using ciNPWT in promoting wound healing and preventing abnormal scarring.

MATERIALS AND METHODS

This study was conducted in the department of Plastic Surgery at tertiary care centre in South India after getting the departmental ethical committee approval. Informed written consent was taken from the patient. A 20 year old Male with post-burn contracture of left little finger with subluxation of left 5th metacarpophalangeal joint. The contracture was due to burns which occurred when he was 1.5 years old due to contact with burning firewood. It caused significant deformity and functional limitation of the left little finger. Contracture release was done. Full thickness skin graft was from left groin and applied over the finger. Following this, Closed Incision Negative Pressure Wound Therapy was done to the donor site.

RESULTS

The donor site healed completely with minimal scar formation.

Author Affiliation: ¹Intern, ²Professor, ³Senior Resident, Department of Plastic Surgery, Jawaharlal Institute of Postgraduate Medical Education and Research, Pondicherry 605006, India.

Corresponding Author: Ravi Kumar Chitoria, Professor, ³Senior Resident, Department of Plastic Surgery, Jawaharlal Institute of Postgraduate Medical Education and Research, Pondicherry 605006, India.

E-mail: drchittoria@yahoo.com

Received on: 14/04/2023

Accepted on: 25/04/2023

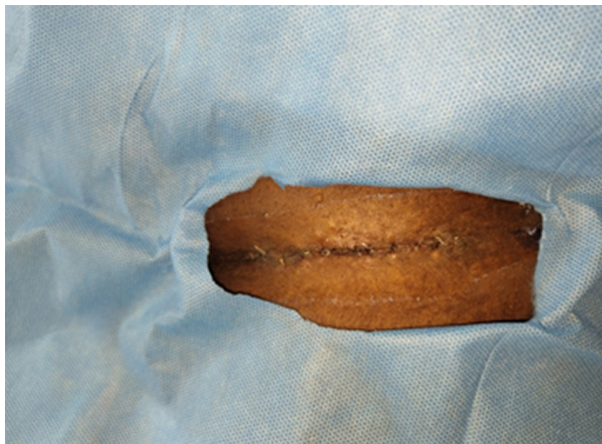

Fig. 1: Donor site skin closure

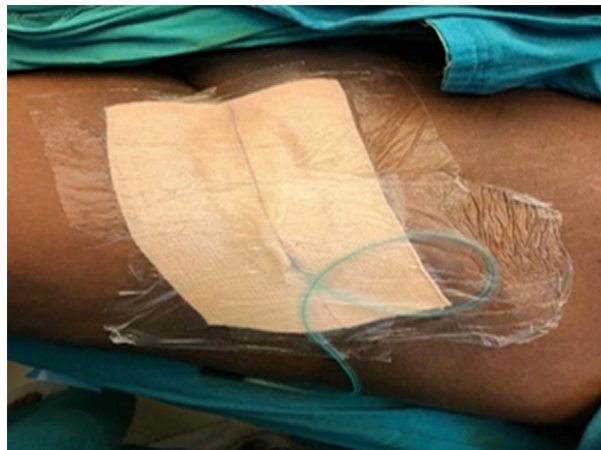


Fig. 2: Application of CiNPWT at donor wound site

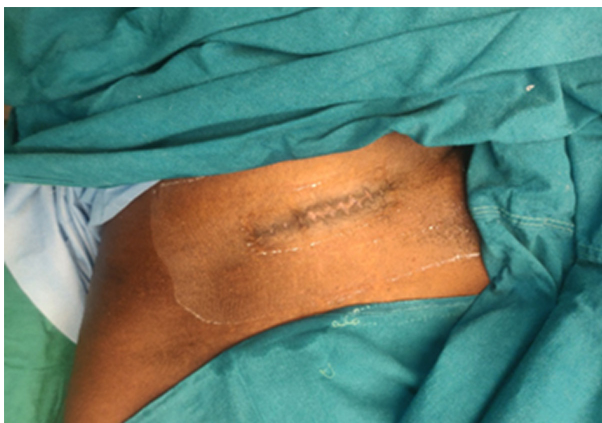


Fig. 3- Donor site healed well

DISCUSSION

Negative pressure wound vacuum therapy (NPWVT) is a well known treatment for infected or burst open surgical incisions. Its usage in closed surgical sites has recently become the topic of new investigation.

Macroscopic findings include shortening of the time of wound closure and maintaining a moist wound environment; reduces oedema and seroma formation. It also helps in mending tissues.

Microscopic effects include increased VEGF, IL.⁸ VEGF gradient increases toward the wound and triggers angiogenesis. Oriented toward the wound compared to fewer tortuous new vessels observed in controls; stimulates cell proliferation through micro-deformation; decreases local blood flow in those tissues in closest proximity to the ROCF; changes the colonizing flora of the wound, may increase or have no effect on overall bacterial load; increased neovascularization.⁶

There are many modes of application of negative pressure: continuous, intermittent, and cyclic.

Continuous mode uses a constant sub-atmospheric pressure of 125 mmHg; intermittent mode uses 5 minutes of -125 mmHg followed by 2 minutes of 0 mmHg. In cyclic mode, pressure oscillates between 0 and -125 mmHg.⁷ Cyclic mode is found to be less painful and more effective as a rapid rise in pressure is prevented.^{8,9} But both intermittent and cyclic modes require specific machines for generation and hence are not feasible to use with classical suction devices. So in most cases, continuous mode NPWT is commonly used.

Sieewart et al, looked at the role of ciNPT in preventing abdominal donor site problems in 300 microsurgical breast reconstructions in a preliminary research.¹⁰ The authors discovered a considerable reduction in wound dehiscence after considering our findings/ ciNPT has been reported to be effective as a prophylactic treatment for the donor site of other flaps, where wound fluid collection is the primary cause of wound complications, allowing suction drains to be removed sooner.^{11,12} Experimental studies have shown that ciNPT reduces tension across the surgical incision, improving local blood flow and hence minimizing dead space and wound fluid collection.

With regard to our study, we demonstrated that ciNPT is a cornerstone to improve scar quality and the esthetic scar appearance. As this a single case study, further large scale randomized control study is required to comment on its efficacy.

CONCLUSION

Closed Incision Negative Pressure Wound Therapy is found to be effective in preventing abnormal scarring by accelerating cell proliferation and wound healing processes.

REFERENCES

1. Agarwal A. *Plast Reconstr Surg.* 2019 Jan;143(1S Management of Surgical Incisions Utilizing Closed-Incision Negative-Pressure Therapy):21S-26S.
2. Jeyakumar, P., Hussain, A. T., &Ahamed, A. R. (2018). Reconstruction of Extensive Post-ElectricBurnLowerlimb defect Defects With Exposed Bones – A Study of 12 Cases. *Annals of Plastic Surgery.*
3. Matatov T, Reddy KN, Doucet LD, Zhao CX. Experience with a new negative pressure incision management system in prevention of groin wound infection in vascular surgery patients. *J VascSurg* 2011;57(3):791-5.
4. Masden D, Goldstein j, Endara M, Xu K, Steinberg J, Attinger C. Negative pressure wound therapy for at-risk surgical closures in patients with multiple comorbidities. *Ann Surg* 2012;255(6):1043-7.
5. Stannard JP, Volgas DA, McGwin G, Stewart RL, Obremskey W, Moore T, et al. Incisional negative pressure wound therapy after high-risk lower extremity fractures. *J Orthop Trauma* 2012;26(1):37-42.
6. Horch RE. Incisional negative pressure wound therapy for high-risk wounds. *J Wound Care* 2015;24:21-8.
7. Willy C, Agarwal A, Andersen CA, De Santis G, Gabriel A, Guerra OM, et al. Closed incision negative pressure therapy: international multidisciplinary consensus recommendations. *Int Wound J* 2016;14(2) :385-98.
8. Suh H, Lee AY, Park q, Hong JP. Negative pressure wound therapy on closed surgical wounds with dead space animal study using a swine model. *Ann PlastSurg* 2016;76(6):717-22.
9. Hyldig N, et al. (2016). Meta-analysis of negative-pressure wound therapy for closed surgical incisions. *British Journal of Surgery.* 2016: 103; 477-486.
10. Siegwart LC, Sieber L, Fischer 5, Maraka 5, Kneser U, Kotsougiani-Fischer D. Influence of closed incision negative-pressure therapy on abdominal donor-site morbidity in microsurgical breast reconstruction. *Microsurgery* 2020:1-8.
11. Tyack Z, Simons M, Spinks A, Wasiak J. A systematic review of the quality of burn scar rating scales for clinical and research use. *Burns* 2012;38(1):6-18.
12. Gomoll AH, Lin A, Harris MB. Incisional vacuum-assisted closure therapy. *J Orthop Trauma.* 2006 Nov-Dec;20(10):705-9. doi: 10.1097/01.bot.0000211159.98239.d2. PMID: 17106382.

