

Role of Hybrid Reconstruction Ladder in Scald Burn

Kada Sri Vidhul¹, Ravi Kumar Chittoria², Barath Kumar Singh P³

How to cite this article:

Kada Sri Vidhul, Ravi Kumar Chittoria, Barath Kumar Singh P/Role of Hybrid Reconstruction Ladder in Scald Burn/RFP Journal of Dermatology 2023;8(1):43–47.

ABSTRACT

Burns and other related ailments frequently result in fatalities and disabilities. Children and adults suffer burn cases at a higher rate than other age groups. Contact with hot surfaces and scald burns are the most typical hospital presentations in toddlers under the age of two. Some of the factors include the custom of cooking on the ground or sleeping next to a burning candle. Better outcomes are seen when this sort of burns are treated quickly. In this instance, we discuss the use of a hybrid reconstruction ladder in the treatment of pediatric scald burns.

Keywords: Management; Scald Burn; Hybrid Reconstruction Ladder.

INTRODUCTION

One of the most common causes of illness and mortality in children is burns. Basic understanding of thermal injury is crucial for managing burns in children who present with them. According to a Davis study from 1990, there are 2 million burn cases across the Indian Subcontinent every year. Burn victims make up 40% of those under 15 years old. 90% of kid burn injuries are caused by scalding and hot liquids. At home, open fire areas and the kitchen are typical locations. Plastic and reconstructive surgeons developed the phrase "reconstructive ladder" to characterize stages of progressively

sophisticated care of soft tissue wounds.¹ The simplest reconstruction strategy would be used by the surgeon to solve a clinical reconstructive problem, which is the lowest step on the ladder. Regenerative medicine techniques can be added to the conventional reconstructive ladder using the hybrid reconstructive ladder (fig. 1). We evaluate the function of the hybrid reconstruction ladder in the treatment of pediatric heat burns in this case report.

Materials and Methods

This research was carried out in a tertiary care facility's plastic surgery department. The patient who was the subject of the study provided informed consent. The approval of the departmental scientific committee was gained. It is a non-randomized, non-controlled trial that only has one centre. The patient, a female 2-year-old with no other known comorbidities, had right chest, arm, and forearm second degree deep scald burns that made about 15% of the total burn surface area (fig. 2). A non-cultured keratinocyte graft was applied after the burn lesion was debrided with regenerative therapies such Autologous platelet rich plasma (APRP) (fig.s 3 and 4). For four weeks, APRP was applied once each week. scaffold

Author Affiliation: ¹Junior Resident, ²Senior Resident, ³Professor & Registrar, Department of Plastic Surgery & Telemedicine, Jawaharlal Institute of Postgraduate Medical Education and Research, Pondicherry 605006, India.

Corresponding Author: Ravi Kumar Chittoria, Professor & Registrar, Department of Plastic Surgery & Telemedicine, Jawaharlal Institute of Postgraduate Medical Education and Research, Pondicherry 605006, India.

Email: drchittoria@yahoo.com

Received on: 31.12.2022

Accepted on: 15.01.2023

dressing made of collagen was used (fig. 5). On the wound, negative pressure wound treatment was used (fig. 6). Once a week, low level laser therapy was used for 10 minutes (fig. 7).

Results

The superficial second degree burn wounds recovered quickly. Patient was successfully discharged, and all burn injuries had entirely

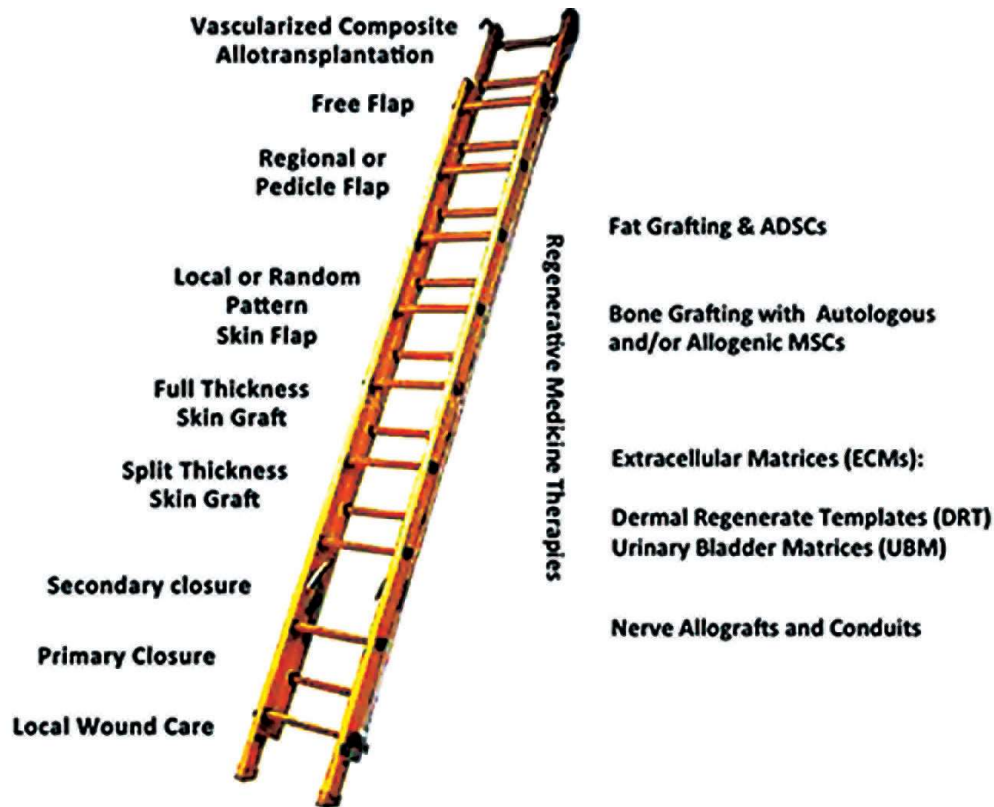

Fig. 1: Hybrid reconstruction ladder

healed (fig. 8). Both the surgical procedure and the recovery period went smoothly.

Discussion

Based on the method of injury, burn wounds can be divided into six different categories: scalds, contact burns, fire, chemical, electrical, and radiation. In this article, the first three forms of burns are discussed. Steam, grease, or liquids can all produce scald burn injuries. Spill and immersion scalds are further categories for liquid burns. Flash burns and flame burns are two types of fire burn injuries. A predictor of outcome can be found in the mechanism of burn injury. For instance, people who suffer from flame burns and electrical burn injuries frequently need to be hospitalized. In contrast, the majority of patients with burns brought on by sun exposure or contact with hot surfaces are treated as outpatients.

Burn injuries are a terrible concern for critical care.

Burns in children continue to be an important global health issue that cause severe morbidity and mortality. It appears that there are considerable physiological and psychological differences between treating these burn injuries in children and adults, despite the similarities in treatment. In comparison to adults, the dermal layer of skin is often thinner in newborns, infants, and children. The danger of hypothermia in children is increased by increased evaporative loss and the requirement for isotonic fluids.

The care of difficult injuries has been altered by hybrid reconstructions, which also provided an expansion of the procedures that can be used to treat composite tissue loss. There is still a need for more study and the creation of tactics to deal with complex tissue loss. Utilizing biologic scaffolds could speed up the healing of wounds.¹ In addition to helping in tissue moulding, APRP is known to encourage the production of collagen, blood vessels, and adipose tissue.^{2,3} This not only aids in the absorption of skin grafts placed but also ensures scarring that is more

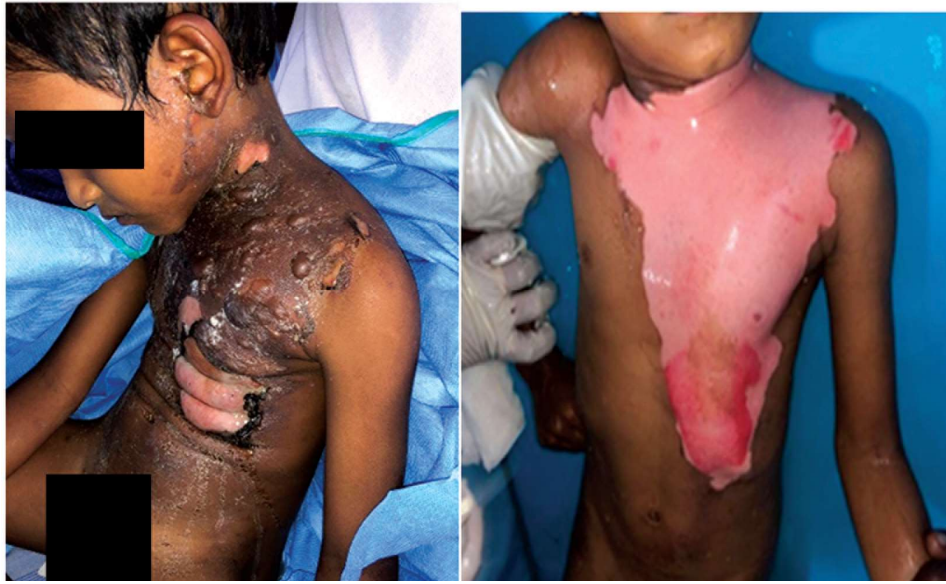

Fig. 2: At the time of presentation

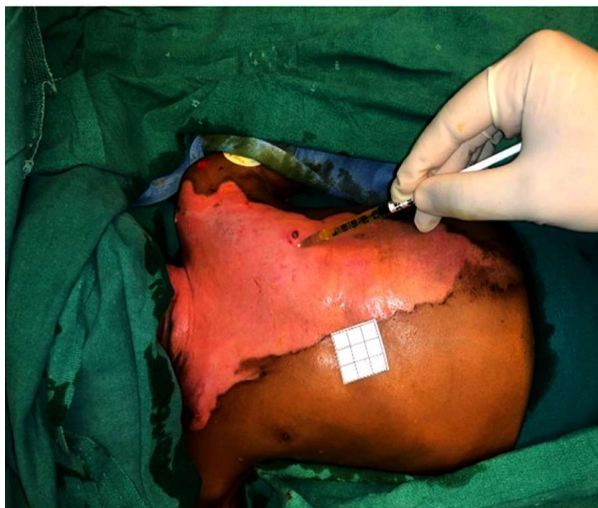


Fig. 3: Autologous platelet rich plasma applied to the burn wound.

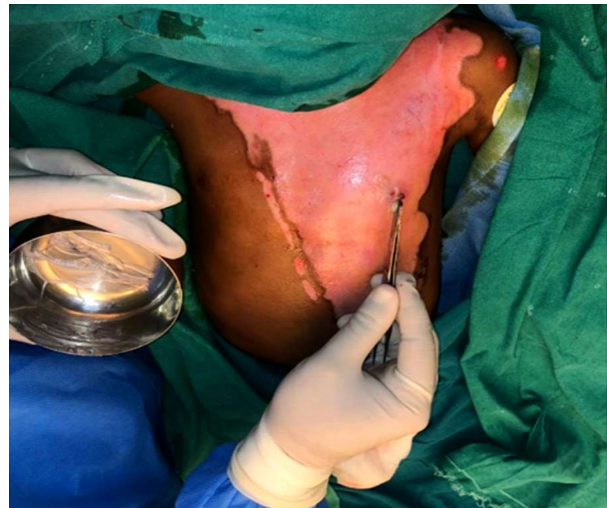

Fig. 4: Application of non-cultured keratinocyte graft (NCKG) over the non-healed areas on day 8

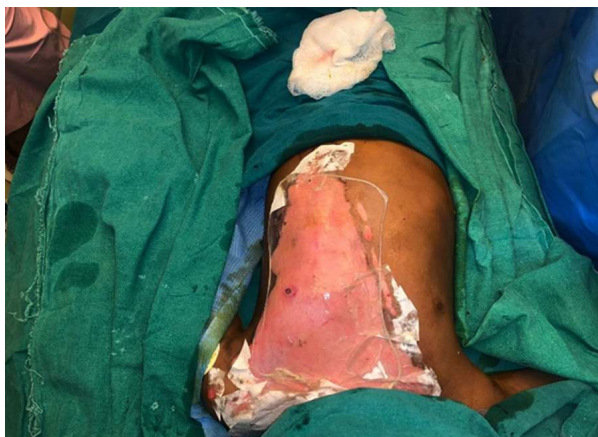

Fig. 5: Application of collagen scaffold dressing

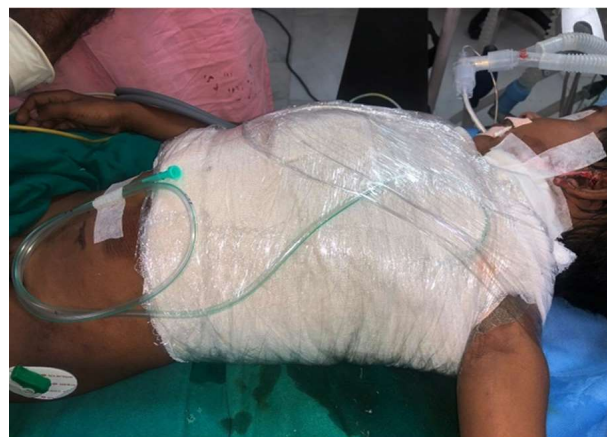

Fig. 6: Negative pressure wound therapy

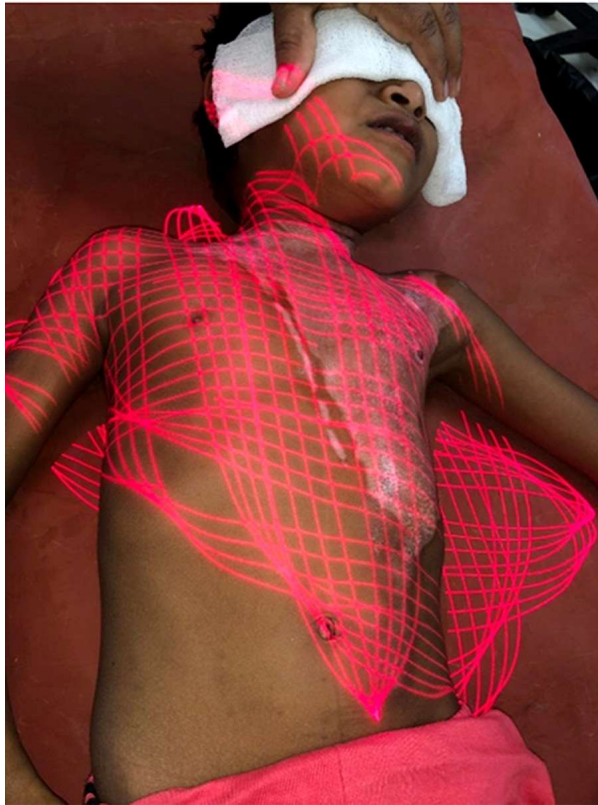


Fig. 7: Low level laser therapy.

aesthetically pleasing.^{4,5}

Topical sucralfate therapy has been shown to be beneficial in treating wounds in studies and rare case reports. In vitro, sucralfate stimulates the development of dermal fibroblasts and keratinocytes while inhibiting the release of interleukin-2 and interferon-gamma from injured skin cells.^{6,7} Sucralfate decreases inflammatory response and encourages mucosal repair through the creation of a physical barrier. Sucralfate also encourages angiogenesis, which hastens the healing of wounds. Basic fibroblast growth factor (bFGF) and epidermal growth factor levels are increased in the wound by sucralfate.⁸ In addition, sucralfate encouraged skin cells to generate IL-6 and PGE2, which benefited in the healing process.⁹

LLLT stimulates tissue regeneration, wound healing, and repair in addition to having analgesic and anti-inflammatory properties.¹⁰ At the cellular level, LLLT promotes cell regeneration, increases collagen production, reduces the development of fibrous tissue, decreases oedema, increases growth factor synthesis, reduces the number of inflammatory cells, reduces the synthesis of inflammatory mediators like substance P, bradykinin, histamine, and acetylcholine, and stimulates the production of nitric oxide. The photobiological effects are influenced

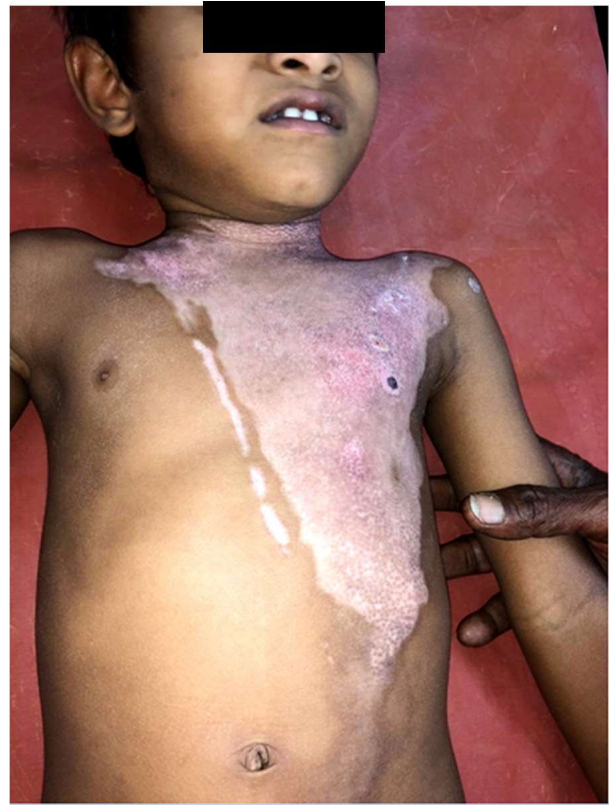

Fig. 8: Healed burn wounds at the time of discharge.

by the LLLT treatment's intensity, wavelength, and duration. LLLT lasers are frequently made of gallium arsenide (Ga-As), gallium aluminium arsenide (Ga-Al), krypton, helium neon (He-Ne), ruby, and argon. It has been used to treat burn wounds, acute and chronic pain, wrinkles, scars, hair loss, and photo rejuvenation of photodamaged skin in addition to wrinkles, scars, and hair loss. As a result of its biostimulatory properties, LLLT has proven to be useful as an adjuvant therapy in the treatment of wounds. Low-level laser therapy (LLLT) can improve and speed up the healing process for burn wounds and also help with scar modulation.¹¹

The literature suggests that the four primary processes by which negative pressure wound therapy works are contraction of the wound, stabilisation of the environment around the wound, drainage of extracellular fluids, and micro deformation at the foam wound interface.¹² It has helped with scar modification and burn wound healing.

Application of cultivated keratinocytes seems to encourage the development of wholesome granulation tissue within the wound bed. When used as a sheet, the graft functions as an occlusive dressing to keep the surrounding area moist and avoid wound dehydration. The overwhelming body of research points to the fact that cultured epidermal allografts do

not last after transplantation indefinitely.¹³ However, it appears that their brief contact with the wound is enough to promote epithelialization, especially when dermal tissue is present in the wound bed. This could be as a result of keratinocytes releasing growth factors that may help with wound healing. In addition, keratinocytes secrete a number of growth factors that aid in the healing of wounds. It is well known that cultured keratinocytes secrete a variety of substances that promote the in vitro development of keratinocytes, fibroblasts, and melanocytes. The factors interleukin-1, additional interleukins, and transforming growth factor alpha have been identified. The origin of these keratinocytes can be either autologous or allogenic.¹⁴ Trypsin or other techniques are used to separate these cells from the skin graft. These are cultivated in the proper conditions after separation to create a sheet. These sheets are applied to the wound as a graft. To aid in the healing process in our situation, we employed autologous keratinocyte cells that were not grown or trypsinized. We saw positive results in the quick epithelialization of the wound from the margins and the healing of scald burn wounds.

Conclusion

Pediatric scald burn patients can be successfully treated using the hybrid reconstruction ladder with regenerative therapies.

Conflicts of interest: None.

Authors' contributions: All authors made contributions to the article.

Availability of data and materials: Not applicable.

Financial support and sponsorship: None.

Consent for publication: Not applicable.

References

1. Tenenhaus M, Rennekampff HO. Surgical advances in burn and reconstructive plastic surgery: new and emerging technologies. *Clin. Plast. Surg.* 39(4), 435-443 (2012).
2. Salazar-Álvarez AE, Riera-del-Moral LF, García-Arranz M, Álvarez-García J, Concepción-Rodríguez NA, Riera-de-Cubas L: Use of platelet-rich plasma in the healing of chronic ulcers of the lower extremity. *ActasDermosifiliogr* 2014; 105:597-604.
3. Picard F, Hersant B, Bosc R, Meningaud JP: Should we use platelet-rich plasma as an adjunct therapy to treat "acute wounds", "burns", and "laser therapies": a review and a proposal of a quality criteria checklist for further studies. *Wound Repair Regen* 2015; 23:163-170.
4. Cobos R, Aizpuru F, Parraza N, Anitua E, Orive G: Effectiveness and efficiency of platelet rich plasma in the treatment of diabetic ulcers. *Curr Pharm Biotechnol* 2015; 16:630-634.
5. Tumino G, Masuelli L, Bei R, et al. Topical treatment of chronic venous ulcers with sucralfate: a placebo controlled randomized study. *Int J Mol Med.* 2008; 22:17.
6. Gupta PJ, Heda PS, Shrirao SA, et al. Topical sucralfate treatment of anal fistulotomy wounds: a randomized placebo-controlled trial. *Dis Colon Rectum.* 2011; 54:699-704.
7. Burch R, McMillan B. Sucralfate induces proliferation of dermal fibroblasts and keratinocytes in culture and granulation tissue formation in full-thickness skin wounds. *Agents Actions.* 1991; 34:229-231.
8. Folkman J, Szabo S, Shing Y. Sucralfate affinity for fibro-blast growth factor. *J Cell Biol.* 1990;111: A223.
9. Farivar S, Malekshahabi T, Shiari R. Biological Effects of LowLevel Laser Therapy. *J Lasers Med Sci* 2014; 5 (2):58-62.
10. Andrade F, Rosana C, Manoel F. Effects of low-level laser therapy on wound healing. *Rev. Col. Bras. Cir.* 2014 Apr; 41(2):129-133.
11. Avci P, Gupta A, Sadasivam M, Vecchio D, Pam Z, Pam N, et al. Low-level laser (light) therapy (LLLT) in skin: stimulating, healing, restoring. *SeminCutan Med Surg.* Panayi AC, Leavitt T, Orgill DP. Evidence based review of negative pressure wound therapy. *World J Dermatol.* 2017;6:1-16.
12. Wynn M, Freeman S. The efficacy of negative pressure wound therapy for diabetic foot ulcers: a systematised review. *J Tissue Viability.* 2019;28 :152-160.2013; 32(1):41-510.
13. Shukla VK, Tiwary SK, Barnwal S, Gulati AK, Pandey SS. Effect of autologous epidermal cell suspension transplantation in chronic nonhealing wounds: a pilot study. *Can J Surg.* 2010;53(1):6-10.
14. Gauthier Y, Benzekri L. Non-cultured epidermal suspension in vitiligo: From laboratory to clinic. *Indian J Dermatol VenereolLeprol* 2012;78: 59-63.

