

■ ORIGINAL ARTICLE

# To assess the Anatomical Variations of Lingual Foramen and its Bony Canals Using CBCT in Relation to Age and Gender

<sup>1</sup>Jayant Kumar, <sup>2</sup>Manu Dhillon, <sup>3</sup>Hemant Sawhney, <sup>4</sup>Madhulika Tomar, <sup>5</sup>Richa Mishra

## ABSTRACT

**CONTEXT:** This retrospective study was conducted in the Department of Centre for Advanced Imaging, I.T.S. Dental College. The sampling method was consecutive and the sample size of 100 CBCT scans were included in which 50 scans were of male patients and 50 of female patients. Scans covering mandibular anterior region for preoperative implant placement planning were included. Scans of the patients within the age group of 20-60 years and those who were referred to the department for mandibular anterior region scan and scans done using the same acquisition parameters were included in the study. Different observations were assessed on multiple sections and the section which had greatest dimensions was selected for variables measurement. The effect of patient age and gender on the dimensional measurements of the various anatomical landmark were accessed. **AIM:** To assess the anatomical variations and locations of lingual foramen and its bony canals by using CBCT in relation to age and gender. **MATERIALS AND METHOD:** Through CBCT examinations, 100 patients were carefully examined in the median region of the mandible in order to detect the lingual foramen and their corresponding vascular canals. Their presence, number, position, diameter, morphology and trajectory were established. We also evaluated the effect of patients' age and gender on the dimensional measurements of the anatomical landmark mentioned above. **STATISTICAL ANALYSIS:** The statistical analysis was done using statistical software SPSS version 16.0. comparison of the means of various parameters for categorical and numerical data was done by chi-square and unpaired t test. Inter- observer agreement was assessed with Cohen's kappa test and interclass correlation. **RESULTS:** All of the 100 CBCT scans taken showed the presence of lingual foramen. Of all the participants, 52% of them had two foramina in their images whereas 43% have single foramen and remaining 5% have three foramina. The most common trajectory was downward in 61% of the cases. The mean diameter of lingual foramen canal at buccal end in male and female was 0.42 mm and 0.37mm respectively, average diameter at lingual end in male and female was 0.60 mm and 0.54mm respectively. **CONCLUSIONS:** As the variations were shown in lingual foramen characteristics, is mandatory to be aware of the structures present in anterior mandible to prevent the surgical complications. CBCT appears to be an ideal imaging modality to assess these variations that must be taken into consideration prior to treatment planning. There was also an age and gender related significant difference in the diameter of canal. So, the morphology of lingual foramen and its canals can be used to evaluate the age and gender of an individual which can open a new vista in the field of forensics. **KEY MESSAGE:** CBCT assessment of morphological features of the alveolar bone and locations of nerve canals and foramina in the anterior region of mandible represent useful anatomical information about the inter-foraminal region. This information is a useful guide to the dentist before surgery and also lingual foramen have some morphological variations compared to male and female. This study should be done on larger population in future which can open new vistas in the field of forensics.

### Authors' Credentials:

<sup>1,3</sup>Senior Lecturer, <sup>3</sup>HOD & Professor, Department of Oral Medicine and Radiology, School of Dental Sciences, Sharda University, Greater Noida, Uttar Pradesh 201310, India.

<sup>2</sup>HOD & Professor, Department of Oral Medicine and Radiology, DJ Dental College, Modinagar, Uttar Pradesh 201204, India.

<sup>4</sup>Dental Surgeon, Smile of India Dental and Health care Clinic, Greater Noida, Uttar Pradesh 201016, India.

### Corresponding Author:

Manu Dhillon, HOD & Professor, Department of Oral Medicine and Radiology, DJ Dental College, Modinagar, Uttar Pradesh 201204, India.

### Email:

[drmanudhillon@gmail.com](mailto:drmanudhillon@gmail.com)



### How to cite this article

Jayant kumar. To assess the Anatomical Variations of Lingual Foramen and its Bony Canals Using CBCT in Relation to Age and Gender. Indian J Forensic Med Pathol.2021; 14(3 Special):519-528.

KEYWORDS | Cone beam computed tomography, lingual foramen and lingual canal

---

## INTRODUCTION

---

It is well known that anterior mandible contains several anatomical landmarks such as intra bony vascular canal, which is named the mandibular incisive canal (MIC) and lingual foramen.<sup>1</sup> Interforaminal mandibular region is considered relatively safe for the dental implant treatment.

Knowledge of lingual foramen and their bony canal dimensions and locations are important to be considered during anterior dental surgery (implant placement, genioplastic or grafting procedures) for avoiding various complications.<sup>2,3</sup> There are many unnamed accessory foramina present in the mandible, especially on the lingual side which are variable in their distribution and may be of significance in relation to the effectiveness of local anesthetic solutions administered for dental procedures.<sup>4</sup>

In Sutton's survey of 300 mandibles, the foramen was present in 85% of the mandibles examined and Shiller & Wiswell found a median lingual foramen in 88.9 % in 126 specimens.<sup>4,5</sup>

Ennis demonstrated a foramen located superior to the genial spines. Suzuki and Sakai mentioned that the bony canals of these foramina coursed perpendicular to the inner surface of the mandible. Their reported frequency was 87% for the foramen supraspinosum, 68% for the foramen interspinosum (superior genial spinal foramen) and 26% for the foramen infraspinosum (inferior genial spinal foramen).<sup>6,7,8</sup> McDonnell *et al.*, reported that the foramina are in the midline on the lingual side of the mandible, at or above the genial spines.<sup>9</sup> Only Gahleitner *et al.*, characterized the diameter of the canals and the distance between their foramina openings and the mandibular border.<sup>10</sup>

The foramina located below the genial spines are denoted as inferior genial spinal foramina and contain sometimes the branches of sublingual artery and vein and sometimes the submental vessels and branches of mylohyoid nerve.<sup>11</sup>

Computed tomography (CT) has the ability to evaluate bony structures on the axial, coronal

and sagittal sections. It has low radiation dose and capability of showing coronal, sagittal and axial planes in addition to lower cost for the patient making it a preferred imaging modality for assessment of bony anatomical structures.<sup>12</sup>

Along with the surgical guidance, the assessment of variation of lingual foramen and its canals can also be helpful in the determination of gender and age. Several studies have shown the efficacy of various foramen and canal evaluation in the determination of gender and age.<sup>13</sup> However, to the best of our knowledge no study has been done to evaluate the variation of lingual foramen in relation to age and gender.

Thus, the purpose of this study was to assess the anatomical variations of lingual foramen and location of lingual foramen and its bony canals by using CBCT in relation to age and gender. Their presence, number, position, diameter, morphology and trajectory were established. We evaluated the effect of patient's age and gender on the dimensional measurements of the anatomical landmark mentioned above.

---

## METHODS AND MATERIALS

---

In this retrospective study conducted at the Centre for Advanced Imaging, I.T.S Dental College, the sampling method was consecutive and the sample size of 100 CBCT scans of which 50 scans were of male patients and 50 of female patients. The data were obtained retrospectively from the data bank of Centre for Advance Imaging, Department of Oral Medicine & Radiology between 2015 and 2017. Ethical clearance was obtained for utilizing the scans for this study. Scans covering mandibular anterior region for preoperative implant placement planning were included. Scans of the patients within the age group of 20-60 years and those who were referred to the department for mandibular anterior region scan and scans done using the same acquisition parameters were included in the study. The scans of the patients with any bone pathology in mandibular anterior region or mandibular fracture or history of trauma, or artifacts or

scans of patients with any genetic abnormality or syndromes affecting the mandibular anterior region were excluded from the study.

All the CBCT scans were taken retrospectively from the CBCT unit (NewTomGiANO) using a standard exposure and patient positioning protocol and analyzed further using NNT software in ambient light on a Dell workstation. All observations were assessed on multiple sections and the section which had greatest dimensions was selected for variables measurement. (Figure 1). Two reference parallel lines were drawn for measurements. One line was drawn passing through the alveolar crest and second one passing through the inferior cortex of mandible. Inter observer reliability was calculated by Cohen's Kappa and inter class correlation was used to check the agreement between the two examiners.

Basic observations used in this retrospective study on sagittal section consisted of (fig. 1):

- Number of lingual foramen and its canals.
- Position of lingual foramen with relation to genial tubercle.
- Trajectory of lingual foramen canal.
- Length of lingual foramen canal.
- Diameter of lingual foramen canal at buccal and lingual end.
- Distance between the terminal end of lingual canal at the buccal and lingual side from the inferior border of mandible and alveolar crest.

The participants were divided into two age groups: Group A (20-40 years) and Group B (41-60 years). Afterwards, the effect of patient age and gender on the dimensional measurements of the anatomical landmark mentioned above was evaluated.

All the data were collected and entered into an Excel sheet. The statistical analysis was done using statistical software SPSS Version 16.0. The descriptive statistics, mean and standard deviation of different parameters were calculated. Comparison of the means of various parameters for categorical and numerical data was done by chi-square and unpaired t test. Inter-observer agreement was assessed with Cohen's

kappa test score and interclass correlation. The level of significance and Confidence of Interval (CI) were 5% and 95%.

---

## RESULTS

---

The mean age of the patients was 43.51± 12.9 years. The inter-class correlation coefficient was found to be between 0.838-0.935 which showed a good agreement.

The Cohen's Kappa (*k*) was found to be between 0.849-0.905 for number of lingual foramen, position and trajectory which showed an excellent agreement between the examiners.

Lingual foramen was observed in all 100 patients (100% of the cases). Two foramina were observed in 52% of cases whereas single foramen was observed in 43% of the cases. The remaining 5% of cases had three foramina. On comparing the distribution of number of lingual foramina among males and females, using chi square test, no significant difference was found (Table 1).

Out of 79 foramina found in males, 44 were superior to genial tubercle, 34 were inferior to tubercle and only single foramen was at the level of genial tubercle. In females out of 83 foramina, 45 was superior to genial tubercle, 38 were inferior and none were found at the level of tubercle. On comparing the distribution of Position of lingual foramen between males and females, using the Chi-square test, no significant difference was found. (Table 2)

Out of 79 foramina found in males, 48 were downward trajectory, 28 were upward and 3 canals were horizontal. In females out of 83 foramina, 51 were downward trajectory, 30 were upward and 2 canals were horizontal. On comparing the distribution of Trajectory of lingual foramen between males and females, using the Chi-square test, no significant difference was found. (Table 3)

The average length of lingual foramen canal in males was 6.31mm (SD 2.22) and in females was 6.11mm (SD 2.34). On comparing the mean Length of lingual foramen canal between males and females, using the unpaired t-test, no

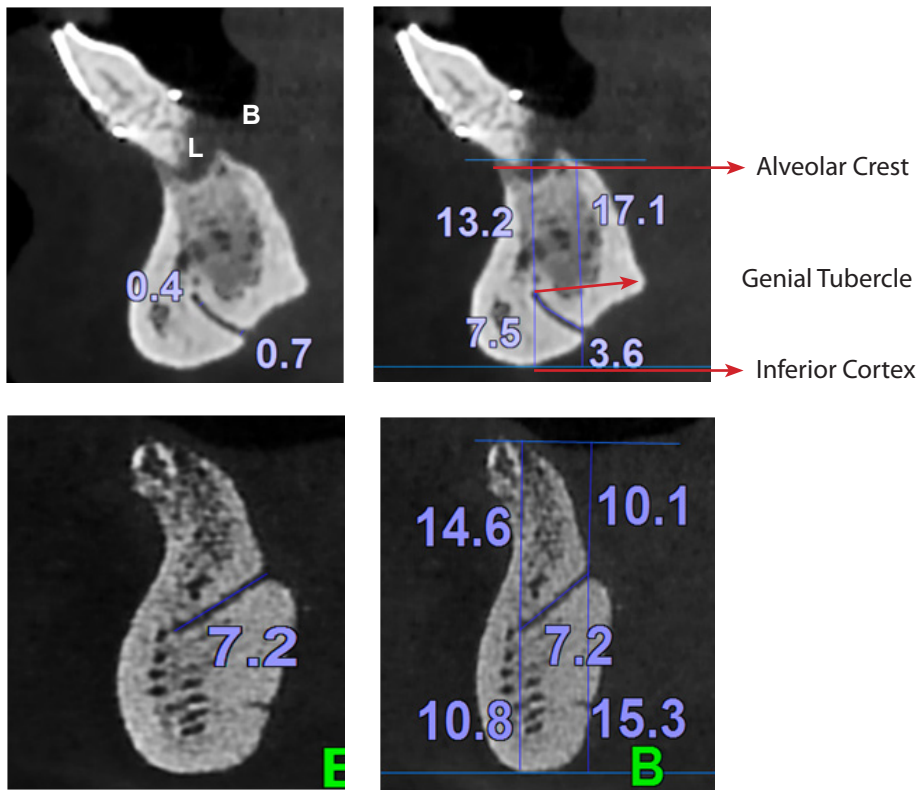


Figure 1 Dimensional measurements on axial sections. A. Diameter of lingual canal at buccal and lingual end. B and D. Distance between lingual foramen to alveolar crest and inferior cortex of mandible at buccal and lingual end. C. Length of lingual foramen canal.

No. of lingual Foramen	Gender		Total
	Male	Female	
1	23 46.0%	20 40.0%	43 43.0%
2	25 50.0%	27 54.0%	52 52.0%
3	2 4.0%	3 6.0%	5 5.0%
Total	50 100.0%	50 100.0%	100 100.0%

Table 1: Distribution of number of lingual foramen in relation to gender  
Notes: Chi-square test, # Non-significant difference

Position	Gender		Total
	Male	Female	
Superior to genial tubercle	44 55.7%	45 54.2%	89 54.9%
Inferior to genial tubercle	34 43.0%	38 45.8%	72 44.4%
At level	1 1.3%	0 0.0%	1 0.6%
Total	79 100.0%	83 100.0%	162 100.0%

Table 2: Distribution of position of lingual foramen in relation to gender.  
Notes: Chi-square test, # Non-significant difference

Trajectory	Gender		Total
	Male	Female	
Downward	48 60.8%	51 61.4%	99 61.1%
Upward	28 35.4%	30 36.1%	58 35.8%
Horizontal	3 3.8%	2 2.4%	5 3.1%
Total	79 100.0%	83 100.0%	162 100.0%

Chi-square value = 0.261 p-value = 0.878

Table 3: Distribution of trajectory of lingual foramen canal in relation to gender.

No. of lingual Foramen	Age Groups		Total
	20-40 Years	41-60 Years	
1	18 38.3%	25 47.2%	43 43.0%
2	27 50.0%	25 54.0%	52 52.0%
3	2 4.3%	3 5.7%	5 5.0%
Total	47 100.0%	53 100.0%	100 100.0%

Chi-square value = 1.673, p-value = 0.433

Table 5: Distribution of number of lingual foramen in relation to age  
Notes: Chi-square test, # Non-significant difference

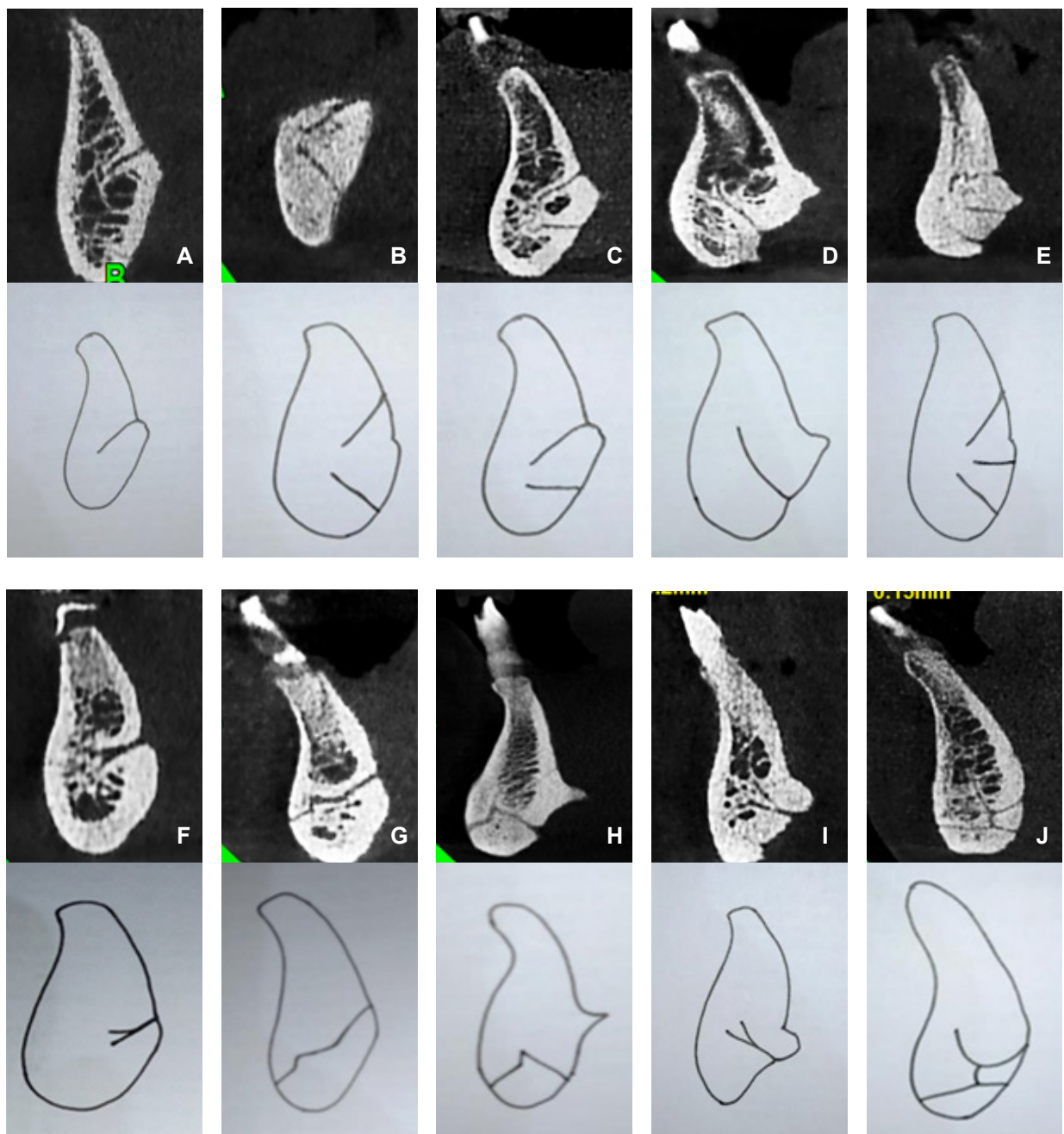


Figure 2: A-J Variations in the morphology of lingual canals in the anterior mandible as observed during review.

LOCATION	GENDER	MEAN	STANDARD DEVIATION	MEAN DIFFERENCE	T-TEST VALUE	P-VALUE
Length of Lingual Foramen Canal	Male	6.31	2.22	-0.20	0.559	0.577
	Female	6.11	2.34			
Diameter of lingual foramen canal at buccal end	Male	0.42	0.15	-0.05	2.113	0.036*
	Female	0.37	0.13			
Diameter of lingual foramen canal at lingual end	Male	0.60	0.25	-0.05	-2.422	0.047*
	Female	0.54	0.21			
BC	Male	18.70	4.62	0.47	0.684	0.495
	Female	18.23	4.04			
LC	Male	17.69	5.28	0.67	0.781	0.436
	Female	16.84	5.72			
BIC	Male	9.84	2.87	1.57	3.564	0.001*
	Female	9.25	2.90			
LIC	Male	10.90	5.06	1.39	2.787	0.046*
	Female	9.51	4.82			

**Table 4:** Variations of lingual canal length, diameter of lingual foramen canal, distance from alveolar crest to lingual foramen at buccal and lingual end, and distance from inferior border of mandible to lingual foramen at buccal and lingual end in relation to gender.

LOCATION	AGE GROUPS	MEAN	STANDARD DEVIATION	MEAN DIFFERENCE	T-TEST VALUE	P-VALUE
Length of Lingual Foramen Canal	20-40 years	5.90	1.85	-0.60	-1.669	0.097
	41-60 years	6.50	2.59			
Diameter of lingual foramen canal at buccal end	20-40 years	0.36	0.11	-0.60	-2.981	0.003*
	41-60 years	0.43	0.15			
Diameter of lingual foramen canal at lingual end	20-40 years	0.54	0.25	-0.60	-2.735	0.045*
	41-60 years	0.60	0.21			
BC	20-40 years	18.83	3.41	1.05	-1.052	0.294
	41-60 years	18.11	5.03			
LC	20-40 years	17.89	5.05	0.72	1.236	0.218
	41-60 years	16.84	5.72			
BIC	20-40 years	8.81	2.90	-0.44	-0.971	0.333
	41-60 years	9.25	2.90			
LIC	20-40 years	9.79	5.00	-0.77	-0.988	0.325
	41-60 years	10.56	4.95			

**Table 8:** Variations of lingual canal length, diameter of lingual foramen canal, distance from alveolar crest to lingual foramen at buccal and lingual end and distance from inferior border of mandible to lingual foramen at buccal and lingual end in relation to age.

No. of Lingual Foramen	Age Groups		Total
	20-40 Years	41-60 Years	
1	18	25	43
	38.3%	47.2%	43.0%
2	27	25	52
	57.4%	47.2%	52.0%
3	2	3	5
	4.3%	5.7%	5.0%
Total	47	53	100
	100.0%	100.0%	100.0%

Notes: Chi-square value = 1.673, p-value = 0.433  
Unpaired t-test # Significant differences

Position	Age Groups		Total
	20-40 Years	41-60 Years	
Superior	42	47	89
	53.8%	56.0%	54.9%
Inferior	35	37	72
	44.9%	44.0%	44.4%
At Level	1	0	1
	1.3%	0.0%	0.6%
Total	78	84	162
	100.0%	100.0%	100.0%

Notes: Chi-square value = 1.116, p-value = 0.572  
Unpaired t-test # Significant differences

TRAJECTORY	Age Groups		Total
	20-40 Years	41-60 Years	
Downward	44	55	99
	56.4%	65.5%	61.1%
Upward	31	27	58
	39.7%	32.1%	35.8%
Horizontal	3	2	5
	3.8%	2.4%	3.1%
Total	78	84	162
	100.0%	100.0%	100.0%

TYPES OF CANAL MORPHOLOGY	NO OF MANDIBLES MANDIBLES
A	34
B	48
C	3
D	3
E	5
F	2
G	1
H	1
I	2
J	1

**Table 9:** Ten different types of anatomical variations.

significant difference was found. (Table 4)

The mean diameter of lingual foramen canal at buccal end in males was 0.42mm (SD 0.15) and in female was 0.37mm (SD 0.13). The mean diameter of lingual foramen canal at lingual end in male was 0.60mm (SD 0.25) and in female was 0.54mm (SD 0.21). On comparing the mean Diameter of lingual foramen canal at buccal and lingual end between males and females, using the Unpaired t-test, statistically significant difference was found. [table 4] The mean Diameter of lingual foramen canal at buccal and lingual end was significantly more among males in comparison to females.

The mean distance from alveolar crest to lingual foramen at buccal end (BC) in males was 18.70mm (SD 4.62) and in females was 18.23mm (SD 4.04). The mean distance from alveolar crest to lingual foramen at lingual end (LC) in male was 17.69mm (SD 5.57) and in female was 17.02mm (SD 5.28). On comparing the mean BC and LC between males and females, using the Unpaired t-test, no significant difference was found. (Table 4)

The mean distance from inferior cortex of mandible to lingual foramen at buccal end (BIC) in males was 9.84mm (SD 2.87) and in females was 8.28mm (SD 2.72). The mean distance from inferior cortex of mandible to lingual foramen at lingual end (LIC) in males was 10.90mm (SD 5.06) and in females was 9.5mm (SD 4.82). on comparing the mean BIC and LIC between males and females, using the Unpaired t-test, significant differences were observed. The mean BIC and LIC was significantly more among males in comparison to females. (Table 4)

The distribution of number of lingual foramen was compared between 20-40 and 41-60 years age groups using the Chi-square test. However, no significant difference was observed between the groups. (Table 5)

On comparing, the distribution of Position of lingual foramen between 20-40 and 41-60-years age groups using the Chi-square test, no significant difference was observed between the age groups. (Table 6)

On comparing the distribution of Trajectory

of lingual foramen was compared between 20-40 and 41-60years age groups, using the Chi-square test, no significant difference was observed. (Table 7)

The average length of lingual foramen canal in 20-40 years age group was 5.90mm (SD 1.85) and in 41-60 years of age group was 6.50mm (SD 2.59). On comparing the mean Length of lingual foramen canal between 20-40 and 41-60years age groups using the Unpaired t-test, no significant difference was observed between the groups. (Table 8)

The mean diameter of lingual foramen canal at buccal end and lingual end in 20-40 years of age group has been depicted in table 8.

On comparing the mean Diameter of lingual foramen canal at buccal and lingual end between 20-40 and 41-60years age groups, using the Unpaired t-test, the Diameter of lingual foramen canal at buccal and lingual end was significantly more among 41-60 years age group in comparison to 20-40 years age group. (Table 8)

The mean distance from alveolar crest to lingual foramen at buccal end (BC) in 20-40 years of age group was 18.83mm (SD 3.41) and in 41-60 years of age group was 18.11mm (SD 5.03). The mean distance from alveolar crest to lingual foramen at lingual end (LC) in 20-40 years of age group was 17.89mm (SD 5.05) and in 41-60 years of age group was 16.84mm (SD 5.72).

On comparing the mean BC and LC between 20-40 and 41-60 years age groups using the Unpaired t-test, no significant difference in mean BC and LC between 20-40 and 41-60 years age groups was observed. (Table 8)

The mean distance from inferior cortex of mandible to lingual foramen at buccal end (BIC) in 20-40 years of age group was 8.81mm (SD 2.90) and in 41-60 years of age group was 9.25mm (SD 2.90). The mean distance from inferior cortex of mandible to lingual foramen at lingual end (LIC) in 20-40 years of age group was 9.79mm (SD 5.00) and in 41-60 years of age group was 10.56mm (SD 4.95).

On comparing the mean BIC and LIC was

compared between 20-40 and 41-60 years age groups using the Unpaired t-test, no significant difference in mean BIC and LIC between the groups was observed. (Table 8)

In the present study, we found ten different types of anatomical variations of lingual foramen canals morphology which was categorized from A to J. 34 mandibles were type A, 48 mandibles were type B, 3 mandibles were type C, 3 mandibles were type D, 5 mandibles were type E, 2 mandibles were type F, 1 mandible was type G, 1 mandible was type H, 2 mandibles were type I, 1 mandible was type J. [Figure 2, Table 9]

---

#### DISCUSSIONS

---

The field of dentistry is consistently evolving with advancements in dental technologies and the procedures like implant, grafting and orthognathic surgeries have gained popularity with increasing success rate. The clinicians should be aware of the anatomy of these vital structures and the variations to prevent any surgical complications.<sup>11</sup>

Many anatomical landmarks in the mandible including foramens and canals exhibit a high degree of sexual dimorphism. In previous studies, various anatomical parameters like the height of mandible, gonial angle and the position of mental foramen, mandibular foramen and mandibular canal have shown significant differences in various age groups and gender.<sup>14,15</sup> To the best of our knowledge there are very few studies in literature that determine the gender and age based on lingual foramen and its canals. In this study, 100 retrospective CBCT scans of anterior mandibular region were evaluated for anatomical variations of lingual foramen and its canals. Furthermore, the age and gender related changes were also evaluated based on the observations like number of lingual foramen and canals, position of lingual foramen, trajectory of lingual foramen canal, length, diameter of lingual foramen canal etc.

The result of the present study were consistent with those reported by Tepperet *et*

*al.*, Gahlleitner *et al.*, Tagaya *et al.*, Sheikhi *et al.*, McDonnell *et al.*, Denny *et al.*, who suggested that lingual foramen was found in 100% of the cases examined.<sup>16,17,18</sup> However, the results were in disagreement with the Jacob *et al.*, S. Caravilli *et al.*, and Longoni *et al.*, who observed lingual foramen in 82%, 90.35% and 60% of the Computed Tomography (CT) scans examined, respectively.<sup>19,20,21</sup> One possible interpretation of this disagreement is the imaging technique used. CT images with larger slice thickness may limit the accuracy of the measurements. Cone Beam Computed Tomography (CBCT) images obtained with a finer slice thickness is considered to be more reliable and accurate than those with larger slice thickness. The multiple CBCT sections were assessed in the present study with a finer slice thickness from a range of 0.15mm to 2mm due to which minute details on lingual surface of mandible was visualized more clearly than the above-mentioned imaging technique.

According to the present study two lingual foramina were found in 52% of the participants followed by single lingual foramen in 43%. The results were corroborated with those of Shekhiet *et al.*, Aggarwal *et al.*, and Choi *et al.*, Liang *et al.*, conducted a study on dry skull and found 3 foramina only in 4% of the 49 mandibles and our results were in accordance with this study.<sup>23</sup> While a study performed by Abesiet *et al.*, Shekhiet *et al.*, and Ceena E Denny *et al.*, found 3 foramina in 7.5%, 19.6% and 2% of the cases, respectively.

Most of the subjects in our study were having lingual foramen superior to genial tubercle (54.9%), followed by 44.4% that were inferior to genial tubercle. The results were in consistence with Shekhiet *et al.*, Nagar *et al.*, Iulianababuc *et al.*, Nimje DA *et al.*, and Aoun G *et al.*, who suggested that the most frequent position of lingual foramen was superior to genial tubercle followed by inferior to genial tubercle.<sup>25,26,27,28</sup>

In the present study, 61.1% participants showed downward trajectory of canal followed by 35.8% participants which showed upward trajectory. Our results were similar to the studies performed by Shekhiet *et al.*, Agrawal PK, and

Liang *et al.*, as their results show that the most common trajectory of lingual foramen canal was downward trajectory.

Our results showed that there was no significant difference in the number, position and the trajectory of lingual foramen canal among various age groups and gender which is in accordance to the studies done by a George Aoun *et al.*, and Denny *et al.*

According to our study the mean diameter of lingual canal at buccal and lingual end was significantly more in males as compared to females. The results were similar to the studies previously performed by He *et al.*, Sekerci *et al.*, and Wang *et al.*, which showed that male subjects had a larger diameter of the lingual foramen as compared to female subjects.<sup>29-31</sup> whereas in the 41-60 years age group exhibited more diameter in comparison to 20-40 yrs age group. Our results were also in favor of Abesi *et al.*, who said that there is significant relation between the diameter of lingual foramen and age group.<sup>24</sup>

Abesi *et al.*, found seven different types of lingual foramen canals morphology which was categorized from A to G.<sup>24</sup> Type B and A were most frequently found canals morphology in our study which is in accordance with the study by Abesi *et al.*. Another study performed by Sekerciet *et al.*, they found twelve different types of lingual foramen canals morphology

which were categorized into I-XII.<sup>29</sup> They found two extra variations in canal morphology as compared to the present study. That is type V (single lingual vascular canal exiting through the labial side of the mandible) and type IX (intersection of two separate canals; one exiting through the lingual cortical plate and one through the labial). These two extra canals variation could be due to the number of CBCT scans assessed. The number of scans assessed were more as compared to our study.

---

#### CONCLUSION

---

Every individual has anatomic variation and different measurements of lingual foramen and its bony canals. These variations must be taken into consideration prior to treatment planning to prevent any surgical complications. The mean diameter of lingual canal and the distance from lingual foramen to inferior cortex of mandible at buccal and lingual end varied significantly in males and females. There was also an age-related significant difference in the diameter of canal.

Hence, the morphology of lingual foramen and its canal can be used to evaluate the age and gender of an individual which can open a new vista in the field of forensics. However, further studies with more sample size are warranted to support this finding. **IJFMP**

---

#### Acknowledgment:

The authors have made no acknowledgment in this article.

#### Conflict of Interest:

The authors declare that there is no commercial or financial links that could be construed as conflict of interests.

#### Source of Funding:

The author declares that there is no funding for this project.

---

1. **Sheikhi Mahnaz, Mosavat Farzaneh, Ahmadi Ahura.** Assessing the anatomical variations of lingual foramen and its bony canals with CBCT. *Dental Research Journal (Isfahan)* 2012;9(1):45-51.
2. **Del Castillo-Pardo de Vera JL, Lopez-ArcasCalleja JM, Burgueno-Garcia M.** Hematoma of the floor of the mouth and airway obstruction during mandibular dental implant placement: Oral Maxillofacial Surgery 2008;12(4):223-226.
3. **Woo BM, Al-Bustani S, Ueek BA.** Floor of mouth haemorrhage and life-threatening airway obstruction during immediate implant placement in the anterior mandible. *International Journal of Oral Maxillofacial Surgery* 2006;35(10):961-964.
4. **Sutton RN.** The practical significance of mandibular accessory foramina. *Australian Dental Journal* 1974;19(3):167-173.
5. **Shiller WR, Wiswell OB.** Lingual foramina of the mandible. *Anatomical Record* 1954;119(3): 387-390.
6. **Ennis LM.** Roentgenographic variations of the maxillary sinus and the nutrient canals of the maxilla and mandible. *International Journal of Orthodontia and Oral Surgery* 1937; 23(7):173-193.
7. **Suzuki Koji, Sakai Toshinori.** The foramina on the lingual surface of the mandible in the Japanese. *Medicine Journal of Shinshu University* 1957;2(1):1-8.
8. **Liang X, Jacobs R, Lambrichts I, Vandewalle G.** Lingual foramina on the mandibular midline revisited: A macroanatomical study. *Clinical Anatomy* 2007;20(3):246-251.
9. **Douglas McDonnell, Mahdavi Reza Nouri, Todd ME.** The mandibular lingual foramen: A consistent arterial foramen in the middle of the mandible. *Journal of Anatomy* 1994;184(2):363-369.
10. **Gahleitner Andre, Hofschneider U, Tepper G, Pretterkleber M, Schick S, Zauza K, et al.,.** Lingual vascular canals of the mandible: Evaluation with dental CT. *Radiology* 2001;220(1):186-189.
11. **Bernardi Sara, Rastelli Claudio, Leuter Cinzia, Gatto Roberto, Continenza Maria Adelaide.** Anterior Mandibular Lingual Foramina: An In Vivo Investigation. *Anatomy Research International* 2014;1(1):1-6.
12. **Panjnoush Mehrdad, Rabiee Zonnar Sadat, Kheirandish Yasaman.** Assessment of location and anatomical characteristics of mental foramen, anterior loop and mandibular incisive canal using cone beam computed tomography. *Journal of Dentistry (Tehran)* 2016;13(2):126-132.
13. **Suragimath Girish, Ashwinirani SR, Christopher Vineetha, Bijjargi Shobha, Pawar Renuka, Nayak Ajay.** Gender determination by radiographic analysis of mental foramen in the Maharashtra population of India. *Journal of Forensic Dentistry and Sciences* 2016;8(3):176.
14. **Vodanovic Marin, Demo Zeljko, Njemirovskij Vera, Keros Jadranka, Brkic Hrvoje.** Odontometrics: A useful method for sex determination in an archaeological skeletal population? *Journal of Archaeological Science* 2007;34(6):905-913.
15. **Vinay G, Mangala Gowri S R, Anabalgan J.** Sex determination of human mandible using metrical parameters. *Journal of Clinical and Diagnostic Research* 2013;7(12):2671-2673.
16. **Tepper Gabor, Hofschneider Ursula B, Gahleitner Andre, Ulm Christian.** Computed tomographic diagnosis and localization of bone canals in the mandibular interforaminal region for prevention of bleeding complications during implant surgery. *International Journal of Oral Maxillofacial Implants* 2001;16(1):68-72.
17. **Tagaya Atsuko, Matsuda Yukiko, Nakajima Koh, Seki Kenji, Okano Tomohiro.** Assessment of the blood supply to the lingual surface of the mandible for reduction of bleeding during implant surgery. *Clinical Oral Implant Research* 2009;20(4):351-355.
18. **Denny Ceena, Natarajan Srikant, Ahmed Junaid, Binjal Almas.** Anatomic Variation in Lingual Foramen: A Cone beam Computed Tomography Study. *World Journal of Dentistry* 2016;7(4):179-181.
19. **Jacobs R, Mraiwa N, van Steenberghe D, Gijbels F, Quirynen M.** Appearance, location, course, and morphology of the mandibular incisive canal: An assessment on spiral CT scan. *Dentomaxillofacial Radiology* 2002;31(5):322-327.
20. **Scaravilli MS, Mariniello M, Sammartino G.** Mandibular lingual vascular canals (MLVC): Evaluation on dental CT of a case series. *European Journal of Radiology* 2010;76(2):173-176.
21. **Longoni Salvatore, Sartori Matteo, Braun Marc, Bravetti Pierre, Lapi Antonio, Baldoni Marco, Tredici Giovanni.** Lingual vascular canals of the mandible: The risk of bleeding complications during implant procedures. *Journal of Implant Dentistry* 2007;16(2):131-138.
22. **Agrawal Pratul Kumar, Anupama, Shetty Shilpa, Reddy Nalinakshamma Munisawmy.** Assessment of anatomic variation with the frequency, location, and morphology of mandibular lingual foramina using cone beam computed tomography. *International Journal of Current Research* 2017;9(8):55882-55886.
23. **Choi Da Yae, Woo Yong Je, Won Sung Yoon, Kim Da Hye, Kim Hee Jin, Hu Kyung Seok.** Topography of the lingual foramen using micro-computed tomography for improving safely during implant placement of anterior mandible region. *Journal of Craniofacial Surgery* 2013;24(4):1403-1407.
24. **Abesi Farida, Ehsani Maryam, Haghanifar Sina, Sohianiand Sina.** Assessing the Anatomical Variations of Lingual Foramen and its Bony Canals with CBCT. *International Journal of Sciences: Basic and applied research* 2015;20(1):220-227.
25. **Nagar M., Bhardwaj R. and Prakash R.** Accessory Lingual Foramen in Adult Indian Mandibles. *Journal of Anatomical Society of India* 2001;50(1):13-14.
26. **Babiuc Iuliana, Tärlungeanu Ioana, Păuna Mihaela.** Cone beam computed tomography observations of the lingual foramina and their bony canals in the median region of the mandible. *Romanian Journal of Morphology and Embryology* 2011;52(3):827-829.
27. **Nimje Dipita A, Yadav Nisha RB.** Lingual foramen around genial tubercle in adult Indian human mandibles. *International Journal of Anatomy Physiology and Biochemistry* 2014;1(3):6-8.
28. **Aoun Georges, Nasseh Ibrahim, Sokhn Sayde, Rifai Mohamad.** Lingual Foramina and Canals of the Mandible Anatomical Variations in a Lebanese Population. *Journal of Clinical Imaging and Science* 2017;7(16):1-8.
29. **Sekerçi Ahmet Ercan, Sisman Yildiray, Payveren Mehtap Arikan.** Evaluation of location and dimensions of mandibular lingual foramina using cone-beam computed tomography. *Surgical and Radiological Anatomy* 2014;36(9):857-864.
30. **Wang YM, Ju YR, Pan WL, Chan CP.** Evaluation of location and dimensions of mandibular lingual canals: a cone beam computed tomography study. *International Journal of Oral Maxillofacial Surgery* 2015;44(9):1197-1203.
31. **He Xuejiao, Jiang Junqiang, Cai Wei, Pan Yun, Yang Yang, Zhu Ke, Zheng Yun.** Appearance, location and morphology of mandibular lingual foramina in Chinese Han population. *International Dental Journal* 2016;66(5):272-279.