

■ CASE REPORT

A Case Of Megacolon with a Giant Fecaloma On Medico-Legal Autopsy

Robert Ngude¹, B Meel²

ABSTRACT

Chronic constipation is one of the causes of megacolon. It is generally a natural death, provided not died during procedure under anesthesia. This case (NM) is of a 15-year girl (NM) who died on the operation table and referred for a medico-legal autopsy. There has been a history of repeated episodes of constipation since the age of six, and frequently hospitalized but no definite diagnosis was made by primary health care physician. On autopsy, large bowel was distended with a hard giant fecaloma. On histopathological examination, hirschsprung's disease is ruled, and idiopathic megacolon was considered as a cause of death. History, clinical examination, autopsy findings, and histopathological picture along with medical negligence are discussed in this report.

Keywords | Hirschsprung disease; Idiopathic megacolon; Fecal impaction.

Author's Credentials:

¹Chief Specialist, Department of Forensic Medicine, Witwatersrand University, Johannesburg, South Africa. ²Research Associate, Faculty of Health Sciences, Nelson Mandela University, Port Elizabeth 6017, South Africa.

Corresponding Credentials:

B Meel, Research Associate, Faculty of Health Sciences, Nelson Mandela University, Port Elizabeth 6017, South Africa.

e-mail: Banwarimeel1953@gmail.com

INTRODUCTION

Idiopathic rectosigmoid megacolon is an uncommon and poorly understood condition characterized by massive dilatation and aperistalsis of the sigmoid colon.¹ It is unknown what causes dilatation and dysmotility in this condition, and it usually presents in late childhood or early adulthood.² Chronic constipation is very common and often difficult to remedy than an acute onset of constipation.³ Faecaloma is an extreme variety of

impaction in a chronic constipation.⁴ The fecaloma is characterized by a hardened large mass of faeces frequently localized in sigmoid colon and rectum, and is difficult to discharge.⁵ Primary cause of chronic constipation is related with intrinsic motility of colon and generally considered after secondary causes are ruled out.³ Chronic constipation if not managed promptly lead to faecal impaction, and rarely to fecaloma.⁵ The condition can be



How to cite this article

Robert Ngude, B Meel/A Case of Megacolon with a Giant Fecaloma on Medico-Legal Autopsy/Indian Journal of Forensic Medicine and Pathology/2021;14(3):379-382

due to congenital abnormalities such as Hirschsprung disease, idiopathic megacolon or known risk factors hence due to acquired conditions.⁶ Hirschsprung disease is a congenital abnormality, which is commonly neonatal with the neonate being unable to pass stool in the first 24 to 48 hours.⁶ Surgical techniques are available to remove the aganglionic bowel and reconstruct the intestinal tract.⁶ Pediatricians and primary care physicians have an important role to play in diagnosing and managing children with megacolon or hirschsprung disease.⁶

There are cases reported that lead to sudden death due to catastrophic spontaneous rupture of urinary bladder associated with megacolon due to faecal impaction (Faecaloma).⁷ According to the amended Health Professions Act 2007 section 56, all procedure related deaths are deemed to be unnatural deaths.⁸ In cases of unnatural deaths, the inquest Act (Act 58 of 1959) provides for a medico-legal investigation to be held, including medico-legal post mortem examination.⁸ The purpose of this case report is to highlight the problem of idiopathic megacolon in cases of chronic faecal impacted children.

CASE REPORT

A 15-year-old girl (NM) presented with repeated episodes of constipation since the age of 6 years. On admission she had difficulty in breathing and weaknesses of the lower limbs with inability to pass urine and distended bowel. On examination, the blood pressure was 135/52mm.Hg, pulse 150/min, respiratory rate 37 while no bowel sounds were elicited. Per rectal examination showed rock hard stools impacted within anus. Abdominal X-ray disclosed impacted stools and a severely distended large bowel. Earlier she was tested for pregnancy and found negative.

A laparotomy was arranged in a hospital. The patient went into cardiac arrest after induction of anaesthesia. Full cardiopulmonary resuscitation was done, and the patient recovered. On commencement of

surgery the patient went into cardiac arrest. Resuscitation was done again, but there was no return of spontaneous circulation. On autopsy, the body of 15-year-old girl weighed 5 kg. Left foot was hyperemic, brain weighed 1200g. The proximal colon was markedly distended with gas. The transverse colon, sigmoid colon and the rectum were distended and had rock hard impacted faeces, 5kg of this solid material being found. The liver was enlarged and congested. All other organs appeared intact and unremarkable. On histological examination, Hematoxylin and Eosin stains were used and demonstrated the ganglionic cells in the myenteric plexus with adjacent nerve twigs (Figure 4). This case was diagnosed as idiopathic megacolon by exclusion.

DISCUSSION

This is probably first case report which has come to attention of forensic pathologist for the first time in South Africa. It could be emphasized that sometimes unusual nature of cases which the forensic pathologist is confronted rather than his/her "daily bread" of traumatic deaths. When encountered at autopsy, its contribution to death requires assessment and a thorough investigation of its origin by the forensic pathologist.¹ A correct history of the case, along with anatomical sampling of tissue on autopsy are important to confirm the diagnosis.

NM was admitted on several occasions in different hospitals with history of constipation, but none of the doctor had any clue of diagnosis to her condition. They tested her for pregnancy, because of her distended abdomen and a high prevalence of teenage pregnancies. One could think of it that how many patients in hospital either poorly diagnosed or wrongly diagnosed in hospitals. NM is only one such example. The most common errors reported in the studies reviewed were evaluation and treatment errors.⁹

It is expected that Hirschsprung's disease should be suspected in any case of chronic constipation with history of repeated

admission in hospital. The deceased had a chronic illness that was not diagnosed for 9- years. If she were diagnosed early, there was good chance that the patient could have survived. It was a preventable death.¹⁰ Generally, Hirschsprung's Disease is a congenital condition that usually affects neonates who cannot pass stool in the first 24-48 hours.¹¹ This is due to the failure of ganglion cells to descend during embryogenesis around the 12th to 14th week.¹¹ Sometimes, when Hirschsprung's disease is limited, and involved to a small segment of bowel, then it can delay in manifestation such as teen years and early adulthood.¹¹ The preferred first diagnostic procedure is a contrast enema which could be performed at a primary health care setting. This will define the transition zone between normal (dilated) bowel and narrow segment of gut. This transition zone is seen in 70-90% of cases.¹² The gold standard of diagnosis is rectal biopsy. It is possible to obtain a sub mucosal rectal suction biopsy even without any anesthesia.¹³

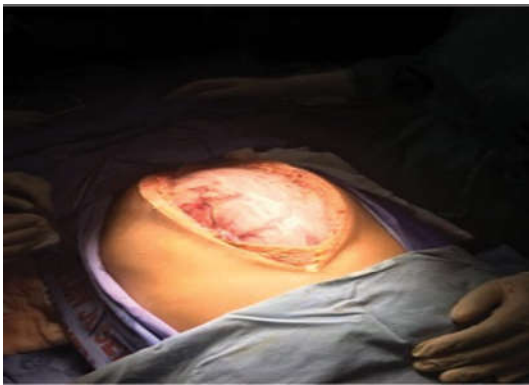

Fig. 1: A view of the exposed abdomen highlighting the abdominal distension (Pic courtesy of operating surgeon).

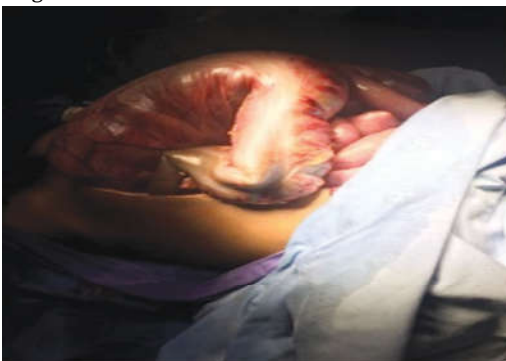

Fig. 2: A view of the distended bowel seen following the

abdominal laparotomy midline incision.

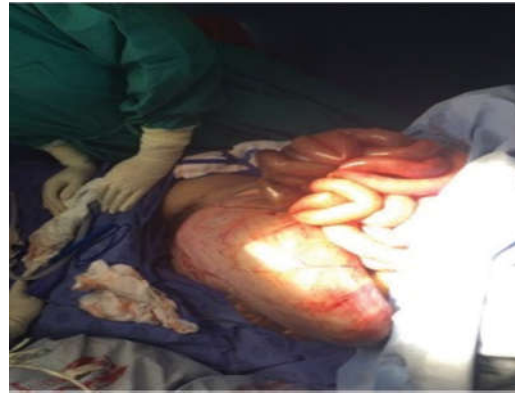

Fig. 3: Distended large bowel seen at laparotomy (Provided by the courtesy of operating surgeon).

The stool collected during autopsy weighed about 5 kg, rock hard and impacted the distal gastrointestinal tract (Photograph 1, 2 & 3). Abnormal dilation of the distal part of gut can develop from a range of disease processes. NM was not died in operation theatre, it may not be fault in category of deaths because of procedure, and therefore, it was not mandatory to carry out a forensic autopsy. Certain deaths that might have been considered natural in the past must now be classified as unnatural.⁸ Very few doctors know or understand the acts and regulations governing their professions, having had minimum exposure to them during undergraduate training.⁸

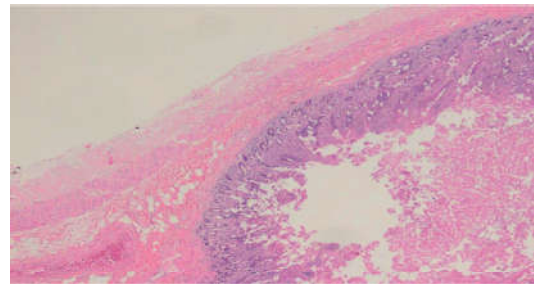


Fig. 4: A section of a full thickness of small bowel (4x).

The etiology of idiopathic megacolon, is due to atrophy of the tendinous fibrous net in the colon. Three elements are essential prerequisites to normal bowel movement are smooth muscle, TFN rooted to the tendinous tissue membrane of the myenteric plexus and an intact enteric nervous plexus system.¹⁴ The ganglionic cells were visible on histopathological examination in the case of NM, therefore, cannot fit in the diagnosis

of Hirschsprung's disease (Photograph 4). It could be an idiopathic megacolon, causing bowel distention with aperistaltic syndromes.¹⁴

Symptoms of inability to pass urine could be due to obstruction of the urinary bladder caused by chronic constipation and fecal impaction which leads to megacolon leading to urinary system mechanical obstruction in NM.⁷ The idiopathic megacolon is an uncommon entity and must be investigated thoroughly to find the gaps in clinical diagnosis. Primary health care physician must be aware of Hirschsprung and megacolon condition in their practice whenever they come across a case of chronic constipation.

The Forensic pathologist must be prepared for unnatural deaths as it falls under the Procedure-related Deaths Act of 2007. In summary, a good history is always emphasized to all medical officers in their primary health care training program so that they will not miss a case like that of NM. The cause of chronic constipation must be investigated thoroughly so that one can prevent a preventable death.

CONCLUSION

Forensic pathologist come across a variety of cases where medical practitioners commit errors in their judgment. Pathologist must report back to these medical doctors so that they will not carry out the same mistakes in their practice.

Acknowledgements

The author would like to thanks to all the stake holder who has contributed to this case, especially to Dr. Dineo Disenyane, a MMed Registrar in Anatomical Pathology with University of Pretoria who has provided histopathological findings in this case.

Acknowledgement

Ethical Issue: The information of this case report has been kept anonymous. However, a formal ethical permission was granted to report this case by the first author from his university.

Funding: self-funded

Conflict of interest: None

REFERENCES

- Hlavaty L, Sung L. Idiopathic Megacolon:** Report of 2 deaths with review of the literature. *The American J of Forensic Medicine and Pathology.* 2017; 38(3):254-257.
- Cribb B, Ranjan R, Henderson N.** A case of perforated chronic idiopathic megacolon. *NZ Med J.* 2015; 128(1422):70-72.
- Schultz M, Arnold T, Fornari M, Miglietta M.** Mega-colon secondary to chronic constipation. *World journal of medical and surgical case,* 2013; 2320-2332. <https://www.doximity.com › States › California › Encinitas> (Accessed 21.01.2018).
- Rajagopal A, Martin J.** Giant fecaloma with idiopathic sigmoid megacolon: report of a case and review of the literature. *Dis Colon Rectum.* 2002; 45(6):833-5.
- Zurabishvili K, Rekhviashvili A, Sakhamberidze M, Tsiklauri K.** A case of giant fecaloma in a 24-year-old woman. *Georgian Med News.* 2015; 240:11-14.
- Langer JC.** Hirschsprung disease. *Curr Opin Pediatr.* 2013; 25(3):368-74.
- Chute DJ, Archer ME, Robert J, Bready Ms, Reiber K.** Spontaneous Rupture of Urinary Bladder Associated With Massive Fecal Impaction (Fecaloma). *American journal of Forensic Medicine and Pathology,* 2009; 30(3):280-3.
- Van Vuuren SJ.** Acts and procedures concerning procedure-related deaths in South Africa. *J Primary health care in family medicine.* 213; 5(1):1-5.
- Settervall CH, Domingues CD, Sousa RMC, Nogueira LD.** Preventable trauma. deaths. *Rev Saude Publica* 212; 46(2):1-8.
- Rustein DD, Berenberg W, Chalmers TC, Child CG, Fishman AP, Perrin EB.** Measuring the quality of medical care: a clinical method. *N Eng J Med.* 1976; 294(11):582-8.
- Tjaden NEB, Trainor PA.** The development etiology and pathogenesis of hirschsprung disease. *Transl Res.* 2013; 162 (1):1-15.
- Smith GHH, Cass D.** Infantile Hirschsprung's disease- is barium enema useful? *Pediatric surgery international.* 1991; 6:318-21.
- Andrassy RJ, Weitzman HIJJ.** Rectal suction biopsy for the diagnosis of hirschsprung's disease. *Annals of surgery.* 1981; 193:419-24.
- Meier-Ruge WA, Muller-Lobeck H, Stoss F, Bruder E.** The pathogenesis of megacolon. *European J Gastro & hepato.* 2006; 18(11):1209-1215.