

■ CASE REPORT

Accidental Decapitation in Road Traffic Accident: A Rare Occurrence

Abhishek Yadav¹, Aravindan V², Jay Narayan Pandit³, Karthi Vignesh⁴

ABSTRACT

Accidental decapitation is very rarely seen in Road Traffic Accidents. The common site of decapitation is at the level of the mid-neck in C2-C3 vertebrae or C3-C4 vertebrae due to its weak nature. Here we present a rare presentation of decapitation in a case of Road Traffic Accident, where a person riding a cycle was decapitated at the atlanto-occipital joint. The mode of decapitation and the rarity of its site make this case unique. Autopsy surgeons do not encounter decapitation cases regularly and hence on first encounter many queries regarding manner of death arises in one's mind. The autopsy surgeons should be clear that although decapitations are commonly encountered in suicide and railway track settings, there is a possibility of its occurrence in regular road traffic accident settings also especially in persons travelling in two-wheeled (open) vehicles.

Keywords | Decapitation; Road Traffic Accident; Atlanto-occipital joint; Avulsed Laceration.

INTRODUCTION

Decapitation is the separation of head from the trunk. It can be of two types: complete and incomplete decapitation. It always causes sudden death because all the vital structures passing through the neck are severed in decapitation.¹ Decapitation may be antemortem or occur due to postmortem mutilation.² In antemortem decapitations, suicides are more common than the other manners of death. Accidental and homicidal manners occur almost equally but quite less than suicides.³ Accidental decapitation is commonly encountered in army conflicts where people are commonly exposed to explosive materials. It is relatively rare in civilian settings⁴ like in industrial accidents or railway accidents.⁵ The frequency of accidental decapitation in Road Traffic Accidents is more in pedestrians⁶, motorcyclists⁷, and cases were also reported in car drivers⁸ and

Author's Credentials:

¹Additional Professor,
²Junior Resident, ^{3,4}Senior Resident, Department of Forensic Medicine and Toxicology, All India Institute of Medical sciences, New Delhi 110029, India.

Corresponding Credentials:

Abhishek Yadav, Additional Professor, Department of Forensic Medicine and Toxicology, All India Institute of Medical sciences, New Delhi 110029, India.

e-mail: drayad_in@yahoo.com



How to cite this article

Abhishek Yadav, Aravindan V, Jay Narayan Pandit, Karthi Vignesh/Accidental Decapitation in Road Traffic Accident: A Rare Occurrence/Indian Journal of Forensic Medicine and Pathology/2021;14(3):373-377

passengers⁹ of cars or buses. The common site of decapitation is at the level of the mid-neck in C2-C3 vertebrae or C3-C4 vertebrae due to its weak nature.¹⁰ Here we present a rare presentation of decapitation in a case of Road Traffic Accident, where a person riding a cycle was decapitated at the atlanto-occipital joint. The mode of decapitation and the rarity of its site make this case unique.

CASE DETAILS

A 48-year-old male was riding a bicycle on a busy road in Delhi. Allegedly, a mini truck hit his bicycle from the back and he was thrown out of his cycle over a street light pole. He was brought to trauma emergency of AIIMS, New Delhi, where he was declared brought dead. Before autopsy, X-ray examination (Figure-1) was done, which showed decapitation at the atlanto-occipital joint. He was well-built and moderately nourished.

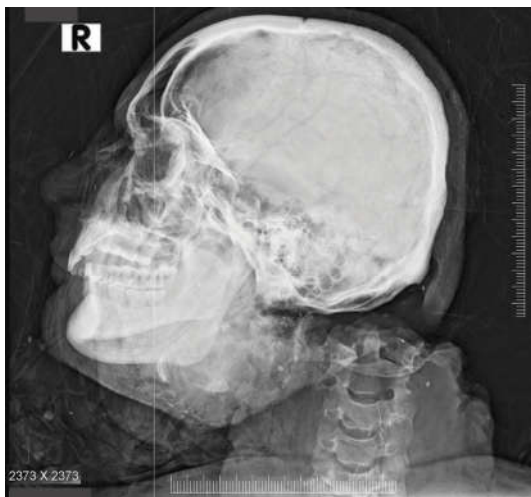


Fig. 1: Digital X-ray of head and neck.

Rigor mortis was present all over the body. An avulsed lacerated wound leading to a near-total decapitation of the head (Figure 2) was present. The head was severed at the level of the atlanto-occipital joint and attached with the trunk only by a piece of skin and soft tissue (Figure 3). All structures including the trachea, esophagus, blood vessels, nerves, and bone were cut. Graze abrasions were present over the anterior aspect of the chest. Lacerated wounds were present over the bilateral occipital region and right frontal region of

the scalp. Multiple abraded contusions were present over the face, both arms, and elbows. On opening the scalp, diffuse subdural and subarachnoid hemorrhage were present.

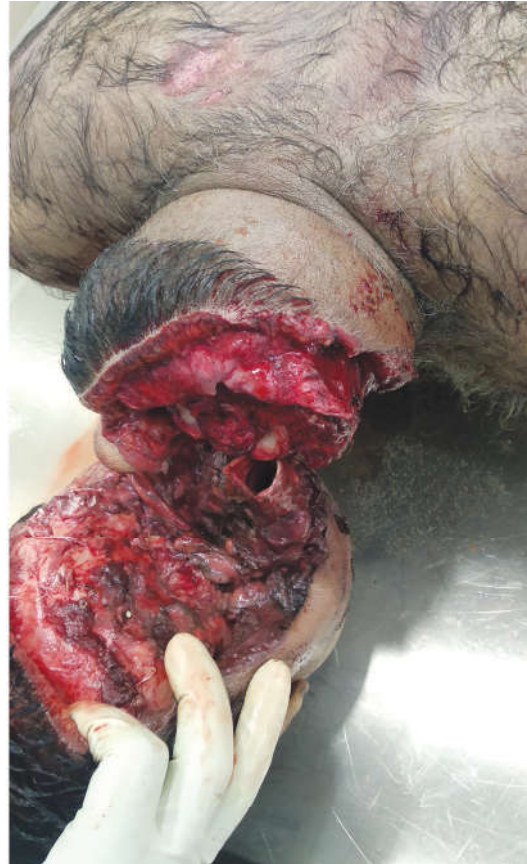

Fig. 2: Near-total Decapitation at atlanto-occipital joint.

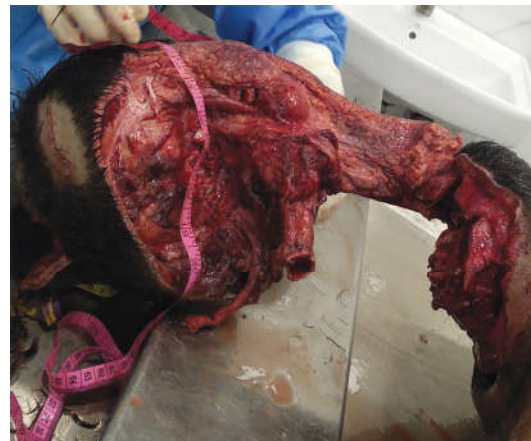

Fig. 3: Near-total decapitation.

Hemothorax was present and all the organs were pale. The cause of death was given as Traumatic decapitation due to blunt force/surface impact.



Fig. 4: Crime scene photograph.



Fig. 5: Damaged back of bicycle.

Crime scene photographs were analyzed and crime scene examination was done which

were consistent with the given history and the postmortem findings. The victim was recovered from the base of a street light pole (Figure 4). The back portion of the bicycle was badly damaged (Figure 5) and the front wheel of the mini-truck was seen dismantled from the main truck and the front part of the truck was damaged (Figure-6).



Fig. 6: Damaged front of mini truck.

DISCUSSION

In India, National Crime Records Bureau 2019 reports documented a total of 4,67,171 cases of Road Traffic Accidents of which 1,81,113 cases were fatal.¹⁰ However, decapitation cases were reported in less than 0.01% of all traffic accidents in the past.⁴ Decapitations are rare outcomes of Road Traffic Accident. Due to its rarity, decapitation cases are less studied and only case reports, case series and some review articles are present in the literature.

Historically, decapitation was carried out as capital punishment since 3000 BC in Rome and Greece.¹¹ They used devices like guillotine for carrying out decapitation. Even in 2013, allegedly judicial executions by

decapitation was reported in Saudi Arabia.¹² The 19th and 20th century literature shows more decapitations in army conflicts only. The civilian settings have seen more number of decapitations in suicides involving railway track.⁴ The homicidal and accidental decapitations are relatively less. Decapitations in form of postmortem mutilation are also reported in the literature.

Accidental decapitations are rarely encountered in civilian settings but contribute to high degree of mortality, especially among young individuals.⁹ Decapitation in road accidents occur due to sudden stoppage of an individual travelling in high velocity¹³ by a stationary object. Zivot and Dimaio in their study found out that minimum 98km/hr speed is required to cause decapitation.¹⁴ Cases are also reported in low velocity impact.¹⁵ The reported stationary objects in the literature are barrier stanchion¹³, iron cross bar¹⁶, tailgate of truck and roadblock chain.¹⁷ Both speed and impact with the stationary object are important mechanisms in decapitations due to road traffic accidents. In our case, a mini truck had hit the back of a cycle.

The deformations in the back of the cycle and the front of the mini truck noticed during crime scene examination were suggestive of a high-speed impact. The stationary object involved in our case was a street light pole on the side of the road. The possible mechanism in our case could be the sudden stoppage of the victim's face causing violent facial impact by the street light pole resulting in profound hyperextension at the atlanto occipital joint thereby leading to decapitation when he was thrown out of his cycle by a high-velocity impact. There were multiple lacerations in front of face and head confirming our possibility of a violent facial impact.

Road accidents related decapitations have been reported in pedestrians⁶ and motorcyclists.⁷ The mechanism behind this could be the exposure of the entire body

to high-velocity impact accidents. The usage of helmets were also not immune for decapitations because of exposure of the neck.¹⁸ It is a known fact that occupants of closed vehicles are relatively safe compared to that of two-wheeled (open) vehicles. The mechanism of exposure of whole body may not be completely acceptable because car drivers and passengers of cars and buses⁹ were also reported to be victims of decapitation in road traffic accidents. In our case, the victim was riding a bicycle and was not wearing helmet. The mechanism of full body exposure could be a possible mechanism of decapitation here.

The site of the decapitation is commonly the mid-neck (C3-C5) in almost all the cases of accidental decapitations in road traffic accidents reported in the literature.¹⁸ The possible mechanism may be due to its anatomical weakness or a direct impact over the cervical region.¹⁹ The cases where the mechanism of violent facial impact followed by hyperextension of neck also reported the site of impact to be in mid-neck (C3-C5). In our case, the site of decapitation was at atlanto-occipital joint. The possible explanation for the site of decapitation being different from that of other reported cases could be the exact site of facial impact. The site of facial impact in our case was in and above the area of forehead, which could explain the higher level of site of decapitation.

CONCLUSION

Autopsy surgeons do not encounter decapitation cases regularly and hence on first encounter many queries regarding manner of death arises in one's mind. The autopsy surgeons should be aware that although decapitations are commonly encountered in suicide and railway track settings, there is a possibility of its occurrence in regular road traffic accident settings also especially in persons travelling in two-wheeled (open) vehicles.

REFERENCES

1. **Dogan KH, Demirci S, Deniz I, et al.** Decapitation and dismemberment of the corpse: a matricide case. *J Forensic Sci.* 2010;55(2):542–545.
2. **Winskog C, Byard RW.** Decapitation: a rare form of postmortem mutilation. *Forensic Sci Med Pathol* 2015 Sep 8;12(1):98–100.
3. **Pilloud MA, Swenson VM, George RL, Knight LD.** Patterns in forensic decapitations: a review of the literature and case report. *Am. J. forensic med. pathol.* 2019 Sep 1;40(3):246–50.
4. **Byard RW, Gilbert JD.** Characteristic Features of Deaths Due to Decapitation. *Am. J. forensic med. pathol.* 2004 Jun;25(2):129–30.
5. **Umesh-Babu R, Kiran J.** Accidental Decapitation; a Case Report. *Int J Med Toxicol Forensic Med.* 2015;5(1):36–8.
6. **Karger B, Teige K, Bühren W, DuChesne A.** Relationship between impact velocity and injuries in fatal pedestrian-car collisions. *Int J Leg Med.* 2000 Feb 15;113(2):84–8.
7. **Osculati A, Visonà SD, Della Chiesa L, Navarra F, Calbi A, Andrello L.** Death Due to Decapitation in Two Motorcyclists: A Description of a Unique Case and a Brief Review of the Literature. *J Forensic Sci.* 2016 Dec 16;62(3):804–6.
8. **Ausania F, Cittadini F, Cascini F, Polacco M, Pascali VL, Oliva A.** Decapitation Due to Car Accident. *Am. J. forensic med. pathol.* 2011 Dec;32(4):308–9.
9. **Rashid AF, Aggarwal AD, Aggarwal OP, Kaur B.** Accidental decapitation – An urban legend turned true. *Egyptian Journal of Forensic Sciences.* 2012 Sep;2(3):112–4.
10. **Traffic Accidents in India.** National Crime Record Bureau. [Internet]. 2019. [updated 2021 Mar 20; accessed 2021 Mar 25]. Available from: https://ncrb.gov.in/sites/default/files/Chapter-1A-Traffic-Accidents_2019.pdf.
11. **Webster's Revised Unabridged Dictionary,** edited by Noah Porter, published by G & C. Merriam Co., 1913.
12. **Death Sentences and Executions 2013"** (PDF). Amnesty International. 2014. Retrieved 19 September 2014.
13. **Kibayashi K, Yonemitsu K, Honjyo K, Tsunenari S** (1999) Accidental decapitation: an unusual injury to a passenger in a vehicle. *Med Sci Law* 39:82–84.
14. **Zivot U, Di Maio VJM** (1993) Motor vehicle–pedestrian accidents in adults: relationship between impact speed, injuries and distance thrown. *Am J Forensic Med Pathol.* 14(3): 185–186.
15. **Stojiljkovic G, Papić Z, Bogdanović V, Simeunović M, Saulić N.** Unusual Response of Human Tissue under the Low Impact Force. *Int J Forensic SciPathol.* 2016 Oct 14;4(10):285–8.
16. **Sharma GK, Sarangi MP, Tyagi AK** (1995) Decapitation death. *Med Sci Law* 35:85–86.
17. **Ihama Y, Miyazaki T, Fuke C, Niki H, Maehira T.** Complete decapitation of a motorcycle driver due to a roadblock chain. *International journal of legal medicine.* 2008 Nov;122(6):511–5.
18. **Zoja R, Gentile G, Giovanetti GF, Palazzo E.** Death by complete decapitation of motorcyclist wearing full face helmet: case report. *Forensic science international.* 2011 Apr 15;207(1-3):e48–50.
19. **A.C. Aufderheide, C. Rodriguez-Martin,** *The Cambridge Encyclopedia of Human Paleopathology,* vol. 29, Cambridge University Press, 2006.

