

■ CASE REPORT

Doctrine of 'res ipsa loquitur' in surgical management of head injury in Transkei region, South Africa: Case Report

Banwarilal Meel

ABSTRACT

Background: Poor people accept death as 'God's wish', sing a ritual song and bury their loved ones without pointing a finger at anyone or asking how their loved ones died. Medical errors cause several deaths, but most of the time this goes unnoticed, because many affected by it are poor and illiterate.

Objective: To highlight the problem of fatal surgical errors in the management of head injury of patients in the Transkei region of South Africa.

Case Histories: The case reports of the autopsies that discussed are intended to highlight the gross surgical negligence of medical professionals. In the first case, burr-holes were made to release intracranial pressure, but a piece of glass, which was the primary cause of increased intracranial pressure, was left in the cranium. In the second case, an inexperienced operating surgeon pushed the drill deep into the cortex of the brain while making burr-holes. The third case report describes a head injury suffered by an alcohol-intoxicated patient. The head injury was inflicted at a police station. This article presents histories, post-mortem findings, causes and mechanisms of death, as well as discusses acts of commission and omission.

Conclusion: A high level of fatalities is caused by 'acts of commission and omission' in respect of head injury of patients in the Transkei region of South Africa. This matter needs regular auditing through forensic pathology services.

Author's Credentials:

Professor, Research Associate, Nelson Mandela University, Port Elizabeth 6031, South Africa.

Corresponding Credentials:

B Meel, Professor, Research Associate, Nelson Mandela University, Port Elizabeth 6031 South Africa.

Email: meelbanwari@yahoo.com

Keywords | Surgical Negligence; Medical Ethics; Res Ipsa Loquitur.



INTRODUCTION

Surgery has become an integral part of global health care, with an estimated 234 million operations performed annually. Surgical complications are common

and often preventable.¹ Preventable medical errors lead to the death of up to 98,000 Americans annually and cost the US economy over \$17 billion per year.² The most expensive of

How to cite this article

BMeel/Doctrine of 'res ipsa loquitur' in surgical management of head injury in Transkei region of South Africa: Case reports/Indian Journal of Forensic Medicine and Pathology/2021;14(3):367-372

these errors are related to surgery, accounting for over \$6 billion annually, roughly one-third of the total financial burden of medical error.²

South Africa may be on the verge of a medical malpractice litigation 'storm', as the number and size of claims appear to be increasing rapidly. In the last four years the Department of Health (DotH) has incurred R1.2 billion in legal costs relating to medical malpractice.³ The worst provincial culprits were KwaZulu-Natal (R209.1 million), the Eastern Cape (R91.9 million) and Limpopo (R30.9 million).³ According to the Medical Protection Society, the cost of reported claims more than doubled over a recent two-year period. Claims exceeding R1 million have increased by nearly 550% compared to 10 years ago, while claims valued at over R5 million have increased by 900% in the past five years.⁴

The Health Professions Council of South Africa (HPCSA) received 2,403 complaints between April 2011 and March 2012. Many of these related to claims for misdiagnosis, practising outside the scope of practice and refusal to treat patients.⁴ Medical professionals fail in their responsibility to their patients by not giving them proper care and attention, acting maliciously, or providing substandard care, thus causing far-reaching complications such as personal injury and even death. A study conducted by the author showed that at least 12% of hospital deaths in the Transkei region are preventable.⁵

Medication errors are an important problem in health care, causing harm to patients. In 1993 such errors were estimated to account for 7000 deaths in the USA.⁶ According to the HPCSA, between April 2008 and March 2009 about 90 doctors in South Africa were found guilty of unprofessional conduct.⁷ Forty-four doctors have been struck from the roll since 2005 owing to unethical and unprofessional conduct.⁷ Xhosa society is not litigious in nature. They leave everything to god. This is because the people are poor and illiterate. Seventy-three percent of the rural people in the Eastern Cape were living

on less than R300 per month in 2005/2006 and more than half of them on less than R220 per month.⁸ The purpose of these case reports is to highlight the problem of surgical malpractice through 'acts of omission' and 'acts of commission' in the Transkei region of South Africa.

Case History 1

Mr XM was a 25-year-old male who was drinking beer in a shebeen (local liquor selling place) with his girlfriend one evening. Some other young boys were also drinking in the same place. One of them harassed Mr XM's girl friend, which led to a fight. He was hit on the head with a broken beer bottle and started bleeding profusely. He was brought to hospital, where he was admitted and initially stabilised, but he became unconscious. The next day he was taken to theatre to decrease intracranial pressure. Two burr-holes were made in the anterior and posterior part of the parietal bone, but a piece of glass lodged in the cranium was not removed. The patient died after two days.

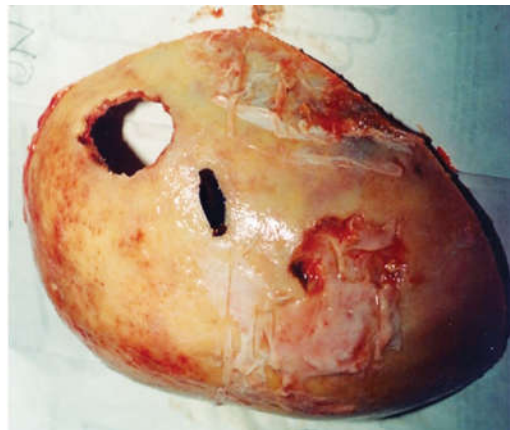


Fig. 1: Two burr-holes and piece of glass in center on outer table of left side of parietal bone.

On autopsy, the scalp was found to be stitched, and two burr-holes were seen in the parietal bone. One burr-hole was completed, but the other was just drilled into the outer table of bone. A piece of glass was recovered. A depressed fracture of the parietal bone was seen, with a cut in the meninges and the brain tissue. Subdural and subarachnoid hemorrhage was observed on the surface of

the brain. The brain was oedematous with shifting and tentorial herniation on one side. The other organs were congested.

Case History 2

Mr BM was a 40-year-old male who was assaulted, being hit on the head with a stone. He was brought to hospital by the police and admitted in a state of unconsciousness. He was diagnosed as having a head injury with subdural haemorrhage. He was operated on and later died in hospital.

On autopsy, stitches were found on the head. Underneath the stitched wounds, burr-holes were seen on the anterior and posterior part of the parietal bone. The durameter and cortex of the brain were found to be cut corresponding to the both burr-hole. The brain was oedematous, and tonsillar herniation was observed. The lungs were oedematous and the other organs congested.

Case History 3

Mr TT was a middle-aged man with a history of alcoholic intoxication whom the police brought to the hospital's casualty department in a semi-comatose state one night. He had been in police custody. The patient was diagnosed as alcohol-intoxicated, as his breath was smelling of alcohol. He was treated with intravenous fluid and insulin. The patient died after two days in hospital. He was sent to the forensic pathology laboratory for an autopsy.

On autopsy, some bruises were found on his head. When the skull cavity was opened, a massive extradural haematoma was visible underneath a depression of the cerebral cortex. Tentorial as well as tonsillar herniation with shifting of the brain to the opposite side was observed. The brain was oedematous and the other organs were congested.

DISCUSSION

This autopsy case report is the first of its kind in the Transkei region of South Africa. It reveals the tip of an iceberg and provides important information to justify further study to develop a protocol for the care of

patients in hospitals in this region. Iatrogenic hospital deaths are generally under-estimated and therefore under-reported. The reporting system used by hospital management is inadequate and most of these deaths are ignored or remain unnoticed. A few cases of iatrogenic injury deaths come to the notice of forensic pathology services because they are referred for medico-legal autopsies. However, even when an autopsy reveals apparent negligence causing the death, no action is taken. When people are poor, they are regarded as lesser human beings. They do not have a voice, and if they have, there are not enough people to listen to them.

According to the Health Professions Amendment Act (Act 29/2007), death during or after a surgical procedure may be considered medico-legal and subjected to medico-legal autopsy and inquest. All deaths due to surgical mishaps, including anaesthetic and/or procedure related deaths, are dealt with under section 48.⁹ In the past the practice was to refer such cases for medico-legal autopsy, but this culture no longer exists in hospital in Transkei region. Deaths are taken very lightly and hardly any enquiry is instituted by the management.

Case 1 was operated on and two burr-holes were observed, but the piece of broken glass bottle, which was the primary cause of increased intracranial pressure, was not removed by the operating surgeon.

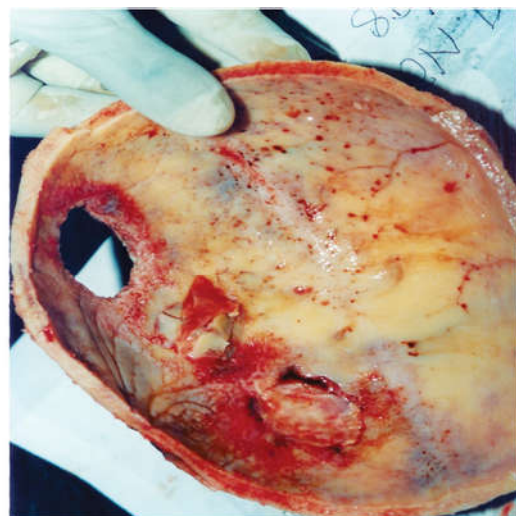


Fig. 2: Depressed fracture of inner table of left parietal

bone of skull in centre with two burr-holes on both side.

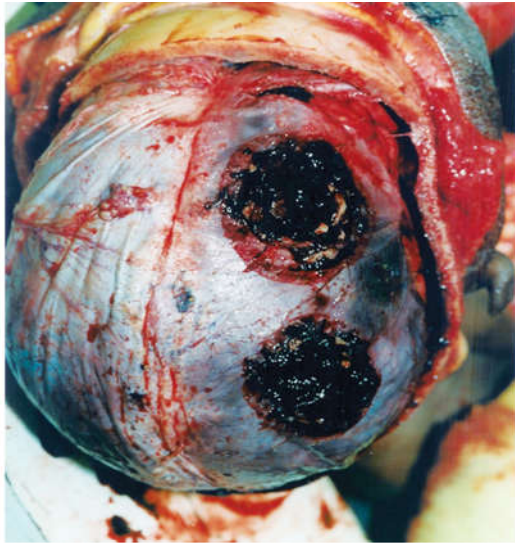


Fig. 3: Burr-holes on right parietal bone penetrated into duramater and lacerated cortex of right parietal lobe of brain.

The first burr-hole was very superficial, incomplete and did not serve any purpose. The second was in the occipital bone (Photograph 1). The piece of glass had led to a depressed fracture (Photograph 2). Young doctors are not trained sufficiently to carry out craniotomy procedures. Moreover, they are doing these operations on their own without any supervision.¹⁰ It is difficult to estimate how many patients have died because of the negligence of these doctors, but it could be presumed that the number is very high.

Case 2 suffered from an uncommon complication of extensive damage to the cerebral cortex underneath burr-hole surgery, indicating that the operating surgeon was not aware of this complication (Photograph 3). The damage to the cerebral cortex was caused exclusively by the surgeon who operated on the patient. It was absolute carelessness and could not be accepted at any standard of patient care. If it happened in any other developed country or even in this country in some metropolitan cities, it would have been headline news in the media. Sadly, it will remain unnoticed and secret forever, and the doctor will not change his/her way of practice. Most young doctors in public hospitals are working without any supervision.¹⁰ Subdural

haematoma is commonly treatable by burr-hole craniotomy with drainage, which is most effective, provided the procedure is performed by an experienced doctor who takes specific precautions to reduce complications.¹¹ The lack of experienced doctors in this region is a matter of concern. They learn, but only after killing several patients, which could be called the 'cut, kill and learn syndrome'. This is totally unacceptable in any society.

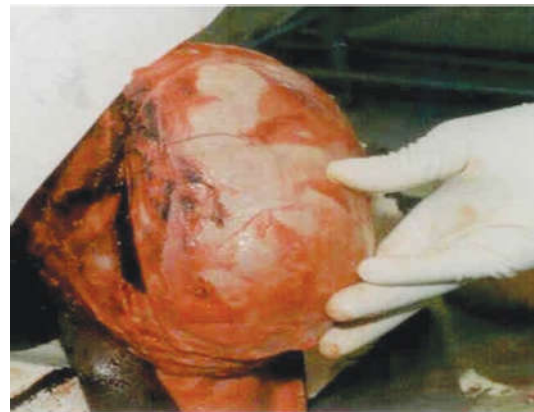


Fig. 4: Fracture of left side parietal and temporal bone.

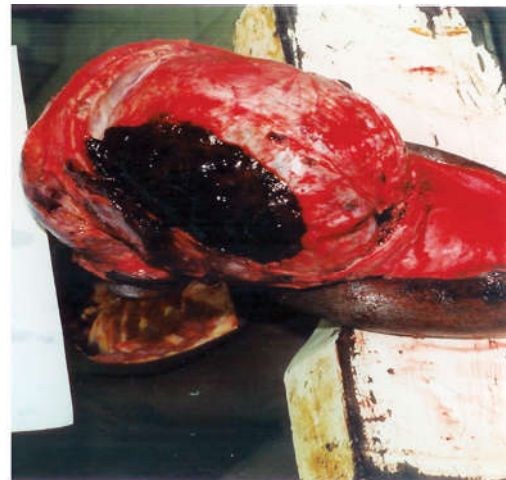

Fig. 5: Extradural hematoma underneath fractured temporo-parietal bone on left side of head.

Case 3 was arrested by police when drunk on a road. He was beaten in police custody and died in the hospital's casualty department. No intervention was carried out, since it was simply presumed that he was drunk. The treating medical officer did not seem to be aware that two conditions can exist in the same patient. It is very important to look for signs of trauma associated with alcohol abuse, especially head injuries, as such patients are more prone to these. This was an

act of omission. This death could have been avoided, as an extradural haematoma is a treatable condition (Photograph). Traumatic extradural haematoma is a neurosurgical emergency and timely surgical intervention is the gold standard.¹²

All three cases in this report fall in the category of the doctrine of Res Ipsa Loquitur, 'the facts speak for themselves.' If a doctor involved in such a case is charged, the incident, which was under the exclusive control of the defendant (cases 1 and 2) happened, but it would not have happened in the absence of negligence, and the plaintiff did not contribute to the harm by his own negligence. The burden of proof then falls on the defendant to refute this prima facie inference of negligence that has been created.¹³ This doctrine is not currently applied in South African courts.¹⁴ This maxim would shift the advantage to the plaintiff in cases of negligence, thus supporting the patient's constitutional right in terms of section 27 (a).¹⁵

There is very limited literature on medical malpractice in South Africa. Surgical malpractice is much easier to pick up in autopsy, but medical errors are difficult and need a well-equipped toxicology laboratory to estimate the drug level. It is the duty of a doctor to do what is best for the patient, and to avoid the death of patients by iatrogenic injury.¹⁶ Medical professionals who work in hospitals must act transparently and be accountable to the public, but that has not happened in these cases. Forensic pathology services provide reliable data that can be used to ensure the quality of care of patients in hospital. Strengthening forensic pathology services will help in quality control in the management of patients in hospitals. Deservedly large pay-outs have been made to patients, related to the harm suffered because of negligence of doctors.¹⁷

In public sector hospitals, there is a mix of many problems such as too many ill patients, non-functioning equipment, and recurring shortage of supplies, exacerbated by lack of experience of interns and community service

medical officers, who all too often function unassisted and are not advised by senior personnel.¹⁰ Deaths due to these conditions remain unnoticed by the next of kin forever.

People in this region are not aware of any kind of litigation process. Even if some know about it, it is difficult to pay the legal fee. This occurs because of a low level of literacy and poverty among people in this region. The Department of Health (DOH) is more concerned about the money paid because of litigation every year, they do not look the lives lost unnecessarily.

People are 'God-fearing' and do not blame their doctors when something goes wrong, yet in many cases litigation would be justified. Too many medical personnel and other stakeholders do not care about the pain and suffering of the people in this region because of negligent service delivery. Patients are invariably the losers, particularly in smaller towns and rural areas as they lost their loved one, and not get compensated in any form.⁴

The high level of iatrogenic injuries or negligence in the care of patients in hospitals could be prevented. The hospital management must be sensitive to these deaths and must carry out periodic mortality meetings and auditing of patient care.

Acknowledgement

Ethical issues: The author has maintained complete confidentiality about the deceased, the health care providers and even the hospitals where the patients were treated. The author has ethical permission for case report publication (approved project No. 4114/1999) from the Ethical Committee of the University of Transkei, South Africa. This article was submitted to some journals but not on internet. It is not a responsibility of an author if someone can publish it without a galley proof to the author.

Conflict of Interest: None

Funding: Self-funded

REFERENCES

1. **Haynes AB, Weiser TG, Berry WR, Lipsitz et al.** A surgical safety checklist to reduce morbidity and mortality in a global population. *N Engl J Med.* 2009; 360:491-9.
2. **Van Den Bos J, Rustagi K, Gray T, Halford M, Ziemkiewicz E, Shreve J.** The \$17.1 billion problem. The annual cost of measurable medical errors. *Health Aff (Millwood).* 2011; 30:596-603.
3. **Medical Malpractice: Health Department spends R1.2 billion on litigation.** <https://www.da.org.za/2015/06/medical-malpractice-health-department-spends-r1-2-billion-on-litigation/> (Accessed 13.10.2020).
4. **Malherbe J.** Counting the cost: The consequences of increased medical malpractice litigation in South Africa. *S Afr Med.* 2013; 103(2):83-84.
5. **Meel BL.** Pre-hospital and hospital traumatic deaths in former homeland of Transkei, South Africa. *J Clin Forensic Med.* 2004; 11(1):6-11.
6. **Kohn KT, Corrigan JM, Donaldson SM.** *To err is human: Building a safer health care system.* Washington, DC: National Academy Press. 1999. <http://www.csen.com/err.pdf> (Accessed 15.10.2020).
7. **Naidoo D.** Traumatic brain injury: The South African landscape. *SAMJ.* 2013; 103(9):1-5.
8. **Westaway A.** Rural poverty in the Eastern Cape Province: Legacy of apartheid or consequence of contemporary segregationism? *Development Southern Africa.* 2012; 29(1):115-125.
9. **Madiba TE, Naidoo P, Naidoo SR.** The amended legislation on procedure-related deaths -an advance in patient care? *S Afr Med J.* 2011; 101(4):234-6.
10. **Seggie J.** The 'boom' in medical malpractice claims patients could be the losers. *SAMJ.* 103(7):433.
11. **Matsuo K, Akutsu N, Otsuka K, Yamamoto K, Kawamura A, Nagashima T.** The efficacy and safety of burr-hole craniotomy without continuous drainage for chronic hematoma and subdural hygroma in children under 2 years of age. *Childs Nerv Syst.* 2016 (Epub ahead of print).
12. **Cheung PS, Lam JM, Yeung JH, Graham CA, Rainer TH.** Outcome of traumatic extradural haematoma in Hong Kong. *Injury.* 2007; 38(1):76-80.
13. **Negligence per se-the Doctrine of Res Ipsa Loquitur.** <http://www.healthlibrary.com/reading/lawpart2.html> (accessed 18.10.2020).
14. **Patel B.** Medical negligence and res ipsa loquitur in South Africa. *SAJBL.* 2008; 1(2); 57-60.
15. **The Constitution of the Republic of South Africa. Act No.108 of 1996.** www.info.gov.za/documents/constitution/index.htm (Accessed 18.10.2020).
16. **Lim LW, Molchanov VI, Volkodav OV.** Iatrogenic traumatic brain injury: Penetration of Kirschner's knitting needle into the middle cranial cavity. *J Craniofacial Surg.* 2007; 18(3):674-9.
17. **Howarth G, Brown S, Whitehouse S.** The importance of comprehensive protection in today's health care environment. *SAMJ.* 2013; 103(7):453-454.