

Management of Lysol Burn in Tertiary care Hospital: Our Experience

Yadunand Sriram¹, Ravi Kumar Chittoria², Barath Kumar Singh P³

How to cite this article:

Yadunand Sriram, Ravi Kumar Chittoria, Barath Kumar Singh P/Management of Lysol Burn in Tertiary care Hospital: Our Experience/RFP J ENT Allied Sci 2023;8(1):21-25.

ABSTRACT

Lysol is a derivative of phenol and is alkaline in nature. Lysol produces liquefactive necrosis after contact with skin by producing protein denaturation and saponification of fats. In this article we are sharing our experience of managing a case of Lysol burns with various regenerative therapies.

Keywords: Lysol burn; Management; Alkali burns; Face.

INTRODUCTION

Phenol (carbolic acid) is one of the antiseptic agents. Currently it is used as a disinfectant, chemical intermediate and nail cauterizer. Phenol is a general protoplasmic poison (denatured protein) with corrosive local effects. Phenol derivatives are less toxic than pure phenol. The lethal dose is between 3 to 30 g, but may be as little as 1 g. Lysol is a derivative of phenol with 50% solution of cresol (3-methyl phenol) in saponified vegetable oil. It is commonly used as a disinfectant or toilet cleaner. It has toxicity both in ingestion as well as topical exposure.¹ In this case report, we share

our experience of managing the Lysol burns in our patient.

MATERIALS AND METHODS

This study was conducted in the Department of Plastic Surgery in a tertiary care center in South India after obtaining the departmental ethical committee approval. Informed written consent was taken from the patient. 23-year-old female Patient had alkali burn injury when accidental splash of disinfectant in restroom wherein she sustained injuries to face, eyes and chest. (Fig. 1)



Fig. 1: Alkali Chemical burns at presentation

Author Affiliation: ¹Junior Resident, Department of Plastic,

²Professor, Department of Plastic Surgery & Telemedicine,

³Senior Resident, Department of Plastic, Jawaharlal Institute of Postgraduate Medical Education and Research, Pondicherry 605006, India.

Corresponding Author: Ravi Kumar Chittoria, Professor, Department of Plastic Surgery & Telemedicine, Jawaharlal Institute of Postgraduate Medical Education and Research, Pondicherry 605006, India.

E-mail: drchittoria@yahoo.com

Received on: 00.00.2023

Accepted on: 00.00.2023

Patient was admitted with the above symptoms and managed according to WHO burn protocol. She underwent Wound debridement and hydrotherapy. The wounds were managed with

Regenerative therapies like collagen scaffold application, feracrylum, , Low Level Laser Therapy Autologous Platelet Rich Plasma, Regenerative Scaffold, Negative Pressure wound therapy (Fig. 2-7).

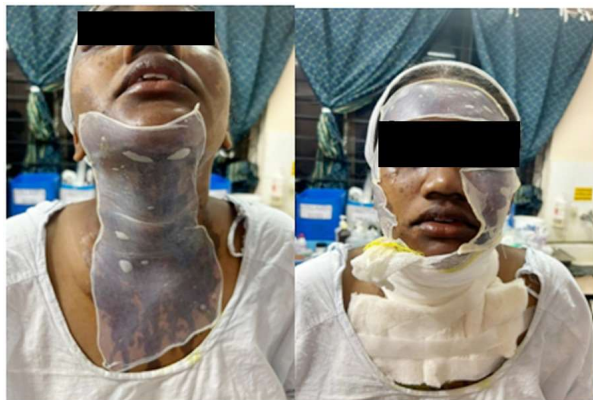

Fig. 2: Collagen Application

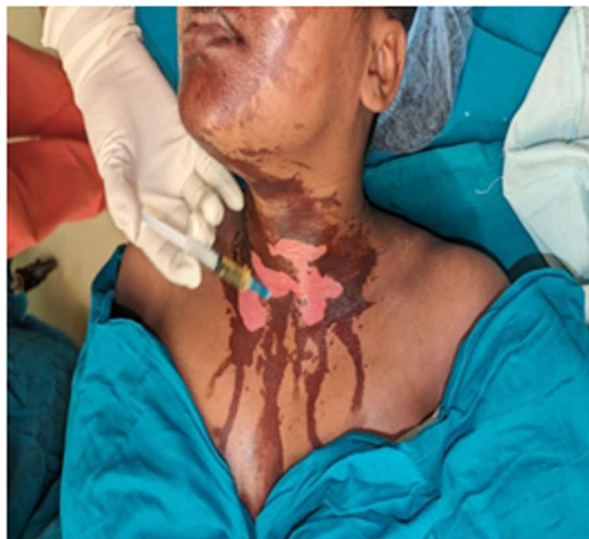

Fig. 5: Autologous platelet rich plasma therapy

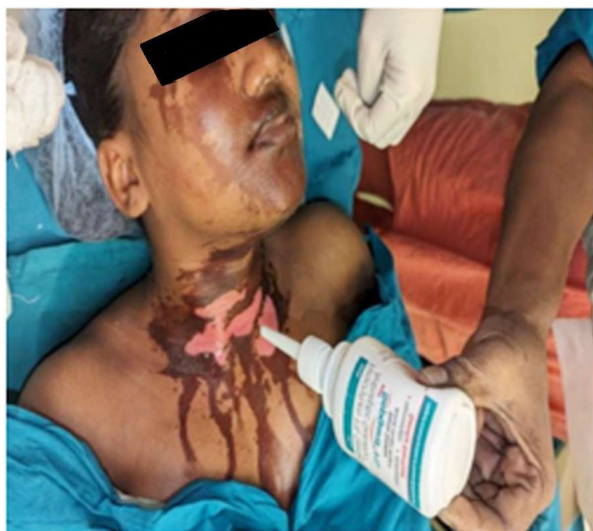

Fig. 3: Feracrylum 1% in Burn wounds

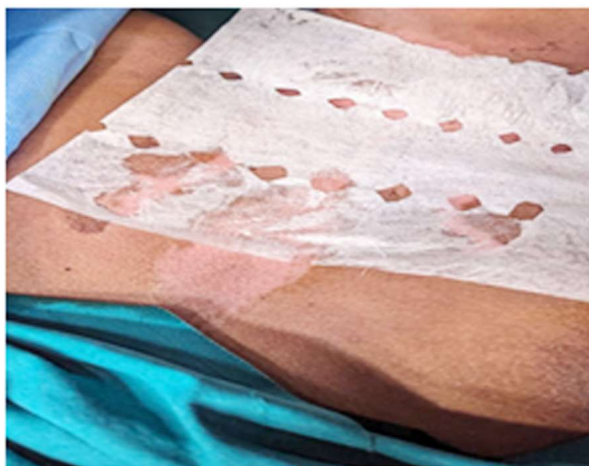


Fig. 6: Collagen application

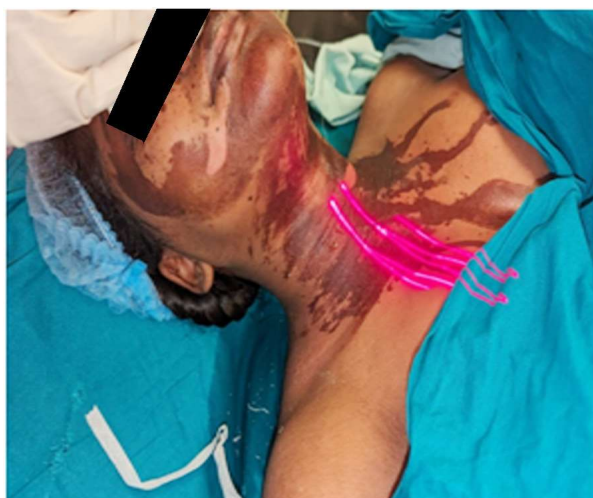

Fig. 4: Low level laser therapy for the burn wound

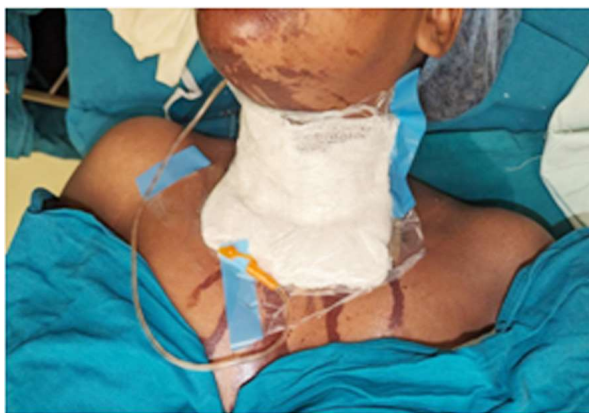

Fig. 7: Negative Pressure Wound Therapy

Once wound showed promising signs of healing and epithelization was complete, we applied Silicone gel and silicon sheet (Fig. 8 and 9) over the healed wound to prevent the abnormal scarring. We

also used low-level laser therapy and autologous platelet rich plasma for scar management. (Fig. 10 and 11)

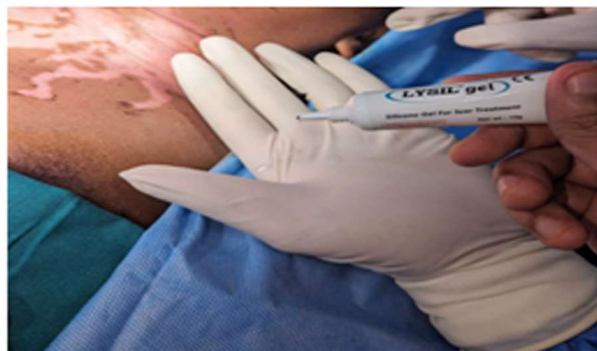

Fig. 8: Silicone gel application for scar

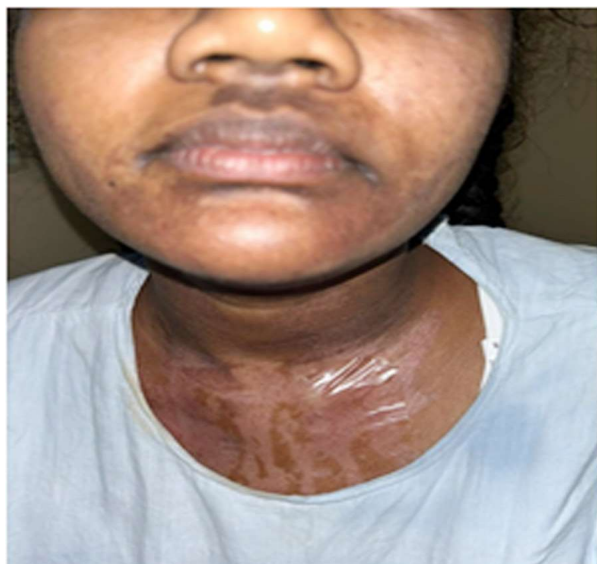

Fig. 9: Silicone sheet application

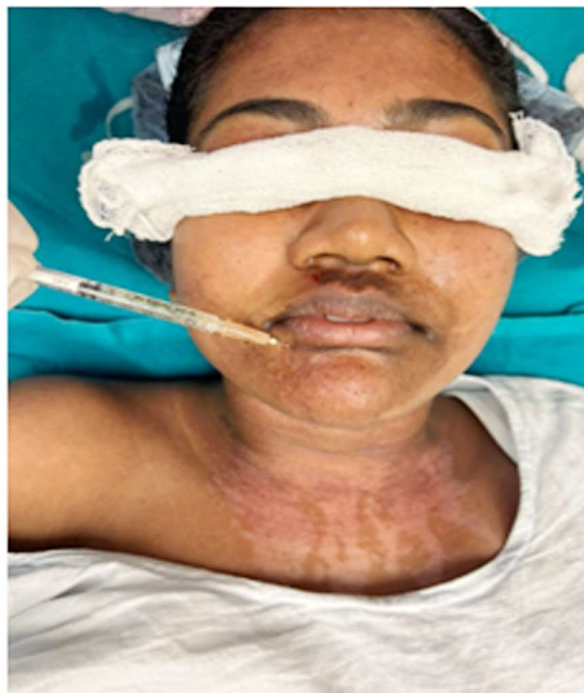

Fig. 11: Autologous platelet rich plasma for scar

RESULTS

Patient burn wounds healed and there was minimal abnormal scarring and no hypertrophic scarring at the time of discharge. (Fig. 12). Vancouver Scar Scale - 5/13 at the time of discharge.

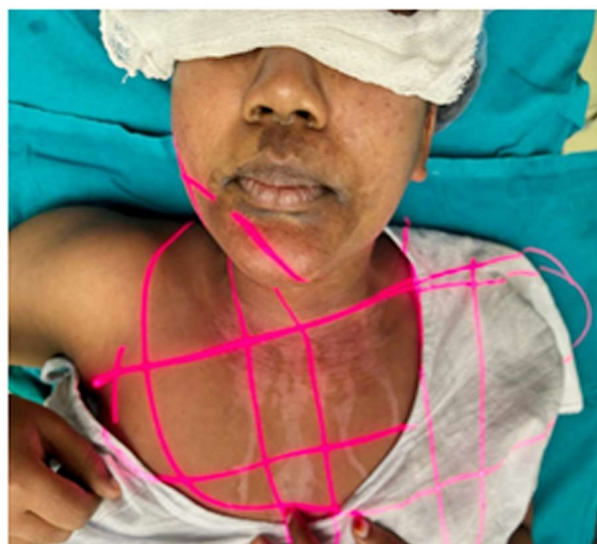

Fig. 10: Low-Level laser therapy for scar

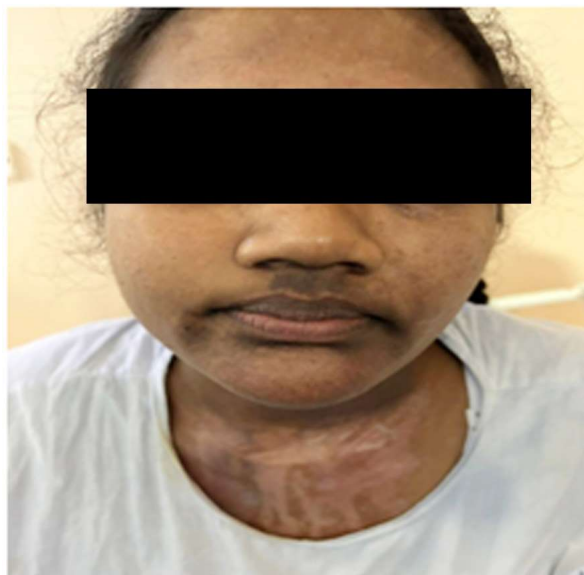

Fig. 12: Healed burn wound at discharge

DISCUSSION

Lysol is derivative of phenol and is used frequently in industries and as disinfectants in households. Instead of causing a hyperthermic injury, most chemical agents harm the skin by causing a chemical reaction. Even though some chemicals cause significant heat when they come into contact with water due to an exothermic reaction, the majority of skin damage is caused by chemicals due to their direct chemical alterations on the skin. Depending on the agent acids, alkalis, corrosives, oxidizing and reducing agents, desiccants, vesicants, and protoplasmic poisons different chemical changes may occur. Dermal exposure produces lesions which are initially painless white patches and later turn erythematous and finally brown. Phenol produces mucosal burns and coagulum. They cause eye irritation and corneal damage. When ingested, it causes extensive local corrosions, pain, nausea, vomiting, sweating, and diarrhea. Severe gastrointestinal burns are uncommon and strictures are rare. Inhalation produces respiratory tract irritation and pneumonia. Systemic manifestations develop after 5 to 30 minutes post ingestion or post dermal application, and may produce nausea, vomiting, lethargy or coma, hypotension, tachycardia or bradycardia, dysrhythmias, seizures, acidosis, hemolysis, methemoglobinemia, and shock.² The degree of skin degradation is mostly determined by the toxic agent's concentration and length of contact.³ Lysol is alkaline in nature and produces liquefactive necrosis on contact with skin causing protein denaturation and saponification of fats.⁴ Autologous platelet rich plasma is an upcoming and proven treatment modality for patients with burn injuries wherein concentrated platelet preparations are used which enhance body regenerative process. Several kinds of bioactive mediators, including immunological mediators, clotting factors, chemokines, integral membrane proteins, adhesion proteins, growth factors, and clotting factors, are stored and prepared to react to tissue injury inside the cytoplasmic granules of platelets. In wounds treated with PRP, the bioactive mediators have a favorable impact on cellular development, proliferation, differentiation, and re-epithelialization by promoting angiogenesis, mitogenesis, and controlling the endogenous inflammatory process.⁵

The advantage of allogeneic PRP is that it can be obtained from willing blood donors, and its derivatives can be used right away without the

requirement for clinicians to get a patient sample. In some clinical circumstances, such as those involving acute burns when patients may be fluid depleted and thrombocytopenic, this may be helpful. Other conditions that preclude the creation of PRP include hemophilia, sepsis, or infection; related contraindications include the use of NSAIDs or corticosteroids, tobacco usage, malignancies, and anemia.

LLLT, which can trigger photochemical reactions in tissue and cells, is sometimes referred to as biological stimulation or photobiological regulation. Previous research has demonstrated that LLLT affects the photoreceptors on mitochondria, stimulates the electron transport chain of produced energy, enhances mitochondrial respiration, and boosts the synthesis of adenosine triphosphate (ATP). As a result, LLLT has the ability to change the cellular redox state and to trigger the activation of signaling pathways that drive transcription factors involved in proliferation, tissue repair, and regeneration.⁶

The various dressings and tissue-engineered constructions used in burn therapy depend heavily on biomaterials. The major goal of employing them is to mimic the skin's ECM, which is composed of laminin, elastin, collagen, and proteoglycans. Laminin gives the skin strength, while proteoglycans give it moisture and viscosity. Biomaterials of diverse origins are employed in skin grafts and substitutes, and the decision made during scaffold manufacturing is crucial because it can affect in situ regeneration. These materials' characteristics control cell behavior and facilitate the development of new tissue. Biodegradability, momentary mechanical support, and permeability are the primary needs. Scaffolds can be either with or without cells, and the latter can be further broken down into dermal, epidermal, and epidermal dermal composites depending on the methodology.⁷ According to theory, negative pressure might generate an interstitial gradient shift that can reduce oedema and, as a side effect, promote cutaneous perfusion, facilitating the evacuation of blood or serous fluid. Additionally, it is hypothesized that NPWT's capacity to generate a mechanical stress or force that directly influences cellular activity, particularly the growth of new blood vessels, may help slow the advancement of burn wounds. Additionally, it may be desirable to maintain a wet environment that offers ideal circumstances for epithelialization and prevents tissue desiccation.⁸

The skin surface temperature of hypertrophic

burn scars under SGS is increased by 1.7°C, and temperature increases of this magnitude can significantly increase collagenase activity and could affect scarring. As a result, it is possible that an increase in skin surface temperature is involved in the mechanism of action of silicone based products for scar management. Because it has been suggested that the negative static electric field produced by friction between SGS and the skin may cause collagen realignment and lead to the involution of scars, the development of a static electric field may also be implicated.⁹

The way feracrylum works is by building water insoluble multi-complexes with different proteins, including those found in blood. The hemostatic effect of feracrylum is given through the creation of a synthetic complex on the wound surface that consists of its adduct with plasma proteins, primarily albumin. The in-vitro mixture of feracrylum and serum albumin results in a substantial rubbery clot. The feracrylum albumin combination degrades over time like all other biodegradable polymers. After that, these subunits are ejected. The benefit of feracrylum is that it combines antibacterial activity with little local toxicity or irritation, making it useful in preventing acute, chronic, and hospital infections, especially in post-operative wounds, and facilitating wound healing.¹⁰

CONCLUSION

With advent of newer technologies, treatment of chemical burn wounds has been much more streamlined and produce better results in patients. In our experience we have seen better wound healing in patient with chemical burns with minimal scarring. However large randomized control trials are necessary to establish association between the same.

Conflicts of interest: None

Authors' contributions: All authors made contributions to the article

Availability of data and materials: Not applicable.

Financial support and sponsorship: None

Consent for publication: Not applicable

REFERENCES

1. Todorović V. Akutna trovanja fenolom [Acute phenol poisoning]. Med Pregl. 2003;56 Suppl 1:37-41.
2. Liu YY, Lu CC, Perng RP. Acute respiratory distress syndrome following cutaneous exposure to Lysol: a case report. Zhonghua Yi Xue Za Zhi (Taipei). 1999 Dec;62(12):901-6.
3. Eldad A, Weinberg A, Breiterman S, et al. Early nonsurgical removal of chemically injured tissue enhances wound healing in partial thickness burns. Burns 1998; 24:166.
4. Ramakrishnan KM, Mathivanan T, Jayaraman V, Babu M, Shankar J. Current scenario in chemical burns in a developing country: Chennai, India. Annals of burns and fire disasters. 2012 Mar 3;25(1):8.
5. Akbarzadeh S, McKenzie MB, Rahman MM, Cleland H. Allogeneic platelet-rich plasma: is it safe and effective for wound repair? European Surgical Research. 2021 May 18;62(1):1-9.
6. Lu W, Lu K, Peng Y, Chen P, Bian W, Yu W. The efficacy of low-level laser therapy for the healing of second-degree burn wounds on lower limbs of glucocorticoid-dependent patients. Lasers in Medical Science. 2023 Aug 15;38(1):186.
7. Shpichka A, Butnaru D, Bezrukov EA, Sukhanov RB, Atala A, Burdukovskii V, Zhang Y, Timashev P. Skin tissue regeneration for burn injury. Stem cell research & therapy. 2019 Dec; 10:1-6.
8. Dumville JC, Munson C, Christie J. Negative pressure wound therapy for partial thickness burns. Cochrane Database of Systematic Reviews. 2014(12).
9. Mustoe TA. Evolution of silicone therapy and mechanism of action in scar management. Aesthetic plastic surgery. 2008 Jan;32:82-92.
10. Moenadjat Y, Setiabudy R, Astrawinata DA, Gumay S. The safety and efficacy of feracrylum as compared to silver sulfadiazine in the management of deep partial thickness burn: A clinical study report. Medical Journal of Indonesia. 2008 Nov 1;17(4):259-71.