Case Report

Indian Journal of Forensic Medicine and Pathology
Volume 12 Number 4, October - December 2019
DOI: http://dx.doi.org/10.21088/ijfmp.0974.3383.12419.7

Malignant Mixed Tumor of Soft Tissue: A Case Report

V Rajalakshmi[1], A Sajitha Begum[2], Hemalatha Ganapathi[3], Mary Lilly[4]

Abstract

Mixed Tumor of soft tissue are not so rare but mostly under recognised Tumors. The mixed Tumor and myoepithelioma of soft tissue are ends of a spectrum. There are only less than two hundred cases reported in literature. We report a case of Malignant mixed Tumor of soft tissue in a *47 years* old male. The excised specimen revealed a heterogenous neoplasm with rounded, plasmacytoid to spindle shaped cells, with areas of tubular differentiation in a chondromyxoid, hyalinised stroma with metaplastic bone. Cytological criteria of atypia, nuclear pleomorphism and Tumor giant cells favoured malignancy. Immuno Histochemistry confirmed the diagnosis. We report a case of Malignant mixed Tumor of soft tissue.

Keywords: Mixed Tumors; Malignant; Myoepithelioma; Soft tissue.

How to cite this article:
V Rajalakshmi, A Sajitha Begum, Hemalatha Ganapathi *et al.* Malignant Mixed Tumor of Soft Tissue: A Case Report. Indian J Forensic Med Pathol. 2019;12(4):321-324.

Introduction

Mixed Tumors of Soft Tissue (MXT-ST) and Myoepitheliomas of SoftT (ME–ST) are often under recognised. Both are similar to their counterparts in salivary glands and skin showing heterogenous microscopic appearance with round to spindle cells, plasmacytoid cells, eosinophilic to clear cytoplasm, chondromyxoid stroma with metaplastic bone. MXT–ST differs from ME–ST by ductular differentiation in the former.[1,2] Unlike their salivary gland counterparts where infiltration predicts malignancy infiltrative margins in MXT–ST and ME–ST do not correlate with malignancy.[3] Cytological atypia only is the predictor of malignancy.[3]

Authors Affiliation: [1]Professor, [2]Postgraduate, [3]Professor and Head, [4]Professor, Department of Pathology, Sree Balaji Medical College and Hospital, Chennai, Tamil Nadu 600044, India.

Corresponding Author: V Rajalakshmi, Professor, Department of Pathology, Sree Balaji Medical College and Hospital, Chennai, Tamil Nadu 600044, India.

E-mail: raji_path@rediffmail.com

Received on 27.09.2019, **Accepted on** 02.11.2019

© Red Flower Publication Pvt. Ltd.

Case History

A *47-years*-old male presented with a gradually progressive swelling in the right gluteal region of *ten years* duration, with sudden increase in size with pain since one month. On examination, circumscribed, smooth swelling, firm to hard in consistency in the right gluteal region near the cleft measuring *6×6 cm* with skin stretched over the swelling, (**Fig. 1**).

Fig. 1: Swelling *6x6 cms*-right gluteal region

MRI showed–A lobulated T2 hyperintense solid mass *6×3.5 cm* with eccentric hemosiderin deposit and surrounding soft tissue edema in the

subcutaneous plane of right medial gluteal region, (**Fig. 2**). FNAC of the lesion showed features consistent with a round cell neoplasm with a provisional clinical diagnosis of sebaceous cyst wide local excision was done.

Gross

Skin covered soft tissue mass measuring *5x4 cms*, *5x3.5 cms*. c/s was yellowish white with glistening areas, foci of hemorrhage and cystic areas with gritty foci, (**Fig. 3**).

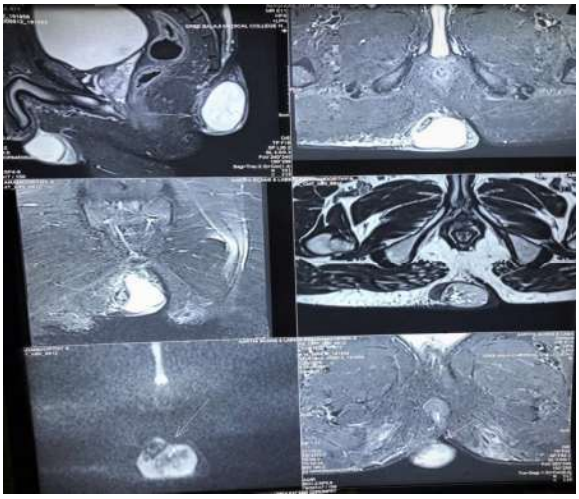

Fig. 2: MRI T2 hyperintense solid mass in gluteal region

Fig. 3: Skin attached soft tissue mass

Microscopy

Structure of skin with subcutis and deeper tissue showing a poorly circumscribed neoplasm arranged in lobules, nests and fascicles, occasional foci showing ductular differentiation with chondromyxoid, hyalinised stroma and metaplastic bone, (**Fig. 4**) & (**Fig. 5**). The cells are spindle to round, plasmacytoid with eosinophilic to clear cytoplasm. (**Fig. 6**) & (**Fig. 7**). There were nuclear atypia, pleomorpism and Tumor giant cells, (**Fig. 7**) & (**Fig. 8**). Only occasional mitosis seen. With the above features in view of the ductular differentiation and atypia the diagnosis of Malignant MXT-ST (MMXT-ST) was made. IHC P63, Vimentin and S100 were strongly positive, (**Fig. 9**) & (**Fig. 10**) CK focally positive, (**Fig. 11**) Ki 67 high index. GFAP negative. The above IHC confirming the diagnosis of MMXT-ST.

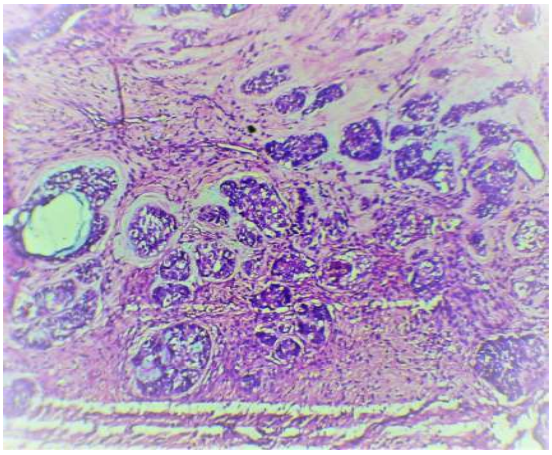

Fig. 4: H & E X100 Tubular differentiation of the epithelial cell

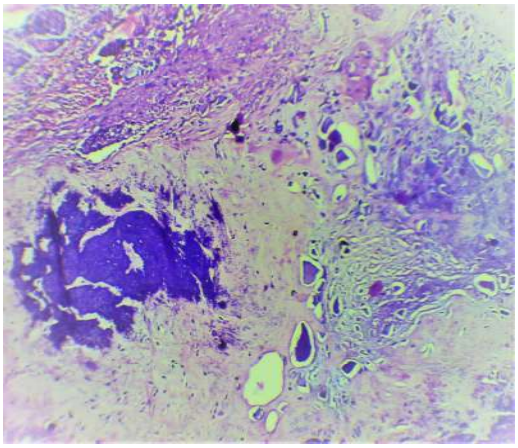

Fig. 5: H & E X100 metaplastic bone with calcification

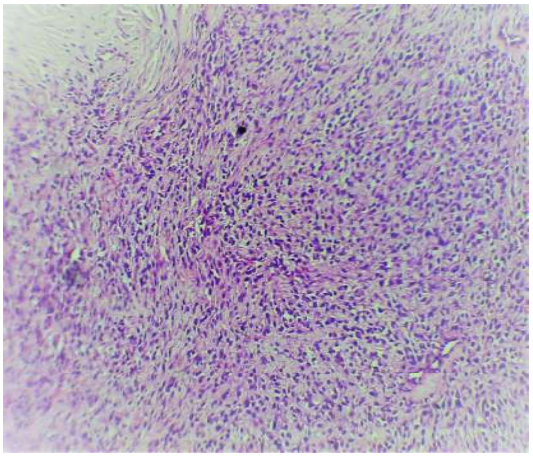

Fig. 6: H & E X100 Fasicles of spindle shaped cells

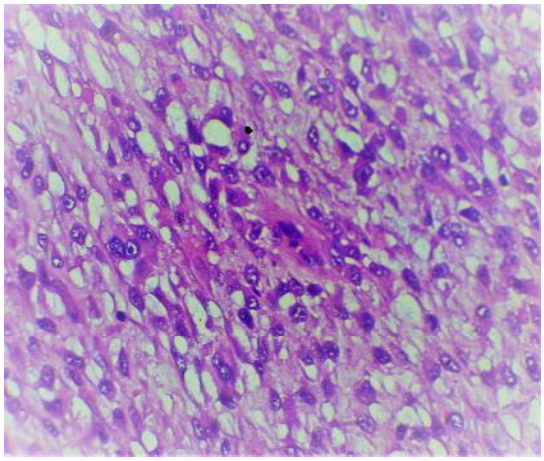

Fig. 7: H & E X400 Round to plasmacytoid cells with eosinophilic to clear cytoplasm

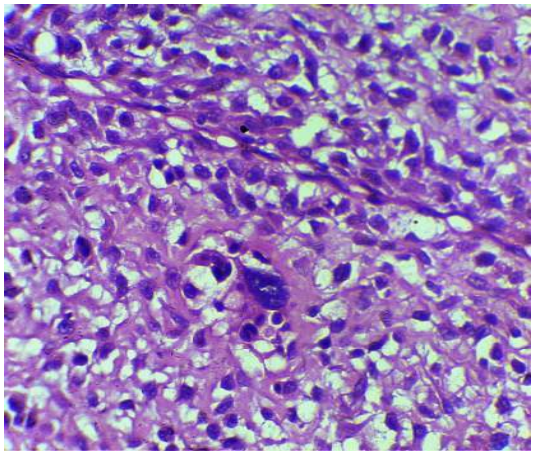

Fig. 8: H & E 400 Round cells with clear cytoplasm with atypia

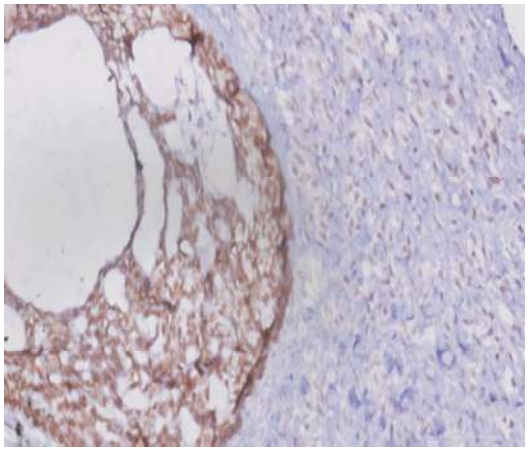

Fig. 9: IHC X400 P63 Positive

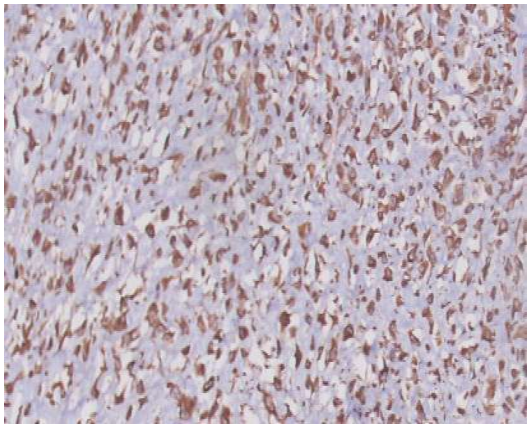

Fig. 10: IHC X400 imaging S100 Positive

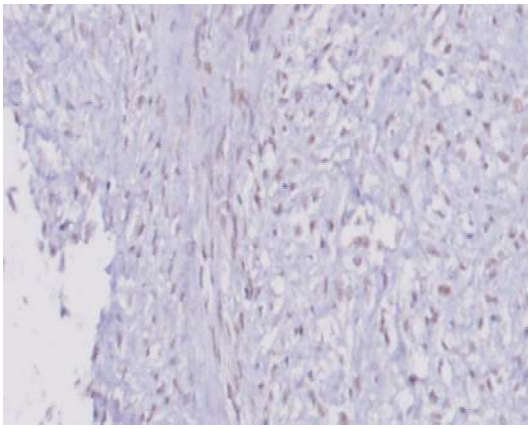

Fig. 11: IHC X400 CK focal Positivity

Discussion

MXT–ST and ME–ST are more often under recognized and there are only less than 150 cases reported in literature.[1,2] Awareness and Immuno histochemical studies have resulted in the increased diagnosis of these Tumors. Hornic *et al*.[1] in their paper have reviewed 101 cases of ME–ST ansd MXT–ST and evaluated the criteria for diagnosis and malignancy. The mean age of

occurrence of ME–ST and MXT–ST *38 years* with a range of *3–83 years* with equal gender predilection.[2] Tumor size ranged from *0.7* to *20 cms*. The most common sites being limb girdle, head and neck and trunk in descending order.[1,2] In the present case, age is *47 years*, the size of the Tumor is also with in the range of other cases reported and the site also is in the gluteal region.[4] MXT–ST and ME–ST have heterogenous histology with epithelial and myoepithelial cells with round, plamacytoid to spindle shaped cells and chondromyxoid, mucoid and hyalinised stroma with osseous metaplasia. Ductal differentiation is the hallmark of MXT–ST to differentiate MXT–ST from ME–ST.

The biological behavior of both MXT–ST and ME–ST is benign. However, 20% of these Tumor recur and metastasize. The cytological criteria for malignancy in both MXT–ST and ME–ST are atypia, nuclear pleomorphism.[1,2] Unlike in their salivary gland counterparts where infiltration is a predictor of recurrence and metastasis nearly in most of the ME–ST and MXT–ST the infiltration do not correlate with their clinical behavior.[3] Tumors with benign cytomorphology with mild cytologic atypia are ME–ST/MXT–ST. Tumors with moderate to severe atypia are classified as MMXT-ST Myoepithilial carcinoma of soft tissue (MEC–ST).[3,5]

ME–ST and MXT-STare positive for S100, Calponin and cytokeratin. 50% show positivity for GFAP. In our case P63, S100, Vimentin are strongly positive. Cytokeratin focally positive. Ki 67 high index. MXT–ST has to be differentiated from Extra Skeletal Mesenchymal Chondrosarcoma (ESMCS) and Ossifying Fibromyxoid Tumor (OFMT). ESMCS has a nodular growth pattern with interlacing fascicles of spindle shaped cells lacking intratumoral heterogeneity in contrast to MXT–ST and ME-ST which has reticular and solid areas.[5] ESMCS show only rare positivity for epithelial and myogenic markers. In our case, epithelial and myoepithelial markers are positive.[4]

OFMT is a lobulated proliferation of pale staining ovoid to round cells in cords and nests set in a variably myxoid or hyalinised stroma with rare metaplastic bone with S100 and desmin positivity. GFAP and Keratin are rarely positive. Our case is positive for cytokeratin.The mainstay of treatment for both benign and malignant ME–ST and MXT–ST is complete surgical excision with clear margins.

Conclusion

MXT–ST and ME–ST are not rare and awareness will increase their recognition. Most ME–ST and MT-ST are benign but 20% of them have unpredictable risk for recurrence and metastasis. MXT–ST and ME–ST with cytological atypia are clinically malignant. This case is reported to highlight the diagnostic criteria of the presence of ductular differentiation in MXT–ST differentiating from ME–ST and to emphasise that cytological atypia is the predictor of malignancy.

References

1. Hornick JL, Fletcher CD. Myoepithelial tumors of soft tissue: A clinicopathologic and immunohistochemical study of 101 cases with evaluation of prognostic parameters. Am J Surg Pathol. 2003;27:1183–96.
2. Kilpatrick SE, Hitchkock MG, Kraus MD, *et al*. Mixed tumors and myoepitheliomas of soft tissue. Am J Surg Pathol. 1997;21:13–22.
3. Ting F, Smith R, Davidson T, *et al*. Low grade myoepithelial carcinoma: A mini case series analysis including a case with sacral disease and a case with forearm disease. MOJ Clin Med Case Rep. 2015;2(1):18–22.
4. Pai MR, Naik R, Kamath R, *et al*. Myoepithelioma of soft tissue. Indian J Pathol Microbiol. 2009;52:100–02
5. Gleason BC, Fletcher CD. Myoepithelial carcinoma of soft tissue in children: An aggressive neoplasm analysed in a series of 29 cases. Am J Surg Pathol. 2007;31(12):1813–24.