

## Covid 19 Vaccine: Associated Henoch Schonlein Purpura in Young Adult Female

Vijay Kumar SS<sup>1</sup>, Shabbir Shekhli<sup>2</sup>

### How to cite this article:

Vijay Kumar SS, Shabbir Shekhli/Covid 19 Vaccine: Associated Henoch Schonlein Purpura in Young Adult Female/Indian J Emerg Med 2022;8(4):165-167.

**Author's Affiliation:** <sup>1</sup>Assistant Professor, Department of Emergency Medicine, K S Hegde Medical Academy Deralakatte, Mangalore 575018, Karnataka, India, <sup>2</sup>Assistant Professor, Department of Emergency Medicine, S Nijalingappa Medical College, Navanagar, Bagalkot 587102, Karnataka, India.

**Corresponding Author: Shabbir Shekhli**, Assistant Professor, Department of Emergency Medicine, S Nijalingappa Medical College, Navanagar, Bagalkot 587102, Karnataka, India.

**E-mail:** drshabbir9880033401@gmail.com

**Received on:** 04.08.2022

**Accepted on:** 02.09.2022

### Abstract

A 20 years female was brought to the Emergency Medicine Department with the complaint of abdominal pain and blood in the stool since morning. There was a history of the second dose of the covid 19 vaccine a month ago and fever the next day. On arrival, she was hemodynamically stable, bilateral purpuric rash was noticed on the bilateral lower limb extending to the thigh. Per abdominal examination was normal. The provisional diagnosis was made as HSP secondary to the covid 19 vaccination. She was treated symptomatically at the emergency room and admitted to the female ward, where she was treated with steroids and supportive care. She was discharged after five days when her symptoms were relieved. This case demonstrates HSP even though rare in an adult, can occur as a possible complication of the COVID-19 vaccine and emphasizes the importance of thorough history taking and clinical examination.

**Keywords:** Henoch-schoenleinpurpura; Vasculitis; Covid 19; Vaccine; Abdominal pain.

### BACKGROUND

Henoch-Schonleinpurpura (HSP) is a rare autoimmune disease causing small vessel vasculitis with multi-organ involvement. The exact cause of HSP is unknown but is associated with infections (bacterial, viral, parasitic), medications, and vaccination. These trigger the autoimmune mechanisms that lead to the formation of Antigen

and antibody complexes, mostly IgA which deposit in the small vessel walls resulting in inflammation and vasculitis.<sup>1</sup>

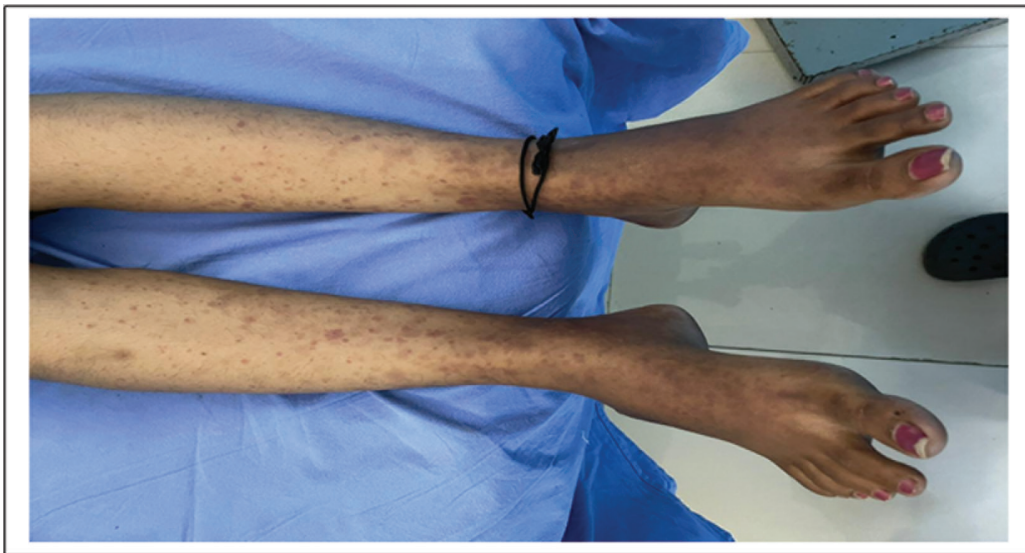
The literature revealed it is the most common cutaneous vasculitis in children comprising up to 90% of cases. The annual incidence ranged from 6.2 to 70.3 per million children in < 17 years of age with a slight male predominance. In adults, the incidence varies between 3.4-14.3 per million population.<sup>2</sup>

The COVID-19, classified as a pandemic by the World Health Organization, Which is working tirelessly with partners to develop, manufacture and deploy safe and effective vaccines. Most vaccines have common side effects like Swelling, pain at the injection site, fatigue, fever, chills, nausea, headache, myalgia, and joint pain.

HSP has previously been reported following immunization with various vaccines but an association with covid 19 is less and not well documented. This report aims to highlight the possible association between the COVID-19 vaccine and HSP in a healthy adult.

## CASE REPORT

We report the case of a 20 year female who came to the Emergency Department for sudden onset abdominal pain with blood in the stool since morning. She had no significant previous medical history, was not on any medication, her LMP was 15 days back and regular. She denied substance abuse. A month before she had received the second dose of the covid vaccine after which she developed a fever the next day. Ten days later of vaccination she started developing rash in both lower extremities, which was not itchy, and extending from the soles to the mid-thigh (Fig. 1).



On examination, she was hemodynamically stable, bilateral purpuric rash was noticed. Per abdominal examination was normal.

### Differential Diagnosis

colitis/Vasculitis/Skin disease.

### Investigations

Point of care Investigations was done, ECG showed Sinus Rhythm, GRBS of 115 mg%, USG abdomen showed minimal free fluid Hemoglobin 11.8 g%, Total Count of 7400, platelet 3.64 lakh, the peripheral smear was Neutrophilic Leukocytosis, serum creatine 0.9mg/dl, B urea 27 mg/dl, CRP 8 mg/L and ESR 40 mm, widal negative, VDRL negative and urine normal. Coagulation profile and liver function were normal. Serology was negative and a chest radiograph was normal.

### Provisional Diagnosis

Henoch-Schonleinpurpura in view of purpura, pain abdomen and normal routine investigations.

### Treatment

She was treated with injection Dexamethasone 8mg IV TID for 5 days and Injection Tranexemic acid 500 mg IV TID for 3 days, and also Injection Ceftriaxone 1gm IV BD with Injection Metronidazole 100 ml (500mg) IV TID for 5 days because of blood in the stool. Other supportive treatment includes Proton Pump Inhibitor, antiemetic, IV fluids, and Dermadew lotion BD for rash as a local application as per dermatology advice. Skin Biopsy was cancelled as there was a clinical improvement, she was later discharged with oral medications of Prednisolone 10 mg BD and gradually tapered over 15 days. She was reviewed after 15 days where she had shown significant improvement.

## DISCUSSION

HSP has been observed in the setting of numerous infections and as post Vaccination complications. To date, several cases of Different Vasculitis after covid 19 infection are described in the literature but to our knowledge, only a few cases of HSP were reported in India after covid vaccination.

The diagnosis of HSP is best determined by the presence of purpura or petechiae (usually palpable) with a lower limb predominance in addition to 1 or more of the following 4 findings:

- Abdominal pain (diffuse and colicky)
- Arthritis or arthralgia
- Renal involvement (proteinuria > 0.3 g in 24 hours, morning urine albumin or creatinine levels of > 30 µmol/L, or positive dipstick results for hematuria)
- Positive histopathology findings (leukocytoclastic vasculitis with predominant IgA deposits on skin biopsy or proliferative glomerulonephritis with predominant IgA deposit on kidney biopsy).

Adam M. Hines et al reported a case 40 year female who developed HSP after the second dose of covid vaccination. This case was reported in the United States.<sup>3</sup>

Dr. Stephanie R. Cohen, Dr. Lisa Prussick, et al reported a case of Leukocytoclasticvasculitis after the covid vaccine in a 46-year-old female after the first dose of covid vaccine.<sup>4</sup>

Bikash Ranjan Kar, Bhabani STP Singh et al recently reported small vessel vasculitis in a 46-year-old female after the first dose of vaccine with covaxin.<sup>5</sup>

In our case patient developed HSP after the second dose of the covid vaccine. It is important to acknowledge that we cannot be certain whether HSP was secondary to the COVID-19 vaccine or purely coincidental.

## CONCLUSION

HSP can occur as a result of infection or vaccination. Early recognition and an individualized treatment plan will aid in a good recovery. Corticosteroids can be used in the setting of abdominal pain, arthralgia, and purpura.

## REFERENCES

1. Sohagia, A., Gunturu, S., Tong, T. and Hertan, H., 2010. Henoch-Schonlein Purpura—A Case Report and Review of the Literature. *Gastroenterology Research and Practice*, 2010, pp.1-7.
2. Bluman, J. and Goldman, R., 2014. Henoch-Schönlein purpura in children. *Child Health Updates*, 60, pp.1007-1010.
3. Hines, A., Murphy, N., Mullin, C., Barillas, J. and Barrientos, J., 2021. Henoch-Schönlein purpura presenting post COVID-19 vaccination. *Vaccine*, 39(33), pp.4571-4572.
4. Cohen, S., Prussick, L., Kahn, J., Gao, D., Radfar, A. and Rosmarin, D., 2021. Leukocytoclastic vasculitis flare following the COVID-19 vaccine. *International Journal of Dermatology*, 60(8), pp.1032-1033.
5. Kar B, Singh B, Mohapatra L, Agrawal I. Cutaneous small-vessel vasculitis following COVID-19 vaccine. *Journal of Cosmetic Dermatology*. 2021.

