

## Brachial Artery Pseudoaneurysm Related Causally to Iatrogenic Coagulopathy in a Patient of Rheumatic Heart Disease with Prosthetic Mechanical Mitral Valve

O P Sanjeev<sup>1</sup>, Alka Verma<sup>2</sup>, Swati<sup>3</sup>, Tapas Kumar Singh<sup>4</sup>

### How to cite this article:

O P Sanjeev, Alka Verma, Swati, et. al./Brachial Artery Pseudoaneurysm related causally to Iatrogenic Coagulopathy in a patient of Rheumatic Heart Disease with Prosthetic Mechanical Mitral Valve/Indian J Emerg Med 2022;8(4):153-155.

**Author's Affiliation:** <sup>1,2</sup>Assistant Professor, <sup>3</sup>Senior Resident, Department of Emergency Medicine, <sup>4</sup>Assistant Professor, Department of Anesthesiology, Sanjay Gandhi Postgraduate Institute of Medical Sciences, Lucknow 226014, Uttar Pradesh, India.

**Corresponding Author:** Alka Verma, Associate Professor, Department of Emergency Medicine, Sanjay Gandhi Postgraduate Institute of Medical Sciences, Lucknow 226014, Uttar Pradesh, India.

**E-mail:** dralka.verma91@gmail.com

**Received on:** 02.09.2022

**Accepted on:** 04.10.2022

### Abstract

Brachial arterial pseudoaneurysms are rare arterial disorders. Usually, they are always related to myriad underlying pathologies ranging from atherosclerosis, and connective tissue disorders to traumatic injuries as trivial as iatrogenic arterial puncture during phlebotomy. We report a case of a 35-year-old female who presented with ecchymosis all over the distal half of the right arm and proximal forearm with pain and tenderness. She was taking an oral anticoagulant (acenocoumarol 2 mg daily) for thromboprophylaxis of the prosthetic mechanical mitral valve. On baseline investigations, her prothrombin time was more than 90 seconds and her INR was more than 7. On USG, muscular hematoma along with a small pseudoaneurysm measuring 20 mm x 16 mm was detected at mid-arm. She denied any trauma in past. She was conservatively managed with vitamin K, transfusion of fresh frozen plasma, analgesics, and topical medications. She was discharged from ED after 48 hours of observation.

**Keywords:** Pseudoaneurysm; Brachial Artery; Coagulopathy

### INTRODUCTION

An arterial pseudoaneurysm is a pulsatile hematoma due to bleeding into the surrounding soft tissue and communication between the rent artery and the hematoma. They are different from aneurysms as they lack components of the normal arterial wall. Trans arterial catheterization is the major cause of pseudoaneurysm affecting both

upper and lower limb arteries. The overall incidence of femoral artery pseudoaneurysm is up to 14% depending on various factors like age, gender, type of intervention, etc.<sup>1</sup> In Vietnam vascular registry, pseudoaneurysm of upper limbs shared 27% of all pseudoaneurysms.<sup>1</sup> However, the arm is an extremely rare site of pseudoaneurysm and only a few cases of brachial artery pseudoaneurysm have been reported.<sup>2,3</sup>

Spontaneous brachial arterial pseudoaneurysms are rare arterial disorders. Usually, they are always related to myriad underlying pathologies ranging from atherosclerosis, and connective tissue disorders to traumatic injuries as trivial as iatrogenic arterial puncture during phlebotomy. We report a case of spontaneous brachial artery pseudoaneurysm in a 35-year-old female who was on an oral anticoagulant for thromboprophylaxis of the prosthetic mitral valve.

## CASE

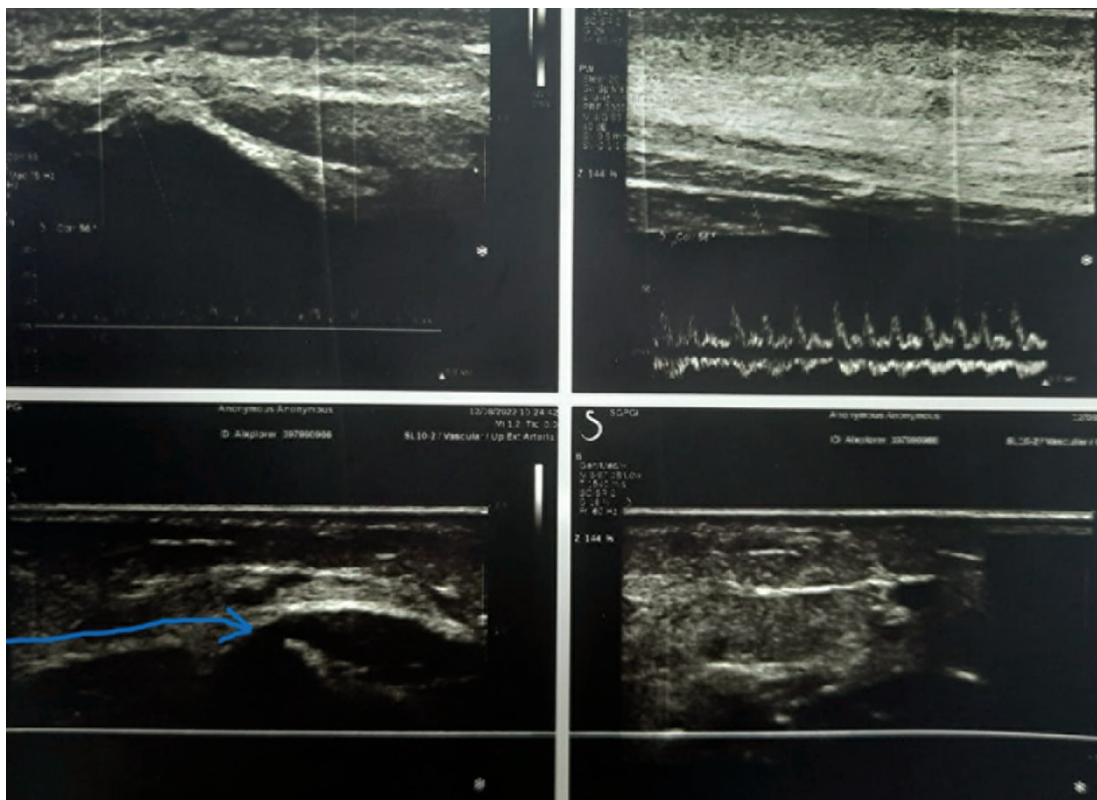
A 35-year-old-female presented to ED with ecchymosis all over the distal half of the right arm and proximal forearm with pain and tenderness. She had a history of rheumatic heart disease and her mitral valve was replaced with the prosthetic mechanical mitral valve 10 years back. She was taking an oral anticoagulant (acenocoumarol 2mg daily) for thromboprophylaxis of the prosthetic mechanical mitral valve. On baseline investigations, her prothrombin time was more than 90 seconds and her INR was more than 7. On USG, muscular hematoma along with a small pseudoaneurysm measuring 20mm x 16mm was detected (Fig. 1). Arterial rent was around 2 mm in size and on color doppler, there was a visible flow of blood from artery to pseudoaneurysm and vice versa.

Interestingly, she had a similar presentation one and a half months back but at a different site. She had ecchymosis, pain, and tenderness at the right lower limb located below the knee. She had similarly high prothrombin time and raised INR values. On lower limb USG and doppler studies, intramuscular hematoma of calf muscles without any vascular abnormality was revealed. So, there was a fair possibility of irregular and arbitrary intake of oral anticoagulant, however patient as well as the attenders denied the same.

She was conservatively managed with vitamin K, transfusion of fresh frozen plasma, analgesics, and topical medications. Her anticoagulant medication was put on hold. After optimization of anticoagulation, at an INR value of 2.86, she was discharged from ED after 48 hours of observation. She was suggested to re-initiate oral anticoagulant and keep testing for INR every week to strictly monitor the anticoagulation.

## DISCUSSION

Despite being the superficial course of the brachial artery in the arm, the pseudoaneurysm of this artery is relatively rare. Many underlying risk factors or causes have been attributed to these vascular pathologies.<sup>1,3,4,5</sup> Various risk factors described in the literature for brachial artery pseudoaneurysm



include trauma (bone fracture, joint dislocation, penetrating trauma, gunshot injuries, orthopaedic procedures with implants), malignancies (osteochondroma), and hematological disorders like haemophilia, etc. Iatrogenic causes are arterial catheterization, haemodialysis fistula, antiplatelet agents, peri-procedural anticoagulation, etc. However, low doses of oral anticoagulant for chronic prophylaxis of prosthetic valve thrombosis have not been described in the literature as a causative factor for Brachial artery pseudoaneurysm. Causative factors like infection and collagen vascular diseases have also been linked to it.

Point of care ultrasound (POCUS) can be extended to cover such vascular abnormalities. Communication between an artery and an aneurysm can be ascertained on color doppler scanning. During systole, blood flows from the artery to the pseudoaneurysm, and during diastole, the flow reverses from pseudoaneurysm to artery. Ultrasonography has 100% sensitivity and specificity for arterial pseudoaneurysms. However, CT angiography or MRI with contrast injection can be obtained for better detailing before surgical or percutaneous vascular intervention.

Therapeutic options for brachial artery pseudoaneurysm include surgical repair, ultrasound guided compression, ultrasound-guided thrombin injection, coil embolization, and endovascular repair using stent grafts. Primary surgical repair and interposition vein grafting especially with arterial defects is usually required for an arterial defect of more than 1 cm.<sup>1</sup> In our case, the arterial rent was small and did not require any surgical repair or vascular intervention. The patient was followed up after one month and her muscular hematoma resolved. Follow-up ultrasonography did not reveal any persistent pseudoaneurysm. The rent of the brachial artery might have sealed gradually by thrombus formation. Such patients need close follow-up for assessment of any intervention. If left untreated without close follow-

up, there are possibilities of myriad complications like infection, compartment syndrome, etc.

## CONCLUSION

This is the first case of a brachial artery pseudoaneurysm in a patient who was on chronic low dose anticoagulant therapy. In case of iatrogenic coagulopathy, ecchymosis and muscular hematomas can be obvious presentation, however, USG scanning of local artery must be performed to rule out pseudoaneurysms. Such patients need rapid correction of coagulopathy only to optimal level for thromboprophylaxis of prosthetic mitral valve.

## REFERENCES

1. Hadidi F A, Hadidy A M, Smady M M A et al. Spontaneous primary pseudo-aneurysm of brachial artery on an adult patient misdiagnosed for 8 years: Casereport. *Cor et Vasa*. 2014;56:e441-e444.
2. Paziienza K. A Rare Case of a Spontaneous Brachial Artery Aneurysm. *Journal for Vascular Ultrasound*. 2016;40(2):90-90.
3. Scotti C, Marone E, Brasca E L et al., Pseudoaneurysm overlying an osteochondroma: a noteworthy complication, *Journal of Orthopaedics and Traumatology* 11 (2010) 251-255.
4. G. Christopher G, Tze-Woei T, Nikhil T et al., Presentation of a brachial artery pseudoaneurysm after a supracondylar humerus fracture in a 6-year-old boy: a case report, *Journal of Pediatric Orthopedics* 30 (1) (2010) 57-59.
5. Gok E, Gokse O S, Alpagut U, Dayioglu E. Spontaneous brachial pseudo-aneurysm in a 12-year-old with kyphoscoliosis-type Ehlers Danlos syndrome. *European Journal of Vascular and Endovascular Surgery* 2012;44:482-484.

