

Acute Abdominal Presentation in Emergency and a Prodigious Diagnosis of Acute Epiploic Appendagitis: A Rare Case Report

Sayani Banerjee¹, Tehseen Quadri²

How to cite this article:

Sayani Banerjee, Tehseen Quadri/Acute Abdominal Presentation in Emergency and a Prodigious Diagnosis of Acute Epiploic Appendagitis: A Rare Case Report/Indian J Emerg Med 2023;9(2):83-88.

Abstract

Background: Appendices Epiploicae, also referred as Epiploic appendages, are 50-100 fat filled finger like projection from the serosal surface of large intestine. Epiploic Appendagitis is a self-limiting, benign disease process which results from the inflammation of these Appendices Epiplocae or thrombosis of the draining vein of Appendices Epiplocae.

Case Report: We report a case of 49 year old female, generally well, presented to the A & E with complaints of a painful lump in her left iliac fossa growing in size for last four weeks. She presented to us because of acute increase in size and pain, resulting in significant discomfort. Owing to her history of CIN-1 we arranged a CT abdomen and pelvis with contrast fearing some sinister underlying ongoing pathology causing her symptoms. But to our surprise Ct reported a underrated cause of her abdominal pain, Epiploic Appendagitis. We were surprised of her presentation as a hard abdominal lump which was quite unusual for EA to present as. We assume it was secondary to an extensive underlying local inflammatory reaction. Patient was reassured and treated with NSAID, antibiotics and follow up with surgery ambulatory care.

Conclusion: We authors are reporting this case of primary epiploic appendagitis because we think every emergency and primary care physicians should be aware of this very rare condition which might present to emergency as an acute abdominal presentation mimicking other common presentations like acute diverticulitis and acute appendicitis. Being aware of this condition is utmost important to diagnose it early and avoid more invasive surgical managements and unnecessary antibiotic usage.

Keywords: Epiploic Appendagitis; Acute Abdomen; Emergency.

Author's Affiliation: ¹Specialty Doctor, ²Consultant, Department of Accident & Emergency Medicine, Weston General Hospital, University Hospital Bristol & Weston, NHS Foundation Trust, Weston Super Mare, North Somerset, UK.

Corresponding Author: Sayani Banerjee, Specialty Doctor, Department of Accident & Emergency Medicine, Weston General Hospital, University Hospital Bristol & Weston, NHS Foundation Trust, Weston Super Mare, North Somerset, UK.

E-mail: sayani.dr@gmail.com

Received on: 03-02-2023

Accepted on: 21-02-2023

INTRODUCTION

Epiploic appendages, also referred to as Appendices epiploicae, are fat filled finger like projections originating from the serosal surface of large intestine, out pouching into the abdominal cavity. They are originating parallel to the outer layer of three longitudinal muscle bands of large intestine called taenia coli and in two rows,

anterior and posterior.¹ There are 50-100 epiploic appendages in an adult human.²

Historically, Epiploic Appendages were first described in 1543 by Vesalius. Virchow gave it a surgical significance in 1853, describing it as “loose bodies” or “peritoneal mice”, when it gets detached from the serosal surface of intestine and wander inside the peritoneum.^{3,4} In rare occasions, it can get reattach to another organ surface and then it is then called as “parasitized appendages epiploica”.⁵

Epiploic Appendagitis, first described by Lynn et al. in 1956, a rare cause of acute abdominal pain/presentation in Emergency Departments (ED). Primary appendagitis epiploica is a self-limiting disease process, resulting from inflammation of one or more epiploic appendage/s or rarely thrombosis of draining vein of a epiploic appendages. Secondary appendagitis epiploica is a resulting secondary inflammation of epiploic appendages which springs from a primary inflammation of an adjacent peritoneal structure, examples: appendicitis or diverticulitis or cancerous process.

Clinically it is often mimics more common causes of acute abdominal presentations in emergency departments, acute diverticulitis or acute appendicitis. It is a very rare diagnosis, often missed at first, because of lack of knowledge regarding this condition among emergency physicians and primary care physicians. Sometimes misdiagnosed as other common conditions, lead to unnecessary antibiotic usage, surgical interventions, and unwanted hospitalizations.

We will discuss this case of a minacious presentation of acute abdominal pain, which to our pleasant surprise, lead us to a very rare but amicable diagnosis of Epiploic Appendagitis.

CASE REPORT

49 year old female presented to the A&E with complaints of a painful lump in her left iliac fossa growing in size for last four weeks. She has consulted her GP already who arranged for an Ultrasound scan, still awaited. She presented to us in A&E as she noticed it increased in size significantly in last few days and pain became much worse. She denied any fever, weight loss, nausea, vomiting, loss of appetite, dizziness. No dysuria/ diarrhoea. She further denied any vaginal

discharge/ bleeding/ spotting/ dyspareunia. Only significant past medical history was, she was diagnosed as cervical intra epithelial neoplasia 1 and recent cervical smear 2 weeks back confirmed no progression of the disease.

On presentation:

She walked in ED. BP 136/76mmhg, PR-89/min, SpO₂-98% on Room Air, RR-19/min, Temperature-36.5°C. Chest: Bilateral (B/L) normal vesicular breath sounds (VBS). CVS= normal S1, S2 audible and no murmur. Abdomen: a hard, tender lump palpated in left iliac fossa, non-mobile and undefined lower edges, approx. 5x5cm size. Rest of the abdomen was soft and bowel sound was normal. We were surprised of her presentation as a hard abdominal lump which was quite unusual for EA to present as. We assume it was secondary to an extensive underlying local inflammatory reaction.

Urine dipstick and urine beta HCG both came back negative.

Her blood report showed raised WBC and CRP and normal renal and liver function tests.

Management:

At this point our main concern was a malignancy in background of the history of CIN-1. Other differentials we wanted to rule out were Diverticulitis/ diverticular abscess, ruptured ovarian cyst or ovarian torsion. Hence we decided to go ahead for a CT abdomen and pelvis with contrast, weighing risk of radiation exposure vs. missing a more sinister pathology undergoing. We discussed with the radiologist and in the background of her history radiologist agreed for the CT abdomen & pelvis too.

CT took quite some time to be reported as we expected in this scenario but what was reported was not something we could ever thought of. To all of our pleasant surprise, CT reported that there was an acute left iliac fossa (LIF) epiploic appendagitis of the sigmoid colon with target sign on the coronal MPR causing significant surrounding fat standing reaching the left inguinal canal with adjacent soft tissue swelling of the later and possible neighbouring collection of the left lateral rectus muscle measuring axillary 16 x 23 mm. No convincing hernia as shown in Figure 1.

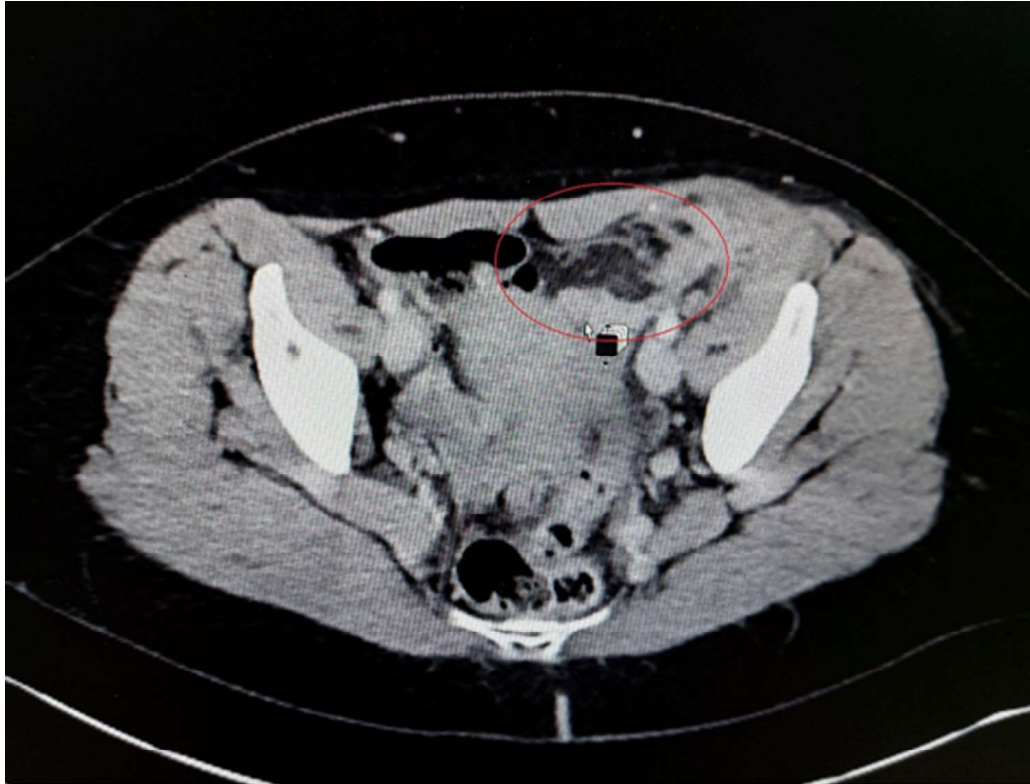


Fig. 1: Left Iliac Fossa Epiploic Appendagitis of Sigmoid Colon with Target Sign with significant surrounding soft tissue swelling suggestive of inflammation, extending to left inguinal canal.

Figure 1: Shows acute left iliac fossa (LIF) epiploic appendagitis of the sigmoid colon with target sign on the coronal MPR causing significant surrounding fat standing reaching the left inguinal canal with adjacent soft tissue swelling of the later and possible neighboring collection of the left lateral rectus muscle measuring axillary 16 x 23 mm.

We referred the patient for emergency review by surgeons. Patient was initially discharged with Non-Steroidal Anti-inflammatory Drug (NSAIDS) and Co-Amoxiclav with follow up in surgery ambulatory care unit. On follow up our patient's inflammatory markers were of rising trend. Hence, our patient was managed conservatively with escalated antibiotic coverage (covering gram positive, gram negative and anaerobes: to avoid complications and intra-abdominal sepsis) and oral non-steroidal anti-inflammatory drugs. Although oral anti-inflammatory drugs are recommended for four to seven days for pain, antibiotic is usually not recommended unless there is fear of complications.

DISCUSSION& LITERATURE REVIEW

Primary appendagitis epiploica is a rare, self-limiting inflammatory or ischaemic process

involving the epiploic appendages, which are fat filled finger like projections originating from the serosal surface of large intestine into the peritoneal cavity. An adult human body they are usually 50-100 in number, between 0.5 and 5 cm long, containing a vascular stalk (two arterioles and one venule) attaching it to the surface of the colon/ large intestine. Primary appendagitis epiploica is a disease presenting mostly between 2nd to 5th decades of life.² It is more common in obese women and one who recently lost weight, as these structures are larger in them, make them more prone to torsion.⁷

Common sites of epiploic appendages are: rectosigmoid junction: 57%, ileocaecal region: 26%, ascending colon: 9%, transverse colon: 6%, descending colon: 2%.⁹

Types of epiploic appendages: can be primary or secondary. Primary appendagitis epiploica is a self-limiting disease process, resulting from inflammation of one or more epiploic appendage/s or rarely thrombosis of draining vein of a epiploic appendages. Secondary appendagitis epiploica is a resulting secondary inflammation of epiploic appendages which springs from a primary inflammation of an adjacent peritoneal structure,

examples: appendicitis or diverticulitis or cancerous process.^{1,2}

Pathophysiology: It is believed that epiploic appendages provide the protection to the large intestine, being its cushion support, during peristalsis. It also responsive for intra peritoneal & intestinal immunity, fat storage and colonic absorption.⁴ Each epiploic appendage attaches to the colon surface via a narrow vascular stalk, containing two arterioles and one venule and relies upon them entirely for vascular supply and drainage. Being pedunculated and mobile structure it is prone to twisting which lead to ischaemia and venous thrombosis, and ultimately inflammation, infarction and necrosis of the draining epiploic appendage. It can sometime be associated with haemorrhage as well. Depending upon the degree and location of inflammation/ infarction and necrosis varies the clinical presentation, degree of abdominal pain, mimicking other common conditions.

Clinical Presentation: Primary appendicitis epiploica presents with non-specific, localized abdominal pain, non-radiating, sharp in nature, mostly in the lower abdomen, left lower abdomen greater than right lower abdomen, usually pain does not get aggravated by movements, without any guarding or rigidity or palpable mass.^{14,15} Nausea, vomiting, abdominal bloating etc. are non-specific symptoms associated.^{16,17,18} Inflammatory marker, whole blood count (WBC), neutrophil count and C-reactive protein (CRP) are seldom raised, when epiploic appendagitis is also related to fat necrosis and ischaemia.^{14,15,16,17,18}

Our patient although presented with a hard lump in the left lower abdomen, which not a common presentation of epiploic appendagitis. We were surprised of her presentation as a hard abdominal lump which was quite unusual for EA to present as. We assume it was secondary to an extensive underlying local inflammatory reaction. Over four weeks the lump was increased in size and became more painful, harder. Recently pain aggravated during movements, like walking, for last 2 days before her presentation to us in A&E, which is also unusual presenting symptoms of pain related to epiploic appendagitis. These feature related to underlying ischemia and necrosis, possibly intra-peritoneal fat necrosis and more advancing inflammatory process. Our though denied any fever, lethargy, loss of appetite, diarrhoea or vomiting etc. to us, which possibly rule out any ongoing intra-peritoneal infection or peritonitis.

Complications: *local adhesions leading bowel*

obstruction, secondary infection leading to local abscess formation, peritonitis, detachment lead to intra-peritoneal loose body formation.

Differential Diagnosis: Diverticulitis: if left sided, Acute appendicitis: if right-sided, Ovarian cyst, ectopic pregnancy: in female, Mesenteric panniculitis, Omental neoplasms, Omental infarction.^{19,20} We suspected an underlying cancerous intra-abdominal metastatic mass should be ruled out without any delay. Acute diverticulitis or a haemorrhagic ovarian cyst or ovarian torsion might be possible other diagnosis we thought to rule out in emergency in this case. During follow up visits, we suspected intra-abdominal localised peritonitis as her WBC & CRP were persistently raised, CRP almost doubled in initial follow up, in spite of treatment with non-steroidal anti-inflammatory drugs (NSAIDs) and oral prophylactic antibiotics, for which she had to be hospitalized antibiotic and analgesia. As her WBC & CRP gradually normalized she was discharged on oral antibiotic, NSAIDs and follow up in surgery outpatient.

Diagnosis: Epiploic appendagitis is primarily a CT/ Radiology diagnosis as this condition is rare and lacks any specific clinical feature to diagnose this condition. In CT, inflammation is mostly around the epiploic appendages and sparing the colonic wall and colonic diverticula, excluding acute diverticulitis or colitis.^{15,16} "Hyper attenuation ring sign" in CT scan is highly pathognomic of epiploic appendagitis. In non-enhanced CT an solitary fat density which originates from the large bowel wall signifies the inflamed or ischaemic epiploic appendages. A hyper-attenuation rim surrounding this solitary fat density is the inflamed visceral peritoneum, giving rise to "Hyper attenuation ring sign".^{19,20,23} "Fat stranding sign" is a more severe CT sign when inflammation spreads to the adjacent mesentery.^{2,6} "Central dot sign" signifies the thrombosis of the venule draining the inflamed epiploic appendage.^{1,15,19,20,23,24}

MANAGEMENT

Epiploic Appendagitis is a self limiting disease and conservative treatment with analgesics and NSAIDs is usually sufficient.

CONCLUSION

Epiploic Appendagitis is often a rare cause of acute abdominal pain presenting in emergency department or primary care. Presentation is

ambiguous. To diagnose epiploic appendagitis CT is the gold standard. Besides diagnosing this condition, CT abdomen also helps to rule out other possible differential diagnoses which may need more aggressive management. Treatment of epiploic appendagitis is simple, with NSAIDs only and hardly require any antibiotic for its management. We authors are reporting this case of primary epiploic appendagitis because we think every emergency and primary care physicians should be aware of this very rare condition which might present to emergency as an acute abdominal presentation mimicking other common presentations like acute diverticulitis and acute appendicitis. Being aware of this condition is utmost important to diagnose it early and avoid more invasive surgical managements and unnecessary antibiotic usage.

REFERENCES

1. Singh AK, Gervais DA, Hahn PF, Sagar P, Mueller PR, Novelline RA (2005) Acute epiploic Appendagitis and its mimics. *Radiographics* 25:1521-1534.
2. Almeida AT, Melão L, Viamonte B, Cunha R, Pereira JM (2009) Epiploic appendagitis: an entity frequently unknown to clinicians—diagnostic imaging, pitfalls, and look-alikes. *AJR Am J Roentgenol* 193:1243-1251.
3. Vesalius A: *De humanis corporis fabrica libri septem* [Title page: Andreae Vesalii Bruxellensis, scholae medicorum Patauinae professoris De humani corporis fabrica libri septem]. Basileae [Basel, Switzerland]: Ex officina Joannis Oporini. 1543-
4. Vinson DR: Epiploic appendagitis: a new diagnosis for the emergency physician. Two case reports and a review. *J Emerg Med*. 1999, 17 (5): 827-32. 10.1016/S0736-4679(99)00090-6.
5. Klatt EC :The Internet Pathology Laboratory for Medical Education. [<https://medlib.med.utah.edu/WebPath/>]
6. Pereira JM, Sirlin CB, Pinto PS, Jeffrey RB, Stella DL, Casola G (2004) Disproportionate fat stranding: a helpful CT sign in patients with acute abdominal pain. *Radiographics* 24:703-715.
7. Ghahremani GG, White EM, Hoff FL, Gore RM, Miller JW, Christ ML (1992) Appendices epiploicae of the colon: radiologic and pathologic features. *Radiographics* 12:59-77.
8. de Brito P, Gomez MA, Besson M, Scotto B, Hutten N, Alison D. Fréquence et épidémiologie descriptive de l'appendicite épiploïque primitive par l'exploration tomographique des douleurs abdominales de l'adulte [Frequency and epidemiology of primary epiploic appendagitis on CT in adults with abdominal pain]. *J Radiol*. 2008 Feb;89(2):235-43. French. PMID: 18354354.
9. Boardman J, Kaplan KJ, Hollcraft C et-al. Radiologic-pathologic conference of Keller Army Community Hospital at West Point, the United States Military Academy: torsion of the epiploic appendage. *AJR Am J Roentgenol*. 2003;180 (3): 748.
10. Schnedl WJ, Krause R, Tafeit E, Tillich M, Lipp RW, Wallner-Liebmann SJ (2011) Insights into epiploic appendagitis. *Nat Rev Gastroenterol Hepatol* 8:45-49.
11. Brady SC, Kliman MR :Torsion of the greater omentum or appendices epiploicae. *Can J Surg* 1979, 22(1):79-82.
12. Shamblin JR, Payne CL, Soileau MK :Infarction of an epiploic appendix. *South Med J* 1986, 79(3):374-5.
13. Sajjad Z, Sajjad N, Friedman M, Atlas SA :Primary epiploic appendagitis: an etiology of acute abdominal pain. *Conn Med* 2000, 64(11):655-7.
14. Ozdemir S, Gulpinar K, Leventoglu S et al (2010) Torsion of the primary epiploic appendagitis: a case series and review of the literature. *Am J Surg* 199:453-458.
15. Chen JH, Wu CC, Wu PH (2011) Epiploic appendagitis: an uncommon and easily misdiagnosed disease. *J Dig Dis* 12:448-452.
16. Saad J, Mustafa HA, Elسانی AM, Alharbi F, Alghamdi S (2014) Primary epiploic appendagitis: reconciling CT and clinical challenges. *Indian J Gastroenterol* 33:420-426.
17. Ortega-Cruz HD, Martinez-Souss J, Acosta-Pumarejo E, Toro DH (2015) Epiploic appendagitis, an uncommon cause of abdominal pain: a case series and review of the literature. *P R Health Sci J* 34:219-221.
18. Legome EL, Belton AL, Murray RE, Rao PM, Novelline RA (2002) Epiploic appendagitis: the emergency department presentation. *J Emerg Med* 22:9-13.
19. Ergelen R, Asadov R, Özdemir B, Tureli D, Demirbaş BT, Tuney D (2017) Computed tomography findings of primary epiploic appendagitis as an easily misdiagnosed entity: case series and review of literature. *Ulus Travma Acil Cerrahi Derg* 23:489-494.
20. Hwang JA, Kim SM, Song HJ et al (2013) Differential diagnosis of left-sided abdominal pain: primary epiploic appendagitis vs colonic diverticulitis. *World J Gastroenterol* 19:6842-6848.
21. Ghosh P, Strong C, Naugler W, Haghghi P,

- Carethers JM :Peritoneal mice implicated in intestinal obstruction: report of a case and review of the literature. *J Clin Gastroenterol* 2006, 40(5):427-30.
22. Bhandarwar AH, Desai VV, Gajbhiye RN, Deshraj BP :Acute retention of urine due to a loose peritoneal body. *Br J Urol* 1996, 78(6):951-2.
23. Rao PM, Rhea JT, Wittenberg J, Warshaw AL (1998) Misdiagnosis of primary epiploic appendagitis. *Am J Surg* 176:81-85.
24. Nadida D, Amal A, Ines M et al (2016) Acute epiploic appendagitis: radiologic and clinical features of 12 patients. *Int J Surg Case Rep* 28:219-222.
-
-