

## Drug-Resistant Long RP Tachycardia in the Emergency Department (ED): A Challenging Entity

Renaldo Pavrey<sup>1</sup>, Farzin Vajifdar<sup>2</sup>

### Author's Affiliation:

<sup>1</sup>Consultant, Department of Emergency Medicine, Sir H N Reliance Foundation Hospital, Mumbai 400004, India. <sup>2</sup>Specialist, Emergency Medicine, Doctors without Borders-India, Mumbai 400088, India.

### Corresponding Author:

**Renaldo Pavrey**, Consultant, Department of Emergency Medicine, Sir H N Reliance Foundation Hospital, Mumbai 400004, India.

Email: [renaldo.pavrey@gmail.com](mailto:renaldo.pavrey@gmail.com)

### How to cite this article:

Renaldo Pavrey, Farzin Vajifdar/ Drug-Resistant Long RP Tachycardia in the Emergency Department (ED): A Challenging Entity./ Indian J Emerg Med. 2021;7(2):25–28.

### Abstract

Long RP tachycardia is an uncommon form of supraventricular tachycardia (SVT) that exhibits a longer RP interval than PR interval on 12-lead electrocardiograms (ECG)<sup>1</sup>. The differential diagnosis of a long RP tachycardia includes the uncommon form of AV nodal reentrant tachycardia (AVNRT), the permanent form of reciprocating tachycardia (PJRT), and atrial tachycardia (AT). Drug responses vary markedly from patient to patient in uncommon SVT. Few small patient cohorts have been studied involving uncommon SVT whose attacks could not be adequately controlled by antiarrhythmic agents<sup>2</sup>. We present the case of a 47-year-old woman with stable long RP tachycardia refractory to first and second-line treatment in the Emergency Department, who rapidly destabilized to transient heart failure and hemodynamic compromise, ultimately requiring synchronized electrical cardioversion. In our report, we highlight the presentation of long RP tachycardia in the Emergency Department; its management in the acute setting and dealing with its ECG interpretational challenges.

Our reasons for highlighting this case are:

1. This is a relatively uncommon ECG presentation to the Emergency Department, which poses its own analytical difficulties.
2. The dynamic nature of drug-resistant tachyarrhythmia in the acute setting makes this case clinically relevant to the Emergency Physician.

**Keywords:** Supraventricular tachycardia; Long RP interval.

### Case presentation

A 47-year-old woman presented to our Emergency Department (ED) for evaluation of sudden-onset rapid heartbeat and intermittent shortness of breath over the past few hours.

The patient suffered from episodic palpitations a

month before, for which she had been hospitalized and diagnosed with paroxysmal supraventricular tachycardia (PSVT). She had a background of Hypothyroidism and Type 2 Diabetes Mellitus, for which she had been prescribed 75 micrograms of Levothyroxine a day, and was also on a combination of Metformin 1000 mg, Vildagliptan 50 mg and Glimepiride 2 mg daily for controlling her blood

sugar levels.

She did not take any supplements. She had no family history of cardiovascular disease or sudden cardiac death. The patient denied drinking coffee, as well as using tobacco or illicit drugs.

Previously, her PSVT had not responded to carotid sinus massage and Valsalva maneuvers. There was also a record of failed cardioversion with Adenosine. At the time, the patient was started on an intravenous infusion drip of Amiodarone, which had subsequently resulted in a conversion to sinus rhythm. She had then been referred to a Cardiologist, and pending further evaluation, had temporarily been started on 40 mg of oral Verapamil twice a day, along with 2.5 mg of Bisoprolol once daily, which she was regular with.

During the patient's current visit to our ED, her initial vital signs were: heart rate (HR) 140 beats/minute and regularly irregular; blood pressure (BP) 110/70 mm Hg; respiratory rate (RR) 22 breaths/minute; axillary temperature 98.6 F. Oxygen saturation was 97% on room air. The random blood sugar was 206 mg/dl. On physical examination, there was no pallor; no anterior neck swelling. There was no carotid bruit. Her extremities were well perfused, with normal capillary refill. There was no evidence of edema. The patient's lungs were clear, and heart sounds were normal with no detection of a murmur. The abdomen was soft and nontender; there was no evidence of organomegaly.

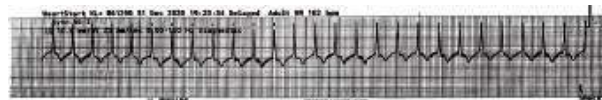
### Investigations

A 12-lead electrocardiogram (Figure 1) showed supraventricular ectopy occurring in triplets and quintuplets.



**Fig. 1:** Supraventricular complexes showing retrograde negative P-waves in the inferior leads, and positive P-wave in lead V1. The P-waves are marked with a blue arrow.

Subsequently, a single-lead tracing (Figure 2) captured a sustained regular narrow-complex tachycardia at 162 beats/minute with retrograde negative P-waves and a long RP interval.



**Fig. 2:** The RP interval is longer than the PR interval and more than half the duration of the RR interval.

Transthoracic echocardiogram demonstrated mild mitral regurgitation and mild mitral stenosis, normal sized left ventricle (LV) with good LV systolic function, a dilated left atrium, and mild pulmonary hypertension.

Her initial blood investigations were normal.

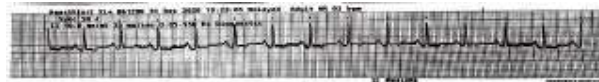
### Differential diagnosis

- Atrioventricular nodal re-entrant tachycardia
- Atrial tachycardia
- Junctional reciprocating tachycardia

### Treatment

The patient was administered Inj. Adenosine 18 mg (in divided doses of 6 mg + 12 mg) through a proximal peripheral intravenous access, at which gradual slowing with reacceleration was noted. She was then given an infusion of 300 mg Amiodarone over an hour.

Within the following hour, the patient got progressively agitated, short of breath, and began complaining of abdominal discomfort. Her vital signs were: HR 165 beats/minute and regular; BP 100/60 mm Hg; RR 25 breaths/minute. Her oxygen saturation was 90% on room air. Physical examination of the patient's lungs revealed fine inspiratory rales bilaterally. She was started on nasal oxygen and given Inj. Furosemide 20 mg IV. As her agitation increased, and with persistence of SVT, the decision for synchronized electrical cardioversion was made. The patient was placed on non-invasive ventilation (NIV) and administered procedural sedation after obtaining written informed consent. Synchronous DC energy with 50 Joules was then delivered with successful conversion to a sinus rhythm (Figure 3).



**Fig. 3:** Normal sinus rhythm following synchronized electrical cardioversion, with a rate of 93 beats/minute.

### Outcome

Post-cardioversion, the patient systematically stabilized. During the next hour in the ED, she was taken off NIV and maintained on nasal oxygen. Her vital signs were: HR 75 beats/minute and regular; BP 120/80 mm Hg; RR 18 breaths/minute; oxygen

saturation 98% on 2 liters of oxygen via nasal cannula. It was decided to keep her in negative fluid balance and on a low-dose diuretic, as the X-ray Chest (Figure 4) showed pulmonary edema.

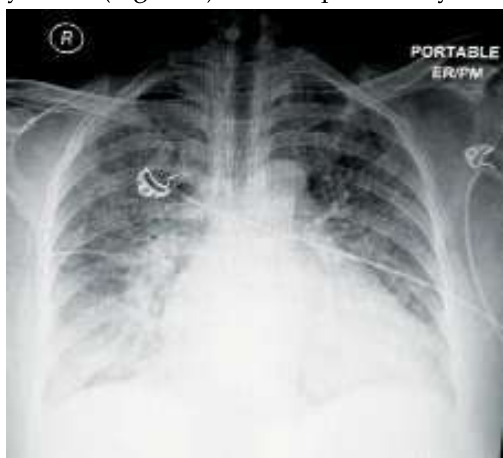

Fig. 4: X-ray of the chest taken shortly before electrical cardioversion.

### Follow-up

In the Intensive Care Unit (ICU), serial cardiac biomarkers stayed within the normal range. Her serum potassium, magnesium and ionized calcium were also monitored, which were normal. The only significant laboratory parameters were elevated TSH 9.38 microIU/ml (0.27 – 4.2) and nt pro BNP 1602 pg/ml (0 – 125).

Trans-esophageal echocardiography revealed rheumatic heart disease, mild mitral stenosis (peak / mean gradient = 10 / 6 mm Hg respectively) and mild mitral regurgitation, normal left ventricle with good systolic function. The left atrium was mildly dilated, with a large thrombus (36 x 13 mm) seen in the left atrial appendage (Figure 5).

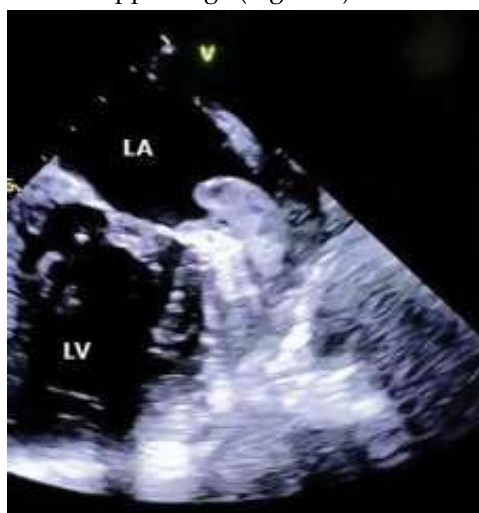

Fig. 5: TEE showing a mid-esophageal two-chamber view; a thrombus can be seen in the left atrial appendage.

The patient was started on T. Rivaroxaban 20 mg once a day and continued on T. Verapamil 40 mg thrice daily. She was discharged on Day 3 (Figure 6), with a planned one-month follow-up with her Cardiologist and a three-month follow-up with a Cardiac Electrophysiologist for catheter ablation therapy.

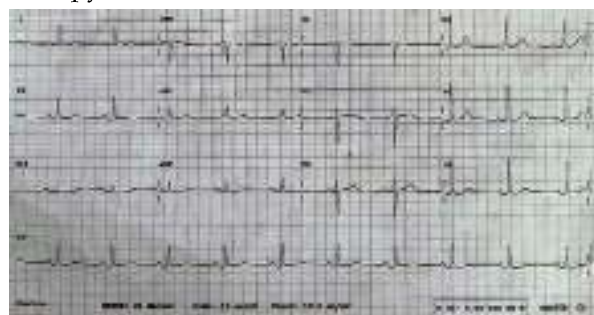

Fig. 6: The patient's ECG on Day 3.

### Discussion

Supraventricular tachycardia (SVT) is an entity commonly seen in clinical practice and often encountered in the Emergency Department. The incidence of SVT is approximately 35 cases per 100,000 patients with a prevalence of 2.25 cases per 1,000 in the general population.<sup>3</sup> Hence, it is our belief that the Emergency Physician will always have an opportunity to interpret, determine and treat previously undiagnosed supraventricular arrhythmias in an acute setting.

Long RP tachycardia is a rare presentation of SVT. The incidence and electrocardiographic characteristics of long RP tachycardia have not been fully elucidated<sup>1</sup>, and to our knowledge, there are no case reports depicting this type of uncommon SVT or its resilience to drug therapy in the Emergency Department.

A tachycardia is defined as long RP if the interval from the R-wave to the next P-wave is longer than the interval from that same P-wave to the next R-wave ( $RP/PR > 1$ ) during the tachycardia (Figure 7)<sup>1</sup>.

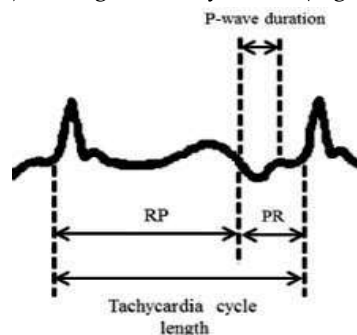
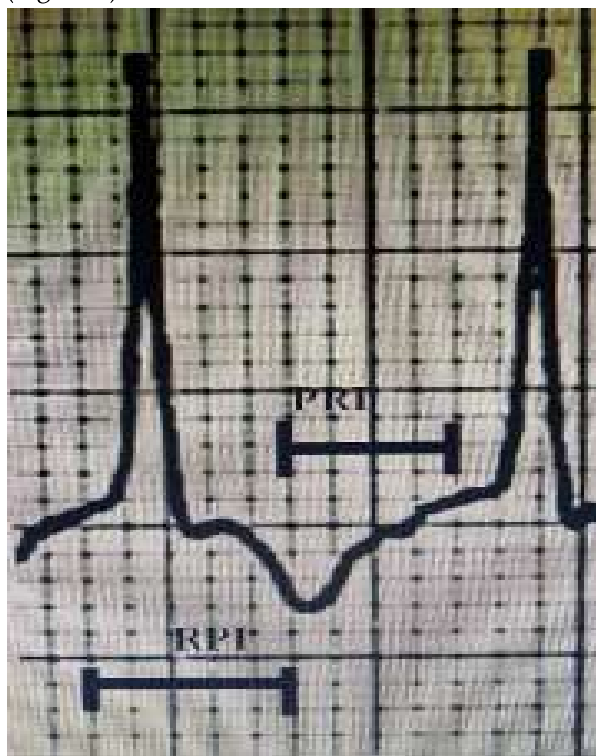


Fig. 7: Measurement of the RP interval, PR interval, and P-wave duration in 12-lead ECG.

In our report, the patient's ECG during tachycardia showed an RP interval of 200 ms, PR interval of 160 ms, and P-wave duration of 80 ms (Figure 8).



**Fig. 8:** Tachycardia cycle measurements showing RPI of 200 ms and PRI of 160 ms with RP/PR of 1.25.

The differential diagnosis for long RP supraventricular tachycardia (SVT) includes atypical or uncommon atrioventricular nodal reentrant tachycardia (AVNRT), atrial tachycardia (AT) and permanent junctional reciprocating tachycardia (PJRT), with diagnostic electrophysiologic studies remaining the mainstay in definitively differentiating between the subtypes<sup>1</sup>.

In our report, the patient had been compliant with Verapamil and Bisoprolol (Class IIa B and Class IIa C recommendations respectively), with apparent failure to control her incessant arrhythmia. In the Emergency Department, the arrhythmia was resistant to vagal and Valsalva maneuvers, as well as first-line medication, Adenosine (Class I B). In retrospect, the effect of gradual slowing with Adenosine followed by reacceleration, could suggest the origin of arrhythmia in the atria (AT) rather than the atrioventricular region (AVNRT). Even though Amiodarone is no longer recommended for stable regular narrow QRS tachycardia, recent guidelines

have made it conceivable in drug-resistant uncommon supraventricular tachycardia or focal atrial tachycardia (Class IIb C). For drug-therapy failure and hemodynamic instability, synchronized DC cardioversion is recommended with Class I B<sup>4</sup>.

### Learning points

- Long RP tachycardia is an uncommon presentation of SVT to the Emergency Department, and hence we believe it should be of academic and clinical interest to the Emergency Physician.
- When dealing with regular narrow QRS tachycardia, characteristic ECG findings, response to Adenosine and persistence or recurrence are helpful in making the diagnosis.
- We suggest early judicious synchronized DC cardioversion in symptomatic patients with incessant SVT with a background of drug-resistant tachyarrhythmia, even if hemodynamically stable.

### References

1. Atsuhiko Y, Hitoshi H, Koji H, Tomofumi N, Koji S, Yasuaki T, Tetsuo S, Mihoko K, Mitsuaki I, Kenzo H. Differentiation of atrial tachycardia from other long RP tachycardias by electrocardiographic characteristics. *Journal of Arrhythmia*. 2014 Oct; 30 (5): 376-381.
2. Basri A, Ayhan K, Hasan Kutsi K, Ersin I, Cengizhan A. Patients with drug-refractory atrioventricular nodal reentrant tachycardia: clinical features, electrophysiological characteristics, and predictors of medication failure. *J Cardiol*. 2014 Oct; 64 (4): 302-307.
3. Daniel S, Owen O. Current trends in supraventricular tachycardia management. *Ochsner J*. 2014 Winter; 14 (4): 586-595.
4. Josep B, Demosthenes K, Elena A, Fernando A, Jeroen B, Carina Blomström-Lundqvist, Hugh C, Domenico C, Spyridon D, Gerhard-Paul D, Juan J Gomez-Doblas, Bulent G, Andrew G, Siew Yen Ho, Juan-Carlos K, Karl-Heinz K, Pier David L, Frederic S, Georgia Sarquella-Brugada, Piotr S, Antonio Z, ESC Scientific Document Group. 2019 ESC Guidelines for the management of patients with supraventricular tachycardia. *European Heart Journal*. 2020 Feb; 41 (5): 655-720.

