

Efficacy of Ultrasound Guided Bilateral Erector Spinae Block in Attenuating Pneumoperitoneal Stretch Response in Patients Undergoing Laparoscopic Abdominal Surg

Saraswathi N.¹, Namratha Chandra², Sumaiya Sabreen³, Mohsina Yasmeen⁴,
Ashwini Lonimath⁵

How to cite this article:

Saraswathi N., Namratha Chandra, Sumaiya Sabreen, *et al.*/Efficacy of Ultrasound Guided Bilateral Erector Spinae Block in Attenuating Pneumoperitoneal Stretch Response in Patients Undergoing Laparoscopic Abdominal Surg/Indian J Anesth Analg. 2023;10(3) 99-104.

Abstract

Background: Increase in heart rate and blood pressure in response to pneumoperitoneum produced during laparoscopic abdominal surgeries is a challenging situation to anesthesiologists. Without adequate control of sympathetic response there is a chance of increase in morbidity of the patient during perioperative period. Aim of the study is to evaluate the efficacy of bilateral erector spinae plane block in attenuating pneumoperitoneal stretch response in patients undergoing laparoscopic abdominal surgeries under general anesthesia.

Methodology: A randomised control trial was conducted among 70 patients, who underwent laparoscopic abdominal surgeries. Under general anesthesia, 35 patients received ESP block with 20 ml of 0.25 levobupivacaine bilaterally (Group B) and 35 patients without block (Group R). This study compared requirement of opioids and response of hemodynamic parameters (Heart Rate, Mean Arterial Pressure) during pneumoperitoneal stretch. Statistical tests were applied.

Results: The intra-operative fentanyl requirement in Group B was 100.85+ and in Group R 119.375 + P value <0.001, statistically significant. The intra-operative heart rate at the time of port insertion, at 5 min, 10 min of pneumoperitoneum and at the end of surgery in Group B (91.97 ±12.09, 90.82±10.7, 92.08±10.9 and 90.857±12.5) were significant when compared to Group R (R 99.9±10.5, 94.48±13.08, 96.68±14.14 and 95.35±14.14 and same is proven statistically. (p < 0.05).

Conclusion: Ultrasound guided bilateral Erector spinae block with Levobupivacaine results in intra-operative hemodynamic stability during port insertion and pneumoperitoneum.

Keywords: Erector spinae; Laparoscopic Surgeries; Lneumoperitoneal.

Author's Affiliation:^{1,3,4}Assistant Professor,²Postgraduate,
⁵Senior Resident, Department of Anesthesiology, Bangalore Medical College and Research Institute, Bangalore 560004, Karnataka, India.

Corresponding Author: Saraswathi N., Assistant Professor, Department of Anesthesiology, Bangalore Medical College and Research Institute, Bangalore 560004, Karnataka, India.

E-mail: dr.saraswathi.pmssy@gmail.com

Received on: 03.05.2023

Accepted on: 15.06.2023

INTRODUCTION

Laparoscopic surgeries induce lower tissue damage than laparotomy, but still spark stress response affecting hemodynamic stability. Challenges to anesthesiologists is to lower the hemodynamic parameters in response to pneumoperitoneum during laparoscopic surgeries and also to attenuate the opioid consumption



perioperatively and to assist opioid affiliated side effects.¹ Hence regional anesthesia was often combined with general anesthesia as an alternative analgesia technique with many benefits; reduces intra-operative stress response, opioid consumption and as a means of providing post-operative analgesia² Analgesia provided by epidural and other peripheral nerve techniques like transverse abdominis block using local anesthetic agents was superior compared to the systemic opioids, use of these ways reduces morbidity and mortality.³ Epidural anesthesia, a central neuraxial block was avoided compared to peripheral nerve block, to avoid unnecessary handling of central neuraxial and side effects of urinary retention.

Among peripheral nerve techniques, Erector spinae block represents a more straight forward, safer alternative to epidural anesthesia as the injection was into a tissue plane that was distant from the pleura, major blood vessels and discrete nerves.⁴ Ultrasound guided erector spinae plane (ESP) block was originally reported in 2016 was used for thoracic neuropathic pain.⁵ It provides thoracic analgesia when performed at the T5 level and relieves visceral abdominal pain when performed at the level of T8. Erector spinae block to be effective in providing extensive somatic and visceral abdominal analgesia in Laparoscopic abdominal surgeries by injection at lower thoracic level of T7-T9 level.⁶ Local anesthetic injected into the fascial plane deep to the erector spinae muscle spreads in a craniocaudal fashion over several levels, also penetrates anteriorly through the inter transverse connective tissue and enters the thoracic para-vertebral space where it can potentially block not only the ventral and dorsal rami of spinal nerves but also the rami communicants that transmit sympathetic fibres.

Emerging research shows that erector spinae block can be employed as a simple and safe alternative analgesic technique for acute perioperative pain instead of using multimodal regimens.⁷ This study aims to evaluate the efficacy of bilateral erector spinae plane block in attenuating pneumoperitoneal stretch response in patients undergoing laparoscopic abdominal surgeries under general anesthesia. The primary objective of this study was, total fentanyl consumption during pneumoperitoneum and secondary objective was hemodynamic stability during pneumoperitoneum.

METHODOLOGY

After taking institutional ethics clearance

and CTRI number-CTRI/2021/12/038716, This Randomized control study design, which was a prospective, double blinded trial conducted on 70 cases undergoing laparoscopic abdominal surgeries for five months from November 2021 to March 2022. Patients were randomly divided into two groups based on random numbers generated by a computer program (www.randomizer.org).

- **Group B:** 35 patients, ESP block 0.25% levobupivacaine 20ml bilaterally.
- **Group R:** 35 patients receiving no blocks.

Allocation concealment was ensured by sequentially numbered opaque sealed envelope method. Patients who gave written informed consent, belonging to ASA I and II and patients undergoing laparoscopic abdominal surgery under general anesthesia were included in the study. Patients having hypersensitivity to the drugs used, having severe systemic illness similar as uncontrolled diabetes, hypertension and with bleeding diathesis were excluded from the study. Procedure was explained to the patients and an informed written consent was taken. Alprazolam 0.5 mg was given night before surgery. On the day of surgery patients were shifted to the operating room. Pulse oximeter, non-invasive blood pressure, ECG monitors were connected and baseline parameters recorded. An intravenous line with 18G IV cannula was obtained and IV infusion of 500 ml ringer lactate started. General anesthesia was induced with intravenous midazolam 1 mg and fentanyl 2mcg/kg as premedication, preoxygenation for 3 minutes duration with 100% oxygen at 6L/min, inj. Propofol 2mg/kg as inducing agent. Inj. Vecuronium 0.1 mg/kg was employed as muscle relaxant. Trachea was intubated with appropriately sized cuffed endotracheal tube. Anaesthesia was maintained using isoflurane dial concentration to attain 1 MAC, in a mixture of oxygen and air. Patient was made to lie in the left side position under general anesthesia. Under strict asepsis, the T8 spinous process was located by counting down from the C7 spinous process. Ultrasound curvilinear array with low frequency 2-6 MHz, (Sonosite M Turbo) was placed transversely at this position to spot the tip of the T8 transverse process. The tip of the transverse process was centred on the ultrasound screen and also the probe was rotated into a longitudinal orientation to provide a parasagittal view, during which the following layers was visible superficial to the acoustic shadows of the transverse processes skin and subcutaneous tissue; trapezius; and erector spinae muscle. The rhomboid major muscle has its lower border at

the T5 - 6 vertebral position and its absence are going to be used as fresh evidence that the T8 transverse process is being viewed. An echogenic 23-G spinal needle (Quincke's) was inserted in-lane to the ultrasound ray in an exceedingly cranial-to-caudal direction until contact was made with the T8 transverse process. Correct position of the needle tip in the fascial plane deep to erector spinae muscle was verified by injecting 0.5-1 ml saline and seeing the fluid lifting the erector spinae muscle off the transverse process while not distending the muscle. An aggregate of 20 ml levobupivacaine 0.25% was fitted into the ESP. The procedure was repeated on the contralateral side.^{4,5} Intra-operatively, intra-abdominal pressure was maintained ≤ 15 mm of Hg. Surgeons were asked to wait for 15 minutes to put incision (positioning of patient and aseptic precaution were followed meanwhile in that time); repeat fentanyl 0.5 to 1mcg/kg was given during carbon dioxide insufflation as rescue analgesia, if there was any increase in heart rate and mean arterial pressure by more than 20% from baseline. IV paracetamol 1gm was given to all patients in both the groups after intubation and repeated every 8th hourly. Isoflurane was stopped at the end of surgery case, was reversed with injection neostigmine 0.05 mg/kg and injection glycopyrrolate 0.01 mg/kg. Case was extubated after surgery shifted to recovery. Total amount of fentanyl consumed during intraoperatively and the response of hemodynamic parameters (Heart Rate, Mean Arterial Pressure) during time of port insertion and at 5 min, 10 min, after pneumoperitoneum stretch, was recorded. Any side effects because of drugs or techniques like hematoma or vascular perforation was recorded and treated consequently. This was a double blinded study, among the two, one anesthetist involved in induction of general anesthesia along with drug loading and ESP block, another anesthetist was involved in recording the hemodynamic parameters after the block once the surgery started.

Table 2: ASA grade between the two groups

		<i>p</i> = 0.832						
		Group						
		Group B			Group R		Total	
		Count	%	Count	%	Count	%	
ASA	1	25	55.56%	24	53.33%	49	54.44%	
Status	2	20	44.44%	21	46.67%	41	45.56%	

The hemodynamic parameters, heart rate (HR) and mean arterial pressure (MAP) was compared between the two groups. The p value on comparing baseline heart rate between the two groups was

Sample size was calculated in line with the study conducted by Tulgar S *et al*¹; grounded on the parameter fentanyl demand in group B (patients receiving ESPB) n=4 and group C (patients not receiving ESPB) n=11. The sample size calculation is $n = 2(Z_{\alpha} + Z_{1-\beta})^2 \sigma^2 / d^2$, Where Z_{α} = standard table value for 95% CI=1.96, $Z_{1-\beta}$ =standard table value for 80% power=0.84, Σ =standard deviation=3.72, D=effect size=2.5, n=35 in each group.

The statistical software namely SPSS 23 was used for the analysis of the data. Categorical data represented as frequencies. Discrete and continuous data represented as mean (SD) and used to analyse the pneumoperitoneal stretch response, fentanyl analgesia requirements intra-operatively. P value <0.05 is considered as statistical significant. Paired t test has been used to find the significance of hemodynamic parameters and opioid requirement between two groups (Inter group analysis).

RESULTS

The demographic profile about age, gender, ASA grade, and duration of surgery in the two groups were comparable. Totally 70 patients were enrolled for the study, out of which 44 were females and 28 were males with a mean age of 43.85 days duration of surgery was comparable in both the groups. There was no significant difference in status between two groups. (Table 1)

Table 1: Demographic parameters between the two groups.

Data	Group B	Group R	
Age in years	43.85±10.04	41.77±10.10	p value >0.0
Gender distribution	Male (16) Female (19)	Male (17) Female (18)	p value >0.05

The intra-operative fentanyl requirement during pneumoperitoneum in Group B was higher (100.85+2.34 mcg) compared to Group R (119.375+3.41 mcg) with P-value <0.001, statistically significant. (Table 2)

0.128 and baseline values between two groups was comparable. The mean heart rate as beat per minute after port insertion, 5 min, 10 min of pneumoperitoneum and at the end of surgery was

stable in group B compared to group R, where the heart rate was increased on pneumoperitoneum, and the difference was statistically significant during port insertion (0.012*), at 5 min (0.043*), 10 min (0.037*) of pneumoperitoneum. (Fig. 1) The p value on comparing the baseline mean arterial pressure between the two groups was 0.342 and baseline values between two groups were comparable. The mean arterial pressure after port insertion, 5 min, 10 min of pneumoperitoneum and at the end of

surgery was stable in group B compared to group R, and the mean arterial pressure difference was statistically significant during port insertion, at 5 min, 10 min of pneumoperitoneum and at the end of surgery. (p < 0.05) Throughout the intra-operative pneumoperitoneum, hemodynamic parameters were stable in Group B. There was no hypotension due to sympathetic blockade or complications associated with the local anesthetic used in both the groups.

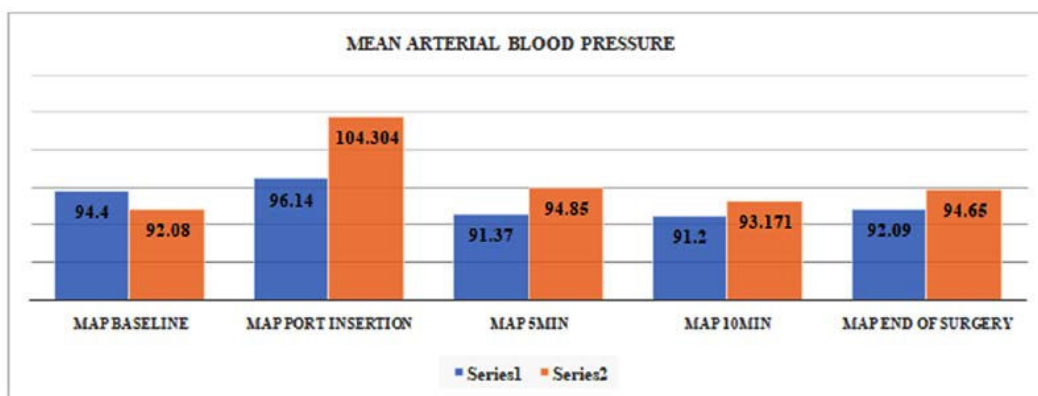


Fig. 1: Mean values of map in Group B (Series 1) and R (Series 2)
MAP = Mean arterial pressure

DISCUSSION

Erector Spinae Plane (ESP) block was first described having been used for the successful treatment of thoracic neuropathic pain. Later studies demonstrated that ESP block was an effective analgesic method in bariatric surgery, pneumothorax surgery, and major abdominal

surgery when performed at the thoracic vertebral levels. The local anesthesia administered during ESP block spreads in the paravertebral space, which causes effective analgesia for somatic and visceral pain. When performed bilaterally, ESP block has similar effect as epidural analgesia.^{1,2} It prevents the nociceptive signals from surgical area reaching central nervous system thus inhibits endocrine and metabolic response to surgery.³

Table 3: Mean value and p value of fentanyl consumption in both the groups.

	Group B	Group R	P Value
Fentanyl Requirement	100.85	119.375	<0.001

Table 4: Heart rate comparison between two groups at different time intervals

Heart Rate at Intervals	Group B		Group R		P Value
	Mean	SD	Mean	SD	
Baseline	91.08 bpm	14.16 bpm	90.31 bpm	16.02 bpm	0.128
Port Insertion	91.97 bpm	12.09 bpm	99.9 bpm	10.5 bpm	0.012*
5 Min Pneumoperitoneum	90.82 bpm	10.7 bpm	94.48 bpm	13.08 bpm	0.043*
10 Min Pneumoperitoneum	92.08 bpm	10.9 bpm	96.68 bpm	14.14 bpm	0.037*
End of Surgery	90.85 bpm	12.5 bpm	95.35 bpm	14.14 bpm	0.043*

Laparoscopic surgery induces less tissue damage than laparotomy, the procedure will still activate

stress response thus affecting hemodynamic stability. Pneumoperitoneum caused by CO₂

insufflation will increase intra-abdominal pressure (IAP) and affect hemodynamic secondary to mechanical and neurohormonal responses. Positive changes of IAP will increase MAP and systemic vascular resistance (SVR) and may decrease cardiac output (CO). Elevations in plasma norepinephrine, epinephrine, cortisol, vasopressin, renin and aldosterone levels were also demonstrated during pneumoperitoneum.³ Pain during laparoscopic abdominal surgeries arises significantly from portsite incisions in the anterior sensory supply of the anterior abdominal wall, segmentally provided by nerves running in the fascial plane between transversus abdominis muscle and internal oblique muscle.⁴ Other component of pain in upper abdominal laparoscopic procedures was the stretching of the peritoneum and peritoneal irritation caused by carbonic anhydrase response to the insufflations of parietal peritoneum with carbon dioxide.⁵

ESP block was a promising regional anesthesia technique as it had the ability to block both supra-umbilical and infra-umbilical dermatomes with a single level injection. Intra-operative fentanyl requirement during laparoscopic pneumoperitoneum would be high and it might result in side effects like vomiting, sedation, urinary retention, ileus, constipation, and respiratory depression. Patients with opioid allergy or history of serious nausea vomiting, or itching after opioid use, those who are not able to use NSAIDs, and those having low pain thresholds would appear to be good candidates for ESP block.^{7,8}

In our study, ESP block the fentanyl was used to maintain intraoperative hemodynamic stability in turn to control pain, the consumption of fentanyl in group B was 100.85±2.34 mcg and in group R was 119.375±3.41 mcg with p value <0.001, statistically significant. Similar results were found in Chin K J *et al*⁴ and Peker *et al*⁶ study, where there was reduced opioid consumption who received bilateral erector spinae block for laparoscopic surgeries. This was in concordance with the study conducted by Mohamed Ahmed Hamed *et al*,⁹ total fentanyl consumption in the first 24 hrs was significantly higher in the control group compared to the ESP block group (485±20.39 mcg vs 445±67.49 mcg, respectively; P=0.003. Heart rate the hemodynamic parameters in group B were stable. There was no variation from baseline compared to group R where there was statistical increase in heart rate, mean arterial pressure from the baseline showing stress response to pain. There was statistically significant difference during pneumoperitoneum in heart rate and mean arterial pressure (MAP) between two

groups on comparing using p value, p<0.05. Similar findings were found in Besthadi Sukmono R³ study, where the intraoperative mean arterial pressure in quadratus lumborum group had better stability in comparison with epidural groups, which may be caused by reduction of surgical stress responses in quadratus lumborum group.

ESP Block showed a relatively steadier intraoperative hemodynamic parameter and minimal fentanyl requirement during pneumoperitoneum, so we can use ESP block for most of the laparoscopic surgery instead of multimodal approach.¹⁰ Limitation of our study was, we used only single shot bolus of drugs for only laparoscopic surgeries. Future scope is to evaluate the effects of unilateral catheter fixation for abdominal surgeries.

CONCLUSION

Bilateral erector spinae block was effective in attenuating pneumoperitoneal stretch response in patients undergoing laparoscopic abdominal surgeries resulting in significant decrease in opioids.

REFERENCES

1. Tulgar S *et al.* Evaluation of ultrasound guided erector spinae plane block for postoperative analgesia in laparoscopic cholecystectomy: A randomized, controlled clinical trial. *J Clin Anesth* 2018; 49:101.
2. Tulgar S, Selvi O, Kapakli M. Erector Spinae Plane Block for Different Laparoscopic Abdominal Surgeries: Case Series. *Case Reports in Anesthesiology* 2018; 2018:1-3.
3. Besthadi Sukmono R, Rahendra, Sari A, Aditiansih D, Rosita Tantri A. Comparison of intraoperative hemodynamic stability between quadratus lumborum and epidural block in patients who underwent laparoscopic nephrectomy. *Journal of Physics* 2019; 1246:012064.
4. Chin KJ, Adhikary S, Sarwani N, Forero M. The analgesic efficacy of pre-operative bilateral erector spinae plane (ESP) blocks in patients having ventral hernia repair. *Anaesth* 2017; 72:452-460.
5. Forero M, Adhikary SD, Lopez H, Tsui C, Chin KJ. The erector spinae plane block: a novel analgesic technique in thoracic neuropathic pain. *Reg Anesth Pain Med* 2016; 41:621-7.
6. Peker K, Akçaboy ZN, Aydın G, Gençay I, Şahin AT, Koçak YF *et al.* The Effect of Erector Spinae Plane Block on Laparoscopic Cholecystectomy Anesthesia: Analysis of Opioid Consumption, Sevoflurane

- Consumption, and Cost. *J Laparoendosc Adv Surg Tech A.* 2020; 30:725-729.
7. Chin KJ, Malhas L, Perlas A. The Erector Spinae Plane Block Provides Visceral Abdominal Analgesia in Bariatric Surgery. *Regional Anesthesia and Pain Medicine.* 2017;42(3):372-376.
 8. Ibrahim M. Erector spinae plane block in laparoscopic cholecystectomy, is there a difference? A randomized controlled trial. *Anesth: Essays and Res* 2020; 14:119.
 9. Hamed MA, Goda AS, Basiony MM, Fargaly OS, Abdelhady MA. Erector spinae plane block for postoperative analgesia in patients undergoing total abdominal hysterectomy: a randomized controlled study original study. *J Pain Res* 2019; 12:1393-1398.
 10. Tulgar S, Ahiskalioglu A, De Cassai A, Gurkan Y. Efficacy of bilateral erector spinae plane block in the management of pain: *J Pain Res* 2019; 12:2597-2613.
 11. Ueshima H, Otake H. Clinical experiences of ultrasound-guided erector spinae plane block for thoracic vertebra surgery. *J Clin Anaesth* 2017; 38:137.
 12. Hurley RW, Murphy JD, Wu CL. Acute postoperative pain. In: Ronald D. Miller editor. *Miller's anesthesia* 8th ed. Philadelphia Elsevier saunders 2015:2974.
 13. Dolin SJ, Cashman JN, Bland JM: Effectiveness of acute postoperative pain management: Evidence from published data, *Br J Anaesth* 2002;89:409-423.
 14. Horlocker TT, Kopp SL, Wedel DJ. Peripheral nerve blocks. In: Ronald D. Miller editor. *Miller's anesthesia* 8th ed. Philadelphia Elsevier saunders 2015; 1721:303-320.

