

Dengue Fever Complicating Term Pregnancy Leading to Postpartum Hemorrhage

Pintu Kumar¹, Priya Govil², Kishalay Datta³

How to cite this article:

Pintu Kumar, Priya Govil, Kishalay Datta/Dengue Fever Complicating Term Pregnancy Leading to Postpartum Hemorrhage/
Indian J Emerg Med 2023;9(3):91 – 93.

Abstract

Dengue infection during the peripartum period is always a challenging situation for the obstetrician as well as other clinical departments involved in the management for these patients. The risk increases to a greater extent if the infection occurs during the third trimester as it possesses the risk of serious bleeding during parturition. In this case report, we will see the incidence and management of dengue fever in a peripartum female.

Keywords: Dengue Fever; Postpartum Hemorrhage.

INTRODUCTION

Dengue fever is a well known viral fever in the South East Asia region of the world. Dengue infection accounts for only 2.5% of all pregnancy in parturient women living in endemic regions¹ but sometimes poses high risk maternal complications, especially during parturition. Life threatening conditions may be predisposed if the mother undergoes any bleeding condition like cesarean section. There have been very few literature articles and case reports where it has been discussed about the management of postpartum

hemorrhage with dengue infection, thus, there is no well written guideline for the management of dengue complicating obstetrical complications.

CASE

A 32 year old multiparous female was brought to the Emergency department of our hospital with complaints of severe abdominal pain and spotting and leaking *per vaginam*. As per the history by the patient's husband, her antepartum period was uneventful with thorough antenatal checkup and scans. She developed a fever for the last 5 days, became very lethargic with nausea and vomiting, very lethargic with a feeling of increased body weight. They both thought it to be normal changes during pregnancy. During the initial obstetrics evaluation, the patient was having strong uterine contractions, *per vaginal* examination revealed 2 cm dilated cervix with fetal head presentation. It was noted that the patient had small petechial rashes over the distal aspect of the forearm. Routine blood tests were done and were found to have low platelet counts (32000 approx), raised hematocrit (38.8%).

Author's Affiliation: ¹Emergency Medicine Resident, ²Senior Consultant, ³Director and HOD, Department of Emergency Medicine, Max super speciality Hospital, Shalimar Bagh- 110088, New Delhi, India.

Corresponding Author: Pintu Kumar, Emergency Medicine Resident, Department of Emergency Medicine, Max super speciality Hospital, Shalimar Bagh- 110088, New Delhi, India.

E-mail: drpintugupta85@gmail.com

Received on: 14-03-2023

Accepted on: 20-04-2023

Patient dengue serology was done (NS1 antigen, IgG and IgM serology) which came to be positive.

Patient was admitted to the Intensive care unit and the pregnancy was hastened up with active management of the third stage of labour. Immediate platelet transfusion was started and a total 4 bags of platelet was transfused before delivery of the child. The third stage of labour was shortened by active management of the third stage of labour to prevent blood loss.

After the delivery of the placenta, the patient suddenly started having severe uterine bleeding with uterine atony. Uterine massage was initiated along with uterotonic medications. Platelet transfusion was started immediately during the third stage of labour. After 30-40 minutes of uterine massage and uterotonic medications, PPH was controlled and the uterus got contracted. Baby was shifted to the NICU for further care, the mother kept in the ICU for 48 hours observation. Both mother and child recovered well and got discharged. Postnatal follow up was uneventful, child growth was progressing well and mother also recovered well.

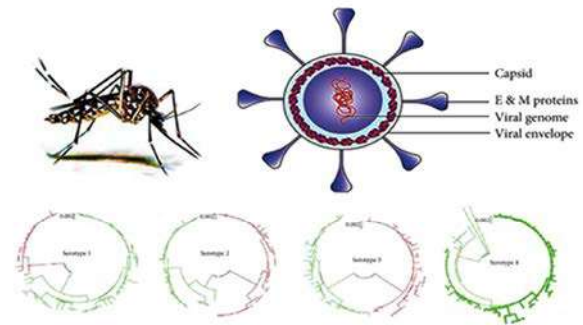
DISCUSSION

Dengue viral fever can occur during any trimester. The early diagnosis and treatment of dengue viral fever related thrombocytopenia plays a crucial role during pregnancy, especially in the third trimester. As per records^{2,3}, dengue viral fever during pregnancy has favorable outcomes for the mothers and neonates, and thus pregnancy can be continued with close monitoring of the mother's blood parameters and fetal scans. As per records available on online data hub, the rate of preterm birth, still birth and low birth weight were found to be 20%, 5.0%, and 5.0%, respectively.^{2,4} Postpartum hemorrhage ranges from 10%-19% if dengue fever occurs during the peripartum period.⁵

The dengue virus, a member of the genus *Flavivirus* of the family *Flaviviridae*, is an arthropod-borne virus that has four different serotypes (DEN-1, DEN-2, DEN-3, and DEN-4).⁶ Transmission among human beings occurs by the bite of female mosquito *Aedes aegypti*.⁷

Vaginal delivery can be allowed with or without prophylactic platelet transfusion even though platelet count falls below 50000/mm³.⁸ Cesarean section increases the risk of bleeding during parturition, hence not tried. Post-partum hemorrhage arising after the vaginal delivery

was complicated by thrombocytopenia secondary to dengue viral fever (with warning signs). Optimal timing for platelet transfusion remains controversial till date, but it should not be too far away from the time of delivery.⁹ In our case, the



platelet transfusion was begun 30 minutes before the active management of the third stage of labour, repeated after 6 hours, 12 hours and 24 hours after the delivery and control of PPH. Regardless of prophylactic platelet transfusion, according to reports available, clinical bleeding mothers with dengue infection may still occur¹⁰, partially due to the intricate effect of dengue infection on the hemostatic system.¹¹ Thus, over emphasizing the platelet correction is not recommended, instead correction of maternal conditions leading to PPH must be corrected promptly. Use of uterotonic medications (Inj. Oxytocin, Inj. Methylergometrine) and need for skill expertise for the management of PPH plays a vital role along with platelet correction.

The diagnosis of dengue fever requires skills and clinician expertise as the presentation of dengue fever overlaps with HELLP syndrome (low platelet, elevated liver enzyme, deranged hematocrit). Also, physiological changes in pregnancy makes it difficult for proper diagnosis and management of dengue fever complication pregnancy. If correctly diagnosed, good resuscitation and proper post natal care is given, the outcomes are favorable as in this case and other reported cases. Close monitoring is required with postnatal checkup of both mother and neonate as there have been reported cases of vertical transmission of dengue viral fever.

CONCLUSION

Dengue fever complicating the peripartum stage is generally due to the effect of dengue viral proteins over the hemostatic system of the body. Prompt diagnosis of dengue fever, management of platelet and other blood parameters along with prevention of maternal risk factors which can lead to maternal

bleeding tendencies during the peripartum state are the treatment goals. Maternal hygiene, environmental hygiene, mosquito control remains the mainstay in prevention and transmission of dengue fever.

REFERENCES

1. Tan PC, Rajasingam G, Devi S, *et al.*: Dengue infection in pregnancy: prevalence, vertical transmission, and pregnancy outcome. *Obstet Gynecol.* 2008; 111(5): 1111-7. 10.1097/AOG.0b013e31816a49fc.
2. Chansamouth V, Thammasack S, Phetsouvanh R, Keoluangkot V, Moore CE, Blacksell SD, *et al.* The Aetiologies and Impact of Fever in Pregnant Inpatients in Vientiane, Laos. *PLoS Negl Trop Dis* 2016; 10: e0004577.
3. Paixao ES, Teixeira MG, Costa Mda C, Rodrigues LC. Dengue during pregnancy and adverse fetal outcomes: a systematic review and meta-analysis. *Lancet Infect Dis* 2016; 16: 857-65.
4. Pouliot SH, Xiong X, Harville E, Paz-Soldan V, Tomashek KM, Breart G, *et al.* Maternal dengue and pregnancy outcomes: a systematic review. *Obstet Gynecol Surv* 2010; 65: 107-18.
5. Sharma S, Jain S, Rajaram S. Spectrum of Maternofetal Outcomes during Dengue Infection in Pregnancy: An Insight. *Infect Dis Obstet Gynecol* 2016; 2016: 5046091.
6. Halstead SB. Pathogenesis of dengue: Challenges to molecular biology. *Science.* 1988; 239: 476-81.
7. Arshad I, Malik FA, Hussain A, Shah SA. Dengue fever: Clinico-pathologic correlations and their association with poor outcome. *Professional Med J.* 2011; 18:57- 63.
8. American College of Obstetricians and Gynecologists: ACOG Practice Bulletin: Clinical Management Guidelines for Obstetrician-Gynecologists Number 76, October 2006: postpartum hemorrhage. *Obstet Gynecol.* 2006; 108 (4): 1039-47.
9. WHO/TDR: Hand book for clinical management of dengue. Geneva, Switzerland: *World Health Organization*; 2012;124.
10. Lye DC, Lee VJ, Sun Y, *et al.*: Lack of efficacy of prophylactic platelet transfusion for severe thrombocytopenia in adults with acute uncomplicated dengue infection. *Clin Infect Dis.* 2009; 48(9): 1262-5. 10.1086/597773.
11. DeAzeredo EL, Monteiro RQ, de-Oliveira Pinto LM: Thrombocytopenia in Dengue: Interrelationship between Virus and the Imbalance between Coagulation and Fibrinolysis and Inflammatory Mediators. *Mediators Inflamm.* 2015; 2015: 313842. 10.1155/2015/313842.