

Comparison of Peng Block versus Ficb in Hip Surgeries, A Randomised Control Study

Malathi Anil Kumar¹, Madhumala HR², Ashna Shetty³

Author's Affiliation: ¹Assistant Professor, Department of Anesthesiology, Sanjay Gandhi Institute of Trauma and Orthopedics, Bangalore, Karnataka 560011 ²Assistant Professor, ³Post Graduate Student, Department of Anesthesiology, Bangalore Medical College and Research Institute, Bangalore, Karnataka 560034, India.

Abstract

Background: Hip surgeries are among the common surgeries performed in orthopaedics especially in geriatric age group. A recent anatomical study on hip innervation led to the identification of relevant landmarks to target the hip articular branches of femoral nerve and accessory obturator nerve making Pericapsular nerve group (PENG) block popular. However there are other commonly performed blocks for hip surgeries including Fascia Iliaca block, 3 in 1 block, Femoral nerve block. This study is aimed at comparing the efficacy of Pericapsular nerve group (PENG) block and Fascia Iliaca Block (FICB) in terms of post operative analgesia.

Aims and objectives: To compare the efficacy of post- operative analgesia in Pericapsular nerve group (PENG) block and Fascia Iliaca block in hip surgeries.

Material and Methods: Total 90 patients scheduled for hip surgeries under combined spinal epidural anesthesia were selected for the study. In 30 patients ,ultrasound guided PENG block was given, in other 30 ultrasound guided Suprainguinal Fascia Iliaca block was given and other 30 patients were used as control group in the post operative period and duration of analgesia was assessed by numeric rating scale (NRS) and visual analogue scores (VAS)

Results: In our study of 90 patients posted for hip surgeries, PENG block showed better results in terms of reduction in pain scores, time of first analgesia requirement and quantity of rescue analgesics used in the post operative period.

Conclusion: The newer PENG block is better than Fascia Iliaca block in hip surgeries in delaying post opioid consumption, its associated side effects and delirium especially in geriatric patients.

Keywords: Hip surgeries; Pericapsular nerve group block; Fascia Iliaca Compartment block; Post-operative analgesia.

How to cite this article:

Malathi Anil Kumar, Madhumala HR, Ashna Shetty/Comparison of Peng Block versus Ficb in Hip Surgeries, A Randomised Control Study/Indian J Anesth Analg. 2021; 8(6):607-613.

Corresponding Author: Madhumala HR, Assistant Professor, Department of Anesthesiology, Bangalore Medical College and Research Institute, Bangalore, Karnataka 560034, India.

Email: drmadhumala@gmail.com

Introduction

Hip fracture is a devastating injury in most cases especially in geriatric patients.¹ Surgical reduction and fixation are the definitive treatment in most patients.² Total hip arthroplasty is also one of the most common major orthopaedic procedures to improve patient's functional status and quality of life. However, the immediate postoperative period can be associated with severe pain that delays mobilisation and increases hospital stay and risk of thromboembolic events.^{3,4} Effective perioperative analgesia minimizes the need for opioids and related adverse effects such as delirium.^{5,6} Hence regional analgesia techniques are commonly used as they provide opioid-sparing effect and are relatively safe.⁷

The anterior hip capsule receives innervation from the femoral nerve, obturator nerve and the accessory obturator nerve.

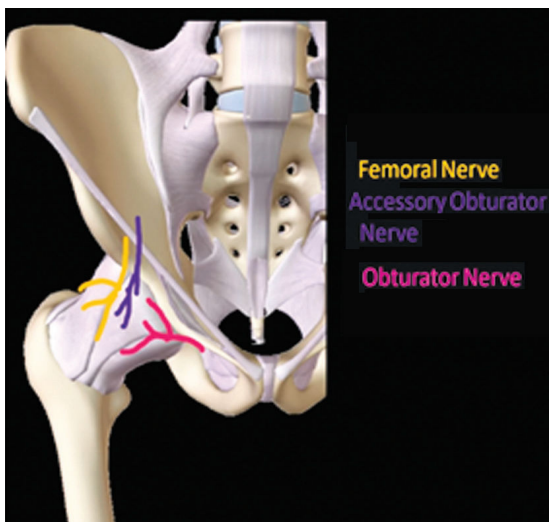


Fig. 1: Anterior Hip Capsule Innervation.

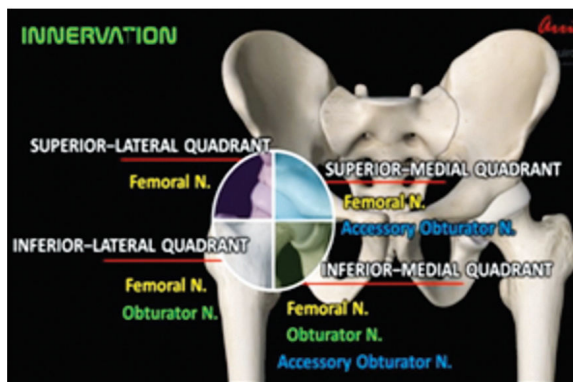


Fig. 2: Quadrant Wise Nerve Supply Innervation.

An anatomic study by Short et al. demonstrated that high and low branches of femoral nerve (above and below inguinal ligament) provided majority of innervations to all quadrants more to lateral

and superomedial hip capsule. High and low branches of obturator nerve (proximal and distal to obturator canal) provided focussed innervation to inferomedial hip capsule. Accessory obturator nerve (found in 56%) was found to innervate the medial aspect of capsule.⁸ It is understood that anterior hip capsule receives major sensory innervation whereas posterior and inferior hip capsule have no sensory innervation.⁹

These studies also evaluated the relationship with these nerves and other bony or soft tissue landmarks visible by ultrasound guidance. The relationship of articular branches from these 3 nerves to inferomedial acetabulum (radiographic teardrop) and the space between anterior inferior iliac spine and iliopubic eminence may suggest potential target.⁸ Previous studies have found histologically that the anterior capsule has predominantly nociceptive fibers, while the posterior capsule is largely made up of mechanoreceptors.¹⁰

A fascia iliaca compartment block under ultrasound guidance can provide superior analgesia with minimal side effects with high success rates. It blocks both femoral and lateral femoral cutaneous nerve.¹¹ However Pericapsular nerve group (PENG) block described in 2018 aimed to target the articular branches of hip which are femoral nerve and accessory obturator nerve providing more complete analgesia to hip with motor sparing effects.¹²⁻¹⁴ In addition, this injection may prevent or decrease the postoperative spasm of iliacus muscle which is common cause of post operative pain after hip arthroplasties.¹⁵

Aim and Objectives

The primary objective of the study was to compare

- The reduction in pain scores following blockade

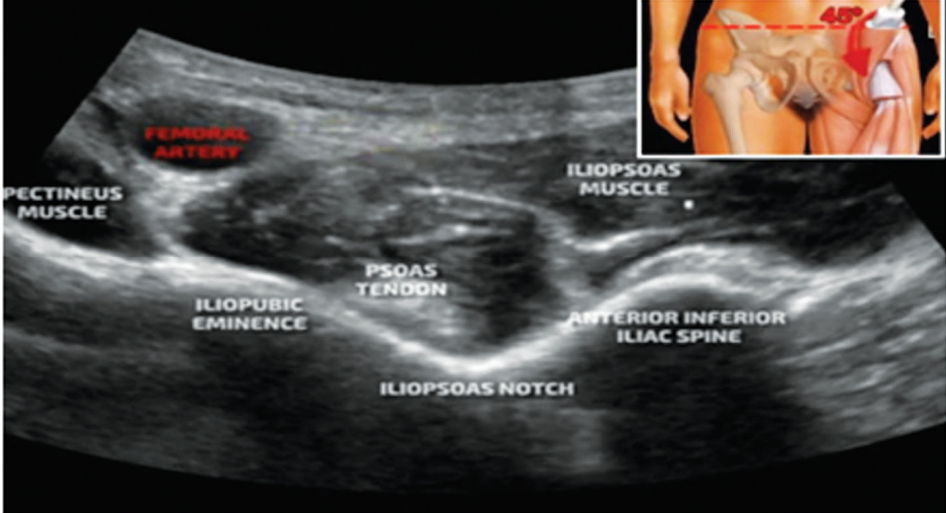
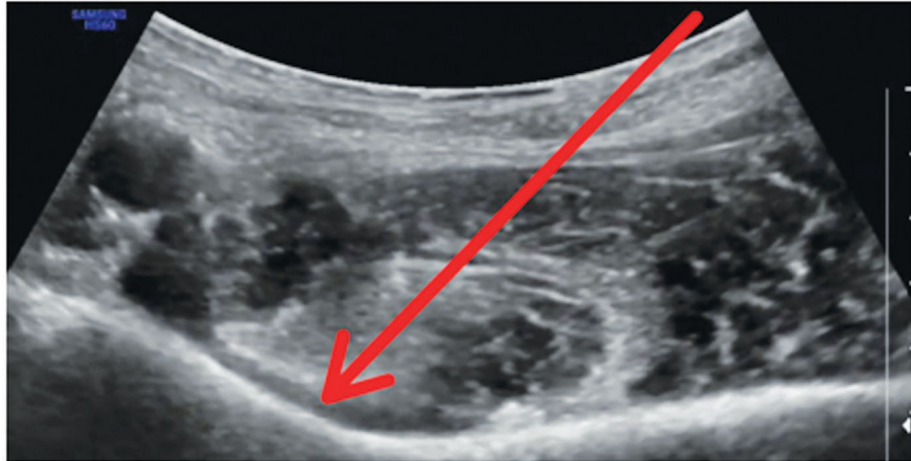
The secondary objectives were to compare


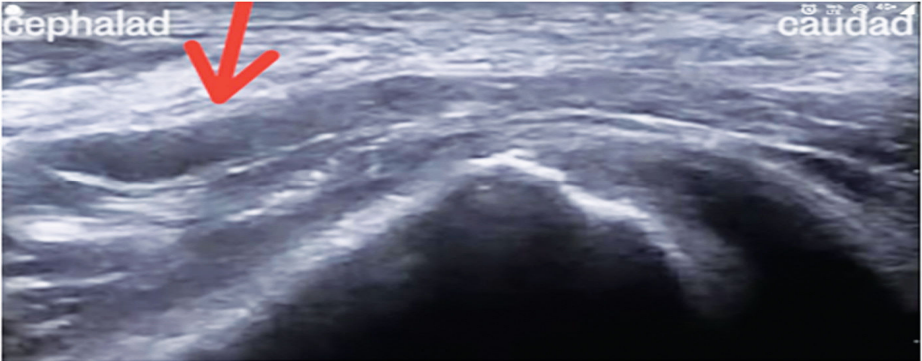
- Time period at which first analgesic was requested
- 24 hour analgesic requirement
- Side effects

Criteria

Inclusion Criteria

Patients scheduled for hip surgeries e.g. hip hemiarthroplasty, total hip arthroplasty, proximal femur fracture fixation under combined spinal epidural (CSE) anesthesia.

Type of block	Procedure
<p>Pericapsular Nerve Group Block (PENG Block)</p>	<p>It blocks the articular branches of anterior capsule that is femoral nerve, obturator nerve and accessory obturator nerve to the anterior capsule. Procedure: A low frequency curvilinear ultrasound probe (2-5 MHz) was placed over anterior superior iliac spine (ASIS) in the transverse plane and then turned 45 degree clockwise placing the probe over the line joining anterior superior iliac spine and pubic tubercle (PT) keeping lateral margin at anterior superior iliac spine (ASIS) to get a sonoanatomic view for PENG block.</p>  <p>Fig. 3: The needle entry point was selected on the skin in such a manner that perpendicular needle entry will guide needle near target point (IPE).</p> <p>The needle entry point was anaesthetised with 2 ml 1% lidocaine and block needle was inserted “in plane” to reach the bony rim near Ileo-pubic eminence (IPE) avoiding injury to femoral nerve (visible just lateral to femoral artery). On bony contact, before injecting, the correct needle position was confirmed by drug spread under illo-psoas muscle. In a successful block, the local anesthetic should lift the psoas tendon off of the ilium and should track both medially and laterally.^{7,16}</p>  <p>Fig. 4: Needle entry.</p> <p>20 ml of 0.25% Ropivacaine was injected slowly with repeated aspiration to avoid intravascular injection.</p> <p>Number of patients-30</p>

<p>Suprainguinal Fascia Iliaca Block (FICB)</p>	<p>It blocks femoral nerve and lateral cutaneous femoral nerve. Procedure :In supine position, a high frequency linear probe was placed in the inguinal crease. Scan starting laterally from the femoral artery and nerve in inguinal crease to identify the sartorius muscle, tracing the muscle until it's origin to anterior superior iliac spine.</p>  <p>Fig. 5: The shadow of the bony of iliac crest & iliopsoas muscle was seen, the end point of the injection was deep to the fascia iliaca and above the iliopsoas muscle in the lateral part of the iliopsoas muscle.</p> <p>After negative aspiration, 20 ml of 0.25% Ropivacaine was injected under the fascial plane incrementally, aspirating every 5 ml, same time avoiding the deep circumflex iliac vessels. Observe for unzipping of the fascia iliaca from the underlying muscle planes to confirm spread between the hyperechoic fascia iliaca and the more heterogeneous iliopsoas muscle beneath it in the picture given above.</p> <p>Number of patients - 30</p>  <p>Fig. 6:</p>
---	---

Exclusion Criteria

- Coagulopathy
- Infection at the injection site
- Allergy to local anesthetics
- Severe cardiopulmonary disease (\geq ASA IV)
- Diabetic or other neuropathies
- Patients receiving opioids for chronic analgesic therapy
- Contraindication to spinal anesthesia
- Inability to comprehend visual analog scale (VAS).

Materials and Methods

After obtaining ethical committee clearance and informed consent, 90 ASA 1 and 2 patients aged between 18 and 80 years posted for fixation of Traumatic hip fractures and Hip Arthroplasties were selected and were scheduled for surgery under combined spinal epidural anaesthesia 30 patients of them were given Pericapsular nerve group block (PENG) and 30 others Fascia Iliaca Block (Suprainguinal) and 30 others were considered control groups. Standard hospital protocol regarding medical optimisation, intravenous line placement, premedication, and antibiotic prophylaxis was followed. In operation room,

monitors for non-invasive blood pressure (NIBP), 3 leads continuous electrocardiogram (ECG), and pulse oximeter (SPO2) were attached. Taking all aseptic precautions, patient was given combined spinal epidural anaesthesia and proceeded with the surgery followed by post-operative Pericapsular Nerve Group (PENG) block or Suprainguinal Fascia Iliaca block.

Thirty more cases were taken as control group with no block given to any of these cases. Pain scores were assessed using Visual analogue score (VAS) and Numeric rating scale (NRS) for the next 24 hours period. Reduction in the pain score, duration of sensory blockade, total duration of analgesia, request to time of first analgesic requested was recorded. Rescue analgesia used were IV paracetamol, IM diclofenac, epidural bupivacaine 0.125% and any side effects were noted.

Results

Reduction in Pain Scores Following Blockade

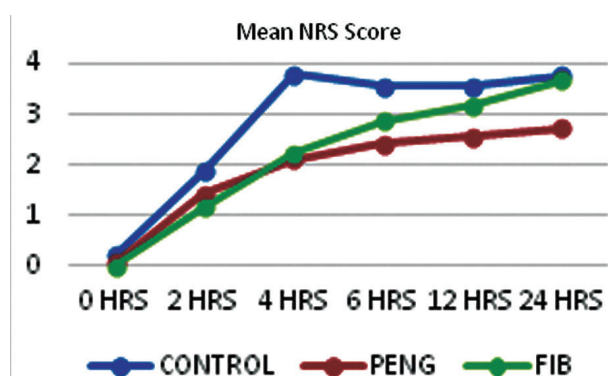


Fig. 9: The graph depicts the significant reduction in numeric rating pain score in the group of PENG block compared to FIB group of block. Comparing the reduction in pain scores using NRS among the three groups was found to be significant at all hours in the 24 hours period ($p < 0.05$).

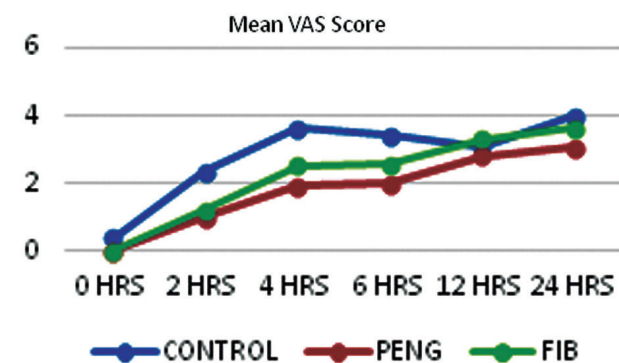


Fig. 10: The graph depicts the significant reduction in Visual Analogue Score in the group of PENG block compared to FIB group of block. Comparing the reduction in pain scores using NRS among the three groups was found to be significant at all hours in the 24 hours period ($p < 0.05$) except at 12 hours.

Time Period at which First Analgesic was Requested: The mean difference in the time of first analgesia required in PENG group and FIB group in comparison with that of control group was found to be -13.800 hours and -4.900 hours respectively and was found to be statistically significant ($p < 0.05$) based on the Post Hoc test for Anova. *amount of Additional Analgesia Required:* The mean difference for amount of additional analgesia required in PENG group and FIB group on comparison with that of control group was found to be 1.300 and 1.033 respectively and was found to be statistically significant ($p < 0.05$) based on the Post Hoc test for ANOVA thus showing a greater requirement of analgesia in the Fascia Iliaca block compared to Pericapsular Nerve Group block.

Discussion

Post operative pain management after hip surgeries has always been a challenging goal to achieve. Multiple regional techniques have been used in the past but there is no 'best proven intervention' for post operative analgesia.¹⁸

The innervation of hip joint is complex and is by both lumbar (L1-L4) and sacral (L4-S4) plexus receiving its sensory innervations from Femoral, Obturator, Accessory obturator and Sciatic nerves with contribution from Nerve to Quadratus Femoris and Superior Gluteal Nerve.¹⁹

PENG block is a novel ultrasound guided myofascial plane block where the target area is the pelvic rim (superior pubic ramus) near the ileopubic eminence, deep to fascia of iliopsoas muscle thus blocking the articular branches of femoral nerve, obturator nerve and accessory obturator nerve which cross over the bony rim.^{7,20} However by increasing the volume of local anesthetic, other nerves (Genitofemoral nerve and lateral cutaneous femoral nerve) can be blocked.¹² Other than its perioperative use for hip surgeries, it is used as an 'arrival block', anesthesia for dislocated hip and varicose vein stripping procedure.^{21,22} One of the major advantage is the preservation of quadriceps motor function due to its diffusion zone blocking only the articular branches to the anterior hip capsule and sparing the motor branches of the femoral nerve.¹³

Suprainguinal Fascia Iliaca Block is a compartmental block and is an important armament of hip analgesia gaining rapid popularity.^{9,23} However there is disagreement about the exact neuroanatomy targeted by Fascia Iliaca Block and they may not provide sufficient analgesia in

hip surgeries as articular branches originate at a higher level along the course of nerves.²⁵ Moreover the cephalad local anesthetic spread does not consistently cover the obturator nerve.²⁶

Our study aimed at comparing the two blocks in terms of reduction in pain scores, time at which first analgesic was requested and quantity of additional analgesia used in the 24 hour post operative period. However larger comparative studies are required to establish the efficacy and superiority over one another.

In a similar randomized comparative study by Bhattacharya et al²⁷ PENG group had significantly quicker onset of action compared to Suprainguinal Fascia Iliaca block (average of 13.6 and 22 minutes) respectively. In a similar double blinded randomized control trial by Shankar et al²⁸ the duration of block was comparable between PENG and FICB (8.16 hours versus 7.85 hours). Patient satisfaction about pain relief after the blocks was assessed by Jaden et al²⁹ and showed 97% were highly satisfied.

EOSP scores (ease of spinal positioning) was better in PENG group when compared to Fascia Iliaca Block.

Kim and Tsui³⁰ raised a valid point that periosteal injury and tissue damage vary between fracture fixation and replacement surgeries and suggested a subgroup analysis comparing the pain outcome in future studies. Furthermore in their experience difference in postoperative pain in hip surgeries tend to be more apparent at a later time than Day 0, especially when patient starts mobilising . This is most likely due to micromotion at the fracture site in the different subgroups.

Our results were similar to other studies that have reported better post operative analgesic efficacy in PENG group when compared to Fascia Iliaca Block. No patient reported any local anesthetic toxicity, block related complications like vascular puncture or ureteric injury and quadriceps weakness.

Further randomized control studies need to determine its efficacy as a solo block is also warranted. Also cadaveric and magnetic resonance imaging studies are recommended for better understanding of the anatomic spread of local anesthetic and nerves covered with both blocks.

Conclusion

The PENG block and SIFICB are potential supplements for regional analgesic techniques for post operative analgesia in hip surgeries. They can

be easily performed in supine position without any discomfort of patient positioning. PENG block showed better reduction in pain scores, delayed request for first analgesic and less requirement of additional analgesia in 24 hours period.

References

1. Brauer CA, Coca-Perrailon M, Cutler DM, Rosen AB. Incidence and mortality of hip fractures in the United States. *JAMA*. 2009;302:1573-9.
2. Neuman MD, Fleisher LA, Even-Shoshan O, Mi L, Silber JH. Nonoperative care for hip fracture in the elderly: the influence of race, income, and comorbidities. *Med Care*. 2010;48:314-20.
3. Sloan M, Premkumar A, Sheth NP . Projected Volume of Primary Total Joint Arthroplasty in the U.S., 2014 to 2030. *J BONE Joint Surg Am* 2018; 100:1455.
4. Talec, P., Gaujoux, S. and Samama, C., 2016. Early ambulation and prevention of post-operative thrombo-embolic risk. *Journal of Visceral Surgery*, 153(6), pp.S11-S14.
5. Morrison RS, Magaziner J, Gilbert M, et al. Relationship between pain and opioid analgesics on the development of delirium following hip fracture. *J Gerontol A BiolSci Med Sci*. 2003;58:76-81. 4.
6. Morrison RS, Magaziner J, McLaughlin MA, et al. The impact of postoperative pain on outcomes following hip fracture. *Pain*. 2003;103:303-11.
7. Girón-Arango L, Peng PW, Chin KJ, et al Pericapsular Nerve Group (PENG) Block for Hip Fracture Regional Anesthesia & Pain Medicine 2018;43:859-863.
8. Short AJ, Barnett JJG, Gofeld M, et al Anatomic Study of Innervation of the Anterior Hip Capsule: Implication for Image-Guided InterventionRegional Anesthesia & Pain Medicine 2018;43:186-192.
9. U. Shukla, M. Jahan, S. Naaz, and S. Srivastava, "USG guided femoral nerve block vs fascia iliaca compartment block as post-operative analgesia in hip fracture patients," *International Journal of Research in Medical Sciences*, vol. 6, no. 9, p. 3057, 2018.
10. Bugada D, Bellini V, Lorini L, Mariano ER: Update on selective regional analgesia for hip surgery patients. *Anesthesiology Clin*. 2018, 36:403-415.
11. Godoy Monzon D, Iserson KV, Vazquez JA. Single fascia iliaca compartment block for post-hip fracture pain relief. *J Emerg Med*. 2007 Apr;32(3):257-62.
12. Ahiskalioglu A, Aydin ME, Ahiskalioglu EO, Tuncer K, Celik M. Pericapsular nerve group (PENG) block for surgical anesthesia of medial thigh. *J Clin Anesth*. févr 2020;59:42-3.
13. Kukreja P, Avila A, Northern T, Dangle J, Kolli S, Kalagara H. A Retrospective Case Series of

- Pericapsular Nerve Group (PENG) Block for Primary Versus Revision Total Hip Arthroplasty Analgesia. *Cureus* [Internet]. [cité 1 août 2020];12(5)
14. Ueshima H, Otake H. Clinical experiences of pericapsular nerve group (PENG) block for hip surgery. *J Clin Anesth.* déc 2018;51:60-1.
 15. NYSORA E Learning <https://www.nysora.com/techniques/lower-extremity/ultrasound-guided-femoral-nerve-block/>.
 16. Luftig J, Dreyfuss A, Mantuani D, Nagdev A, et al. A new frontier in pelvic fracture pain control in the ED: Successful use of the pericapsular nerve group (PENG) block. *Am J Emerg Med.* Published online May 2020.
 17. Amato PE, Thames MR. How I do it: suprainguinal fascia iliaca block. *ASRA News* 2020;45.
 18. Højer Karlsen AP, Geisler A, Petersen PL, et al. Postoperative pain treatment after total arthroplasty: a systematic review. *Pain.* 2015;156(1):8-30.
 19. Tomlinson, J., Ondruschka, B., Prietzel, T. et al. A systematic review and meta-analysis of the hip capsule innervation and its clinical implications. *Sci Rep* 11, 5299 (2021). N. H. Amin, J. A. West, T. Farmer, and H. G. Basmajian, "Nerve blocks in the geriatric patient with hip fracture: a review of the current literature and relevant neuroanatomy," *Geriatric Orthopaedic Surgery & Rehabilitation*, vol. 8, no. 4, pp. 268-275, 2017.
 20. Ashwin AB, Shankar K, Rangalakshmi S. Comparative evaluation of peng block [pericapsular nerve group block] v/s fascia iliaca block [fib] for positioning and post-operative analgesia prior to spinal anaesthesia for hip surgeries: Prospective randomized controlled trial. *Indian J Anaesth* 2020;64(Suppl 1):S35-40.
 21. Ueshima H, Otake H. Pericapsular nerve group (PENG) block is effective for dislocation of the hip joint. *J Clin Anesth* 2019;52:83 21.
 22. Aydin ME, Borulu F, Ates I, Kara S, Ahiskalioglu A. A novel indication of Pericapsular nerve group (PENG) block: Surgical anesthesia for vein ligation and stripping. *J Cardiothorac Vasc Anesth* 2020;34:843-5.
 23. Dulaney-Cripe E, Hadaway S, Bauman R, Trame C, Smith C, Sillaman B, et al. A continuous infusion fascia iliaca compartment block in hip fracture patients: A pilot study *J Clin Med Res.* 2012;4:45-8.
 24. J. Tran, A. Agur, and P. Peng, "Is pericapsular nerve group (PENG) block a true pericapsular block?" *Regional Anesthesia & Pain Medicine*, vol. 44, no. 2, p. 257, 2019.
 25. Amin NH, West JA, Farmer T, Basmajian HG. Nerve Blocks in the Geriatric Patient With Hip Fracture: A Review of the Current Literature and Relevant Neuroanatomy. *Geriatr Orthop Surg Rehabil.* 2017 Dec;8(4):268-275.
 26. Acharya U, Lamsal R. Pericapsular nerve group block: An excellent option for analgesia for positional pain in hip fractures *Case Rep Anesthesiol.* 2020;2020:18030136.
 27. Bhattacharya A, Bhatti T, Haldar M. Pericapsular nerve group block -Is it better than the rest for pain relief in fracture neck of femur? *Reg Anesth Pain Med.* 2019;44:A116.
 28. Shankar K, Srinivasan R, Ashwini AB, Nandini U, Chandra M, Kadlimatti DV. Comparative study of ultrasound guided PENG [Pericapsular Nerve Group] block and FIB [Fascia Iliaca Block] for positioning and postoperative analgesia prior to spinal anesthesia for hip surgeries: Prospective randomized comparative clinical study *Indian J Anesth Analg.* 2020;7:798-803.
 29. Jadon A, Sinha N, Chakraborty S, Singh B, Agrawal A. Pericapsular nerve group (PENG) block: A feasibility study of landmark based technique *Indian J Anaesth.* 2020;64:710-3.
 30. Kim RK, Tsui BC, Kim RK. Towards precision regional anesthesia: is the PENG block appropriate for all hip fracture surgeries? *Reg Anesth Pain Med* 2021.

