

## Anaesthetic Management of Surgical Resection of A Giant Mediastinal Mass - A Case Report

Snigdha Paddalwar<sup>1</sup>, Vaibhav Dhabe<sup>2</sup>, Hiren Shah<sup>3</sup>

**Author's Affiliation:** <sup>1</sup>Consultant Pediatric, Cardiac Anaesthesia, Glenfield Hospital, University Hospitals of Leicester, Leicester, UK, <sup>2</sup>Consultant Pediatric, <sup>3</sup>Junior Consultant Pediatric, SRCC Children's Hospital, Mahalakshmi, Mumbai, Maharashtra 400034, India.

### Abstract

Giant mediastinal mass tumors have been associated with perioperative respiratory and circulatory life-threatening complications during induction of general anaesthesia and initiation of positive pressure ventilation leading to sudden cardiac arrest known as MMS, 'Mediastinal mass syndrome' (4, 5,6). A detailed meticulous preanaesthetic evaluation and a well thought out anaesthetic plan can avoid life-threatening events during management of these patients. We report a successful anaesthetic management of a 12 yrs old pediatric patient with a left sided giant mediastinal germ cell tumor, posted for complete surgical resection. We followed the guiding principles for anaesthetic management of such cases, maintaining propped up position, avoiding muscle relaxants, maintaining spontaneous breathing, keeping cardiac team and perfusion team ready to cannulate and institute CPB in case of sudden cardiorespiratory collapse, adapting to low volume ventilation and titrated and step wise induction of anaesthesia.

**Keywords:** Mediastinal Mass Syndrome; Germ Cell Tumour; CPB.

### Introduction

Giant mediastinal tumors like germ cell tumors are known to cause significant airway and great vessel compression.<sup>1</sup> It has been associated with perioperative respiratory and circulatory life-threatening complications during induction of general anaesthesia and initiation of positive pressure ventilation leading to sudden cardiac arrest known as MMS, 'Mediastinal mass syndrome'.<sup>4,6</sup> A detailed meticulous preanaesthetic evaluation and a well thought out anaesthetic plan can avoid

life-threatening events during management of these patients. Germ cell tumors (GCTs) are rare tumors thought to be derived from totipotent primitive germ cells that either migrate along the urogenital ridge during early embryogenesis or are distributed physiologically. GCTs show a wide diversity of benign or malignant characteristics.<sup>2</sup> Among extra gonadal GCTs, mediastinal germ cell tumors (MGCTs) in children are extremely rare and often form giant masses invading the surrounding vital organs and tissues.<sup>3</sup> We are reporting

### How to cite this article:

Snigdha Paddalwar, Vaibhav Dhabe, Hiren Shah/Anaesthetic Management of Surgical Resection of A Giant Mediastinal Mass - A Case Report/Indian J Anesth Analg. 2021;8(2):273-277.

**Corresponding Author: Snigdha Paddalwar**, Consultant Pediatric, Cardiac Anaesthesia, Glenfield Hospital, University Hospitals of Leicester, Leicester, UK.

**E-mail:** [spdrsnigdha96@gmail.com](mailto:spdrsnigdha96@gmail.com)

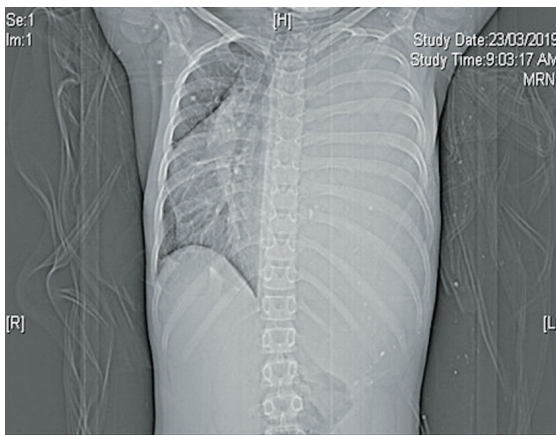


This work is licensed under a Creative Commons Attribution-NonCommercial-ShareAlike 4.0.

anaesthetic management of a pediatric case with a giant mediastinal germ cell tumor for surgical resection without CPB support. This is the largest tumor ever reported for anaesthetic management, as per our search through the literature.

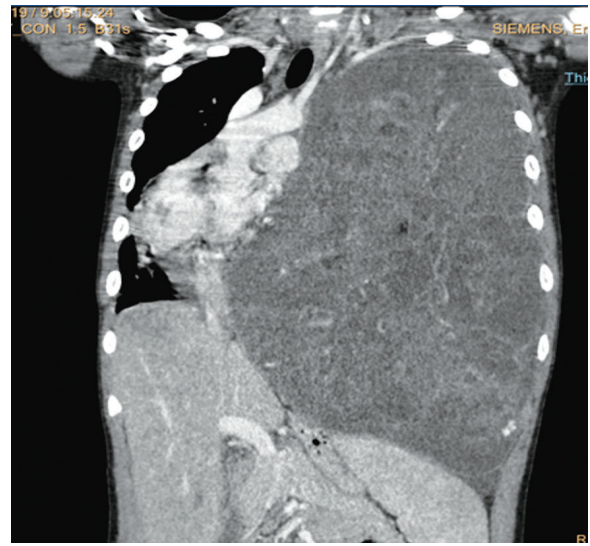### Case Report

A 12 yrs. old male patient, weighing 40kgs was referred to Anaesthetic OPD for Preanaesthetic evaluation with a diagnosis of a giant anterior mediastinal mass, a germ cell tumor. He had received 3 cycles of Bleomycin, Cisplatin and Etoposide and presented with complaints of breathlessness, which had increased rapidly over a period of 6 months from NYHA 2 to 4 at present, with MET of 4. He also complained of left sided chest pain, shoulder pain, fullness on left side of the chest, loss of appetite, weight and change of voice. He specifically complained of not being able to lie supine or in right lateral position, so he adapted left lateral and propped up position to sleep. He also had history of GCTS for which he was being treated with anticonvulsants after ruling out neurological causes with neuroimaging.

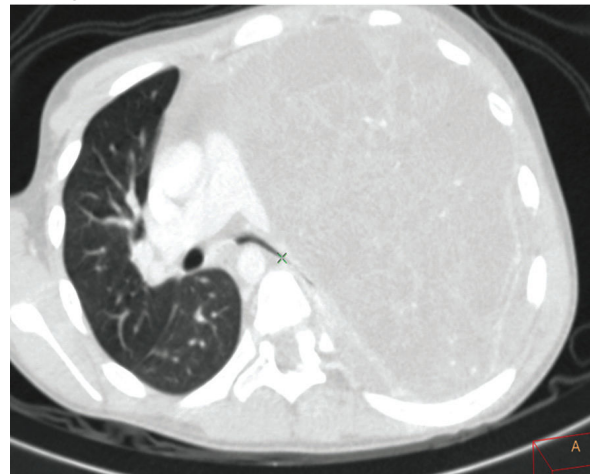

**Fig. 1** X-Ray Chest: Massive tumor seen in left thorax, mediastinal shift to right with heart completely displaced into right hemithorax, tracheal deviation to the right, compression of left bronchus, left diaphragm displaced into abdomen, great vessels stretched.

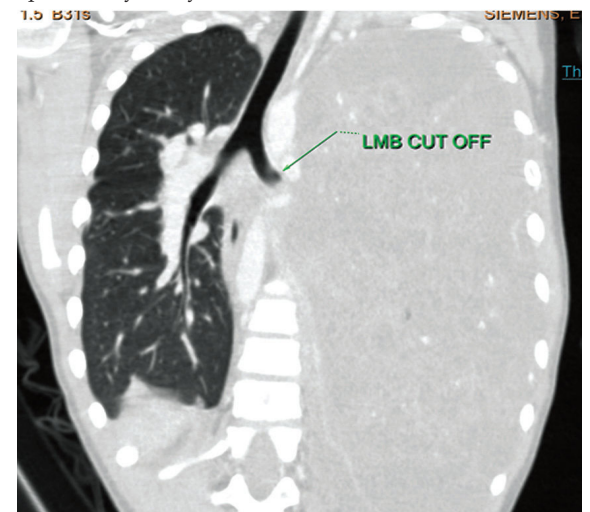
His lab investigations were within normal limit. X-Ray chest (Fig. 1) showed left thorax complete white out, left lung completely collapsed, significant mediastinal shift to right, tracheal deviation to right left hemidiaphragm displaced into the abdomen. CT chest scan (Fig. 2) confirmed findings of chest X-Ray with additional findings of complete obliteration of left bronchus (Fig. 3,4) and left pulmonary artery completely plastered to the mass; other great vessels were compressed and encased in the mass; heart was shifted into right hemithorax. (Fig. 2,3,5) Trachea was shifted into right mediastinum. (Fig. 1,2) The tumor size was 16\*19\*27cms.



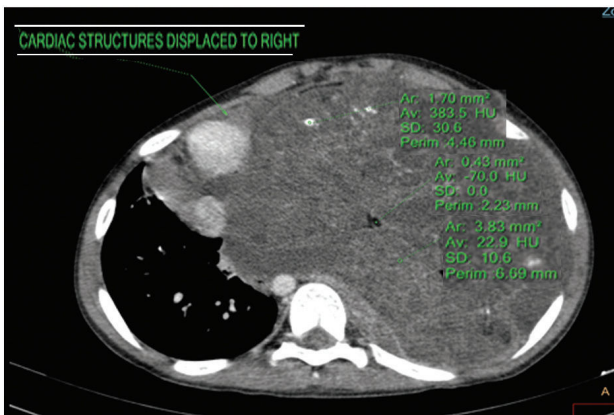
**Fig. 2:** CT scan images massive tumor occupying the left hemithorax and whole mediastinum, Heart displaced into right hemithorax, tracheal displacement and compression, left diaphragm flattened and displaced into abdomen.



**Fig. 3:** Large heterogeneous mass 16cm\*19cm\*27cm, left lung completely collapsed, mild pleural effusion. Left bronchus and left pulmonary artery cut off.



**Fig. 4:** Large mass with left bronchus cut off in sliced CT image, mild compression of right bronchus.



**Fig. 5:** cross sectional view of giant germ cell tumor, cardiac shadow seen in right hemithorax compressed between mass and the anterior chest wall.

After discussing with oncosurgical and cardiac surgical team we finalized a plan for Anaesthesia induction, airway intervention and back up strategy.

On the day of surgery after connecting him to all the essential monitors. We placed him in propped up position. We secured a 18G thoracic epidural catheter in T5-6 space followed by radial arterial line, central line in Rt IJV and 2 16 G IV cannulas in lower limb while patient was awake, under local anaesthetic. We had our CPB machine, perfusion team and cardiac team standby for induction of anesthesia, as these patients are very high risk for cardiac arrest during anaesthetic induction. We had a rigid bronchoscope as a stand by to stent the trachea if it all it collapses after induction. Our plan was to institute CPB for E-CPR with femoral access so we kept femoral triangle prepared and marked with USG. Before induction we gave him a volume bolus, followed by 1 micgm/kg of fentanyl and 2mg of midazolam as premedication and induced with SEVO and a small-titrated dose of Propofol maintaining spontaneous breathing.

We intubated him without a muscle relaxant in propped up and left lateral position, with conventional laryngoscope and SLT. Ventilation was achieved with 6ml/kg of tidal volume with peak airway pressure of 25 with a good ETCO<sub>2</sub> trace. He had hypotension, which responded to volume loading and few boluses of phenylephrine otherwise he tolerated induction well. As soon as surgeons were ready for sternotomy we positioned him supine. His ventilatory parameters improved slightly after sternotomy and we gave our first dose of muscle relaxant. We started with epidural infusion of Ropivacaine 0.1% with Baxter pump.

Excision of entire tumor was done in total, without CPB in 10 hours and he had significant blood loss

approx. 950 ml, which was replaced with blood and blood products. Surgeon had to convert his incision to clamshell to gain access to difficult aspects of the tumor. Problems encountered Intraoperatively apart from excessive blood loss and long operative time was difficulty in maintaining hemodynamics and ventilation every time tumor was manipulated and mobilized. Any manipulation in tumor caused significant fall in blood pressure and extreme increase in airway pressures with inability to ventilate due to complete obstruction of airway and compression of heart into right thorax.

Each time we warned the surgeon to lift the tumor off the great vessels, heart and airway. Intraoperatively his hemodynamics were very labile as surgeon had to manipulate the tumor for fine detailed dissection to free all the important vascular and airway structures from the tumor and hence needed constant intervention. With meticulous coordination between surgeon and the anesthesiologist we could counter all the challenges and avoided CPB completely.

Towards the end we started a small dose of noradrenaline to keep up his MAP above 60. As tumor was removed from the thorax his heart moved into the mediastinum spontaneously and LPA looked full and free. His ventilation improved significantly with PInsp pressure of 18, we could deliver a tidal volume of 10mls/kg. His tumor weighed 3.4kgs. He had received 3 units of PRBC, 2 units of FFP, 2 units of platelets 3.5 litres of crystalloid. His maximum lactates were 3.5 and hemoglobin 10.6gm%

Sternotomy was closed and he was then shifted to PICU with stable hemodynamics. His pain control was appropriate and urine output was 1ml/kg/hour. He got extubated after 3 days of ventilation

Patient was brought back to the operating room 2 times for sternal wound infection and thereafter he was extubated and discharged after 20 days of hospital stay.

## Discussion

MMS is defined as acute right ventricular failure secondary to vascular compression after positive pressure ventilation in patients with a mediastinal mass.<sup>4,5</sup> Difficulty with ventilation and cardiac arrest in the course of anaesthesia for diagnostic or therapeutic procedures in patients with mediastinal mass is well described.<sup>3,4</sup> Some centers have reported an incidence in pediatric patients of 7–20% during anaesthesia and 18% in the postoperative period. Nevertheless, insufficient preoperative

preparations and inadequate perioperative management can promptly lead to life-threatening situations.<sup>3</sup> Therefore, careful diagnostic workup and detailed preoperative imaging is essential in all cases to assess the anatomy and exact relationship of the tumor with the surrounding vital mediastinal structures. In our case we did a detailed imaging analysis and studied the status of all great vessels and airway, in relation to the tumor, along with our surgical and the radiology team.

Our patient had all the clinical signs of significant tracheobronchial obstruction, which could have potentially worsened, with induction of general anaesthesia and intermittent positive pressure ventilation (IPPV). Decreased chest wall tone and caudal displacement of the diaphragm leads to loss of the distending transmural pressure gradient. Anaesthesia induction in patients with anterior mediastinal mass will shrink the transverse diameter of the thorax owing to a decrease in the inspiratory muscle tone, cephalic displacement of the abdominal contents secondary to loss of the abdominal muscle tone and relaxation of bronchial smooth muscles, leading to a major airway collapse. In addition, the craniocaudal movement of the diaphragm will be lost, or significantly diminished with the administration of neuromuscular blockers leading to sudden collapse of the airway.<sup>6</sup>

Hence, maintenance of spontaneous ventilation is critical to avoid precipitating complete obstruction in these patients. Awake intubation in propped up position or inhalational induction with maintenance of spontaneous ventilation is recommended depending on the degree of obstruction and the symptoms produced.<sup>7,8</sup> If there is any difficulty in ventilation because of obstruction at the level of the carina or the bronchus, a rigid bronchoscope should be inserted and ventilation maintained by connecting a Sanders injector or jet ventilator to the side port of the bronchoscope. In the presence of severe symptomatic obstruction, stenting could be performed to rescue the patient. As we had prepared in our case by securing all the lines in awake propped up left lateral position, maintaining spontaneous breathing during intubation avoiding muscle relaxants, keeping rigid bronchoscope by our side, secure large bore IV cannulas in lower limb and preparation for CPB

Predictors of perioperative complications concerning respiratory or circulatory collapse in patients with a mediastinal mass are CT findings of  $\geq 50\%$  tracheal compression or  $\geq 130$  cm<sup>3</sup> mass volume, presence of pleural effusion or pericardial effusion, presence of superior vena

cava compression, pulmonary artery compression on one side, atelectasis on the other side, peak expiratory flow rate  $\leq 40\%$  of the predicted value, and an obstructive or mixed pattern of pulmonary function test.<sup>1,6</sup> Our patient could not perform PFT due to severity of symptoms.

Based on all the investigations and clinical examination patient can be categorized as low risk and high risk for MMS. This risk stratification may guide the utilization of perioperative pre-emptive measures and precautions, like the safest form of anesthesia, the optimal positions for induction of anesthesia and surgery, the additional value of intraoperative (rigid) bronchoscopy and TEE, and the potential assistance of extracorporeal circulation (ECC). Furthermore, due to the possible involvement of the superior vena cava (SVC) in large mediastinal masses, large-bore venous access should be secured in the lower extremity (preferably the femoral vein) rather than the upper extremity in all patients, regardless of risk category.

The rescue modality when MMS occurs is ECC, providing an avenue for both oxygenation and circulatory support. Earlier reports have described "stand-by" ECC as a rescue measure<sup>9-11</sup> for intraoperative hemodynamic or respiratory deterioration. However, even with a primed ECC circuit and perfusionist present in the operating room, it will still take 5–20 minutes before emergency cannulation of the femoral vessels is performed and ECC is initiated<sup>12</sup>; an interval likely to result in significant neurological injury. Therefore, several authors have recommended femoral cannulation under local anesthetics and initiation of ECC before induction of anesthesia (6, 48) especially in patients with high risk of MMS and are deemed "uncertain" or "unsafe" according to the classification proposed by Erdös and Tzanova.<sup>(6, 48)</sup> But we were assured of dealing with any such complications by rescue position and then institution of CPB as our cardiac surgeons and perfusion team was in theatres during induction, well prepared with appropriate size cannulas and markings on the femoral vessels sited with USG.

We could successfully do this high-risk case without any complications as we had comprehensive and detailed preop preparation, involvement of multidisciplinary team, anticipation of problems and possible events and a plan to counter that. We could find a rescue position and maintained the same until sternotomy. Meticulous management of intraoperative hemodynamics, ventilation and fluid status, urine output helped us in optimum outcome. Maintaining optimum temperature

through out helped us in achieving hemostasis inspite of extensive surgical bed and high risk for bleeding.

## Conclusion

Anaesthetic induction of patients with giant mediastinal masses can pose a significant challenge to an anaesthesiologist in view of high risk for cardiovascular collapse and respiratory compromise. Literature search has showed few cases with giant germ cell tumors and their anaesthetic management however ours is the largest mass ever reported. Our casereport highlights the strategy for successful management of such cases. Following are the keys to form a strategy to avoid unwarranted life threatening events. Assess the risk and degree of severity through a detailed history and physical examination. Preoperative imaging and echocardiogram to ascertain details of mediastinal mass and nearby compressed structures. Classify risk of developing mediastinal mass syndrome.

Explore the best position for less dyspnea and greater comfort i.e rescue position, usually it is a propped up, prior to initiating general anaesthesia.<sup>7,8</sup>

Intubation should be done in the operating room with preoperative consultation by a multidisciplinary team involved in specialized Anaesthetics, intensivists and cardiothoracic surgeons and all present in the theatre during induction. Consider awake fiberoptic in certain situations, with rigid bronchoscope by the side.

Make a cardiopulmonary bypass or extracorporeal membrane oxygenator and perfusionist available, as the patient may need rescue cardiorespiratory support. Femoral venous cannulation or readiness to cannulate, should be arranged prior to anaesthesia induction in high-risk patients.

Avoid deep sedation and proceed with stepwise induction and titrated doses of anaesthetics. Inhalational anaesthesia can be a safe alternative

and avoid muscle relaxants. Maintain spontaneous, low-tidal volume ventilation during intubation and after initiation of mechanical ventilation.

## References

1. Benumof JL. Anaesthesia for special elective diagnostic procedures. In: Anesthesia for Thoracic Surgery. Philadelphia: WB Saunders, 1995; 491– 512.
2. Macchiarini P, Ostertag H. Uncommon primary mediastinal tumours. *Lancet Oncol* 2004;5:107e18.
3. De Backer A, Madern GC, Hakvoort-Cammel FG, Oosterhuis JW, Hazebroek FW. Mediastinal germ cell tumors: clinical aspects and outcomes in 7 children. *Eur J Pediatr Surg* 2006;16:318e22.
4. Kanellakos GW. Perioperative management of the pregnant patient with an anterior mediastinal mass. *Anesthesiol Clin* 2012;30:749–58.
5. Béchar P, Létourneau L, Lacasse Y, et al. Mediastinal mass obscured by a large pericardial effusion in a child: a potential cause of serious anaesthetic morbidity. *Anesthesiology* 2004;100:826–34.
6. Erdös G, Tzanova I. Perioperative anaesthetic management of mediastinal mass in adults. *Eur J Anaesthesiol* 2009;26:627–32.
7. Bray RJ, Fernandes FJ. Mediastinal tumour causing airway obstruction in anaesthetized children. *Anaesthesia*. 1982;37: 571–5.
8. O’Leary HT, Tracey JA. Mediastinal tumours causing airway obstruction: a case in an adult. *Anaesthesia*. 1983;38:67.
9. Pullerits J, Holzman R. Anaesthesia for patients with mediastinal masses. *Can J Anaesth* 1989;36:681-8.
10. Inoue M, Minami M, Shiono H, et al. Efficient clinical application of percutaneous cardiopulmonary support for perioperative management of a huge anterior mediastinal tumor. *J Thorac Cardiovasc Surg* 2006;131:755-6.
11. Asai T. Emergency cardiopulmonary bypass in a patient with a mediastinal mass. *Anaesthesia* 2007;62:859-60.
12. Anderson DM, Dimitrova GT, Awad H. Patient with posterior mediastinal mass requiring urgent cardiopulmonary bypass. *Anesthesiology* 2011;114:1488-93.

