

## Dushta Vrana: Simplified

Sathish H S<sup>1</sup>, Rashmi T M<sup>2</sup>, Mithun B<sup>3</sup>, Narmada M G<sup>4</sup>, Ahalya S<sup>5</sup>

**Author Affiliation:** <sup>1</sup>Professor, Department of Shalya Tantra, <sup>2</sup>Associate Professor, Department of Kayachikitsa, TMAE's Society Ayurvedic Medical College, Shimoga 577301, Karnataka, India, <sup>3</sup>Professor, Department of Shalaky Tantra, ALN Rao memorial Ayurvedic Medical College, Koppa, Karnataka 577126, India, <sup>4</sup>Professor, Department of Shalya Tantra, KTG Ayurveda College, Bengaluru 560091, Karnataka, India, <sup>5</sup>Principal, Government Ayurvedic Medical College, Bangalore 560010, Karnataka, India.

**Corresponding Author:** Sathish H S, Professor, Department of Shalya Tantra, TMAE's Society Ayurvedic Medical College, Shimoga 577301, Karnataka, India.

**Email:** ayursathishhs@gmail.com

### Abstract

Surgical outpatient departments are always flooded with Dushtavrana cases and details of Dushtavrana as cited in the treatises are not being simplified yet, as the many of the studies are targeted on evaluating the efficacy of potential wound healing drug. This article attempts to make the dushtavrana verse simpler with pictorial examples.

**Keywords:** Dushta vrana; Vrana; Shalya tantra.

### How to cite this article:

Sathish H S, Rashmi T M, Mithun B, Narmada M G, Ahalya S/Dushta Vrana: Simplified /Indian J Ancien Med Yog. 2021;14(4): 123-134.

### Introduction

Cases of Dushtavrana are routine in the OPD of Ayurvedic Surgical Science, Shalya Tantra (Ayurvedic surgical science), and diagnosing the same on the basis of Doshic lines is tedious task to the clinician, as the descriptions of the Dushtavrana cited in the texts contain two extremes, like, it can either be too minute like in a trivial scratch or in case of Sinus or too wide usually observed as in chronic bed sores or pressure ulcers. This article attempts to detail the description in the simpler form along with the illustration.

**Vrana Shopha:**<sup>1</sup> Vrana Shopha or Inflammatory Swelling is generally the preceding or precursory to Dushtavrana, it has three phases<sup>2</sup>, unripe or Ama avastha, Suppurative or Pachyamana Avastha

(Intermediary stage) and fully ripened or Pakwa avastha.<sup>3</sup>

### Review Methodology

Literary details pertaining to "Dushtavrana" has been collected from various texts of Ayurveda and other relevant materials screened from electronic databases 'Google' and 'Google Scholar' on the current subject till July 2020. Appropriate keywords related to "Dushtavrana" both in Ayurvedic and contemporary science were used for the search. This article is aimed to simplify the details of Dushtavrana as scripted in Ayurvedic treatise and present it in clinically appealing style with pictorial examples.



This work is licensed under a Creative Commons Attribution-NonCommercial-ShareAlike 4.0.

## Observation and Discussion

### Stage of Vrana formation:

**Vrana:** The term Vrana refers to breach or discontinuity in skin or epithelial membrane. In Sushruta's treatise, contextual usage of term Vrana is; an incision, an ulcer, an abscess, a burn and a sinus.

**Vranashotha:** Any pathological ulcer or Nija vrana manifest after the "shotha" or inflammation stage, hence premonitory stage of Vrana is expressed as "Vranashotha". (Fig. 1 & 2)

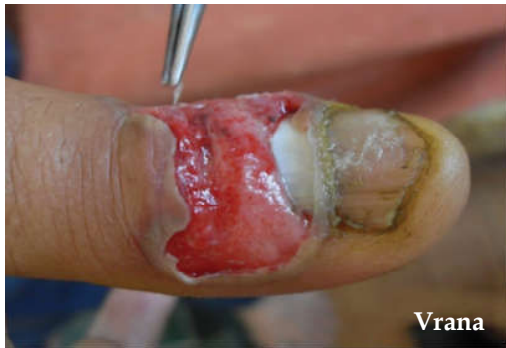
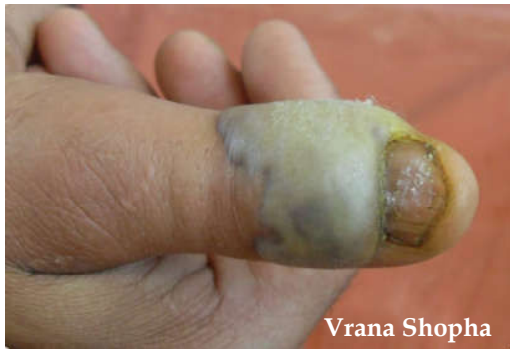
Fig. 1: Stage of Vrana formation. Classification of Vrana.

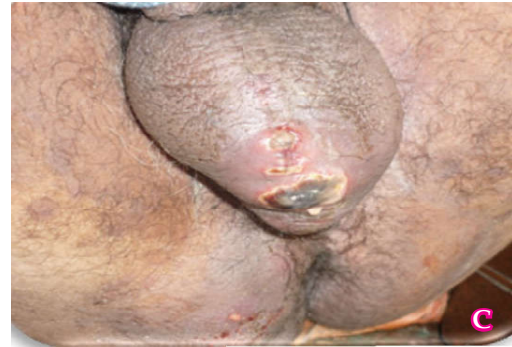
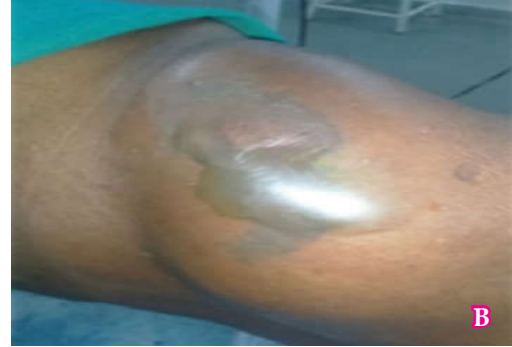
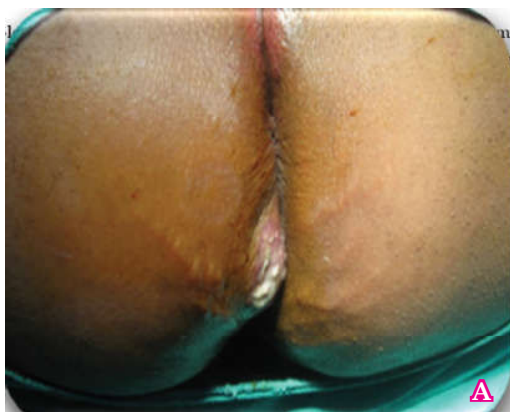Fig. 2: Vranashotha.

### Classification of Vrana

Acharyas	Types of Vrana
Sushruta	15 - Nija vrana
	6 - Sadyovrana
Charaka	20 types
	15 - Nija vrana
Vagbhata	6 - Sadyovrana
	6 - Dushta Vrana
Kashyapa	15 - Nija vrana
	7 - Sadyovrana
Sharangadhara	15 - Nija vrana
	8- Sadyovrana

षण्मूलोऽष्टपरिग्राही पञ्चलक्षणलक्षितः ।  
षष्ट्या विधानैर्निर्दिष्टैश्चतुर्भिः साध्यते व्रणः ॥

- Shanmoola or six causative factor - Vata, Pitta, Kapha, Rakta, Sannipata and Agantu.
- Ashtaparigrahi or eight adhishtana - Twak (Integument system), Mamsa (Muscle), Sira (Vessels), Snayu (Tendon), Asthi (Bone), Sandhi Majja (Bone marrow), Koshta (Gastrointestinal system) and Marma (Vital points).
- Panchalakshana - Clinical features which can

be perceived by using five senses of visual, tactile, gustatory, olfactory and hearing – srava, gandha, akruti, vedana and varna are the factors perceived.

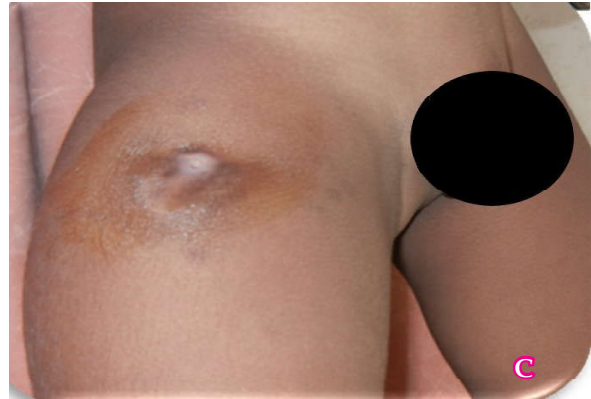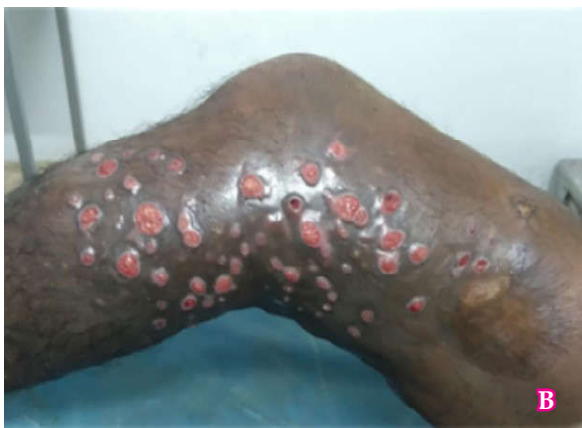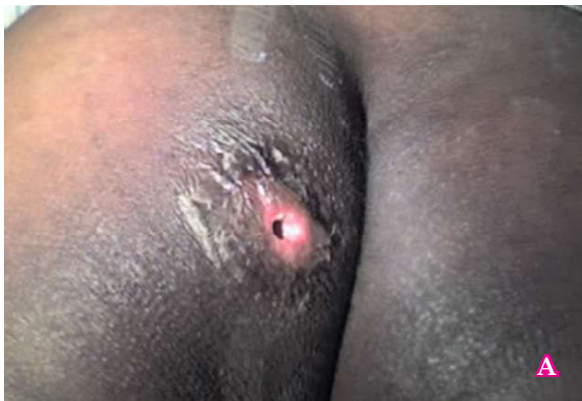- Shashti Upakrama – 60 therapeutical options to treat the ulcer.
- Managed by four limbs of treatment.

#### *Dushta vrana:*

The term Dushta vrana is christened for a chronic ulcer with high microbial load with high scores of pain and associated symptoms and with delayed or non healing nature. Understanding the details of the Dushta vrana is pivotal in prognosis and formulating the therapeutical plan. Hence in this study, an attempt is made to simplify the descriptions of the Dushta vrana.

#### *Ati Samvruta*

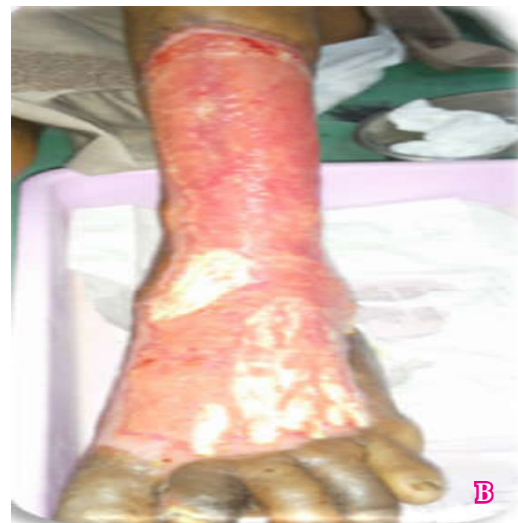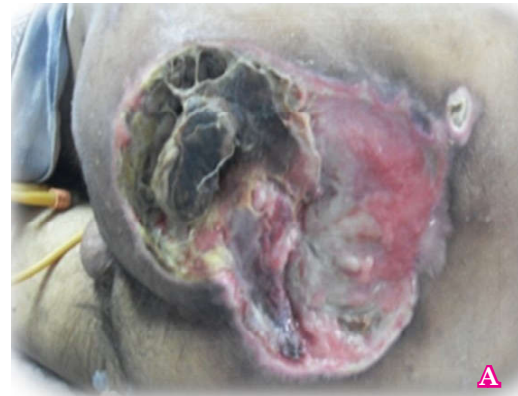The word “Samvruta” means concealed or tiny or minute. It refers to opening of an ulcer due to Vata dosha. This feature is an inspector finding in the clinical examination. The wound with minute openings such as sinus or fistulous tracks are best suited examples for Ati Samvruta. (Fig. 3)



**Fig. 3:** Ati Samvruta Vrana.

#### *Ati Vivruta:*

Vivruta refers to wide open or gaping; the wide mouthed wound is also one of characteristic feature of Dushta Vrana. This feature is by pitta and rakta dosha dominance. Non healing bed sore or pressure ulcers, venous ulcers are few examples for this feature. (Fig. 4)



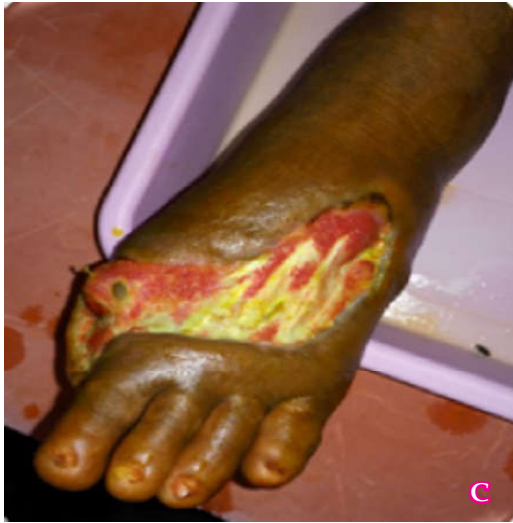

Fig. 4: Ati Vivruta Vrana.

#### Ati Kathina:

Kathina means hard or solid or indurated due to Vata dosha and appreciable on palpation, there are certain wounds which are very hard to touch as in cases of Actinomyces or in chronic non healing venous ulcers or ulcer in the Elephantiasis. (Fig. 5)

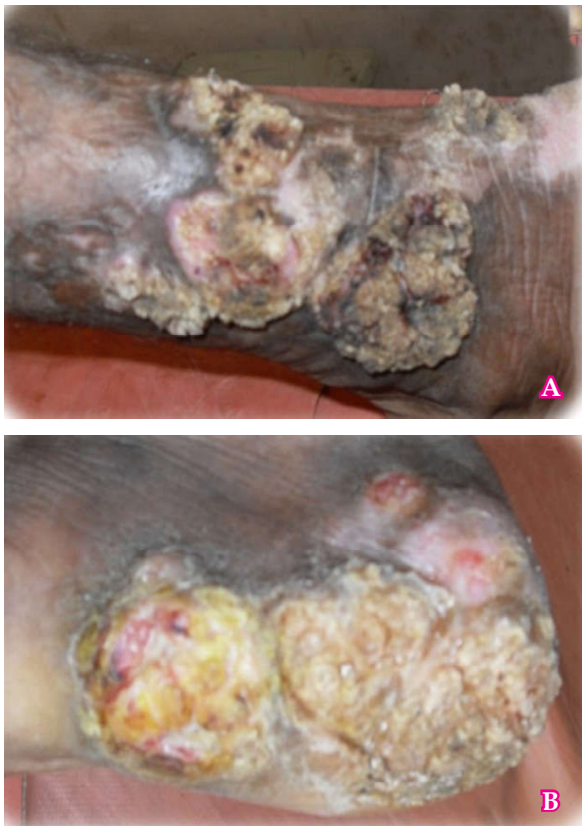

Fig. 5: Ati Kathina Vrana.

#### Ati mridu:

Mridu means soft due to Kapha, pitta and rakta dosha, there are various ulcers which are very soft on palpation. The best suited examples are ulcers of genitalia - fournier's gangrene, soft chancre and ulcers of the mouth etc. (Fig. 6)

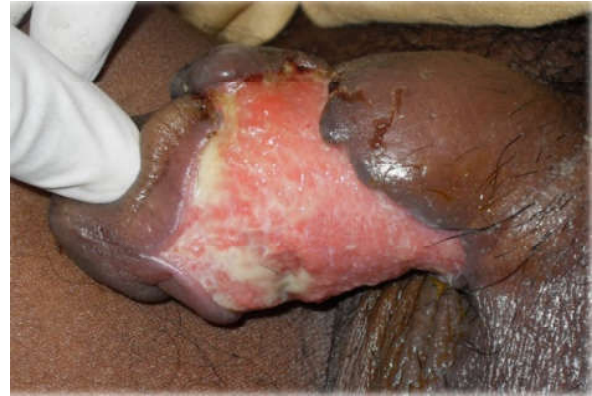

Fig. 6: Ati Mridu Vrana.

#### Ati Sheeta:

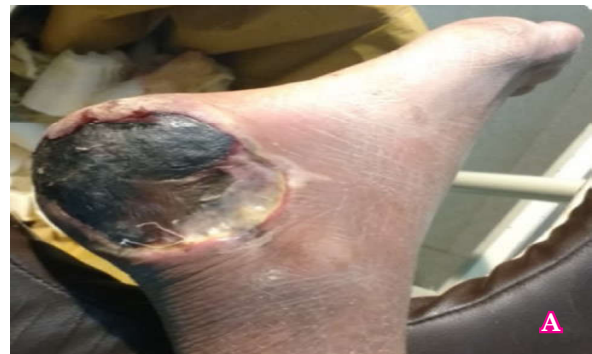Ulcers which are cold on touch are usually seen in arterial or ischemic ulcers, and in gangrene due to the involvement of Vata and Kapha. It is indicative of mild to severe vascular insufficiency.

#### Ati Ushna:

The local rise of temperature over the ulcer and its peri area is quite often seen infective, inflammatory ulcer, or pitta pradhana vrana.

#### Krishna varna:

Ulcer with blackish discoloration is an inspection finding. Numerous examples are present for ulcer with blackish discoloration denoting necrosed, unhealthy tissue in the wound bed. Examples include Necrotizing fasciitis, fournier's gangrene, in all types of gangrene, Arterial ulcers, Vincent ulcer, Pressure ulcer etc. (Fig. 7).



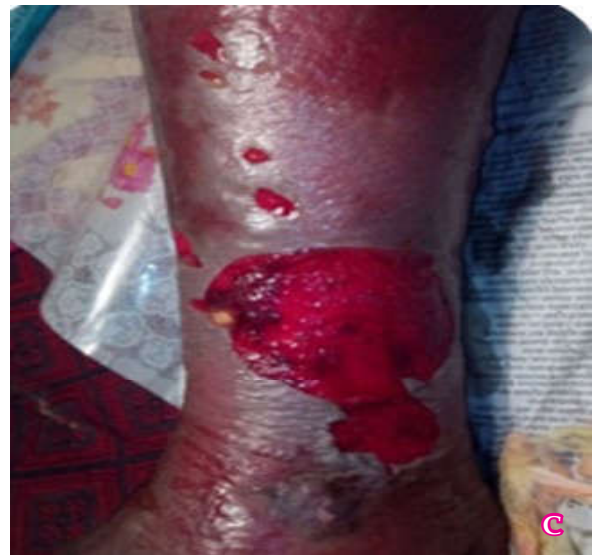
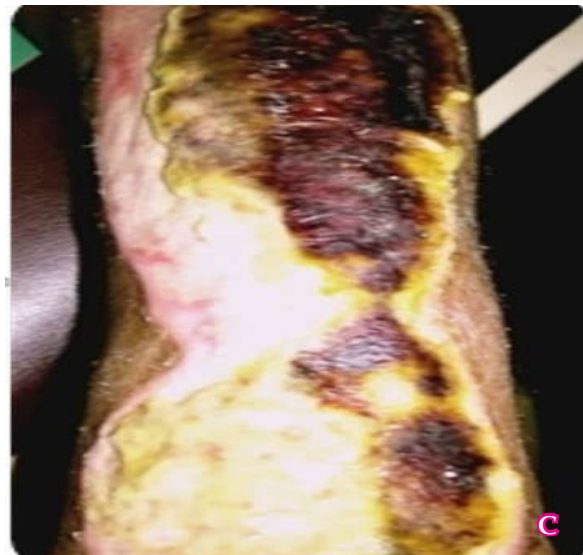
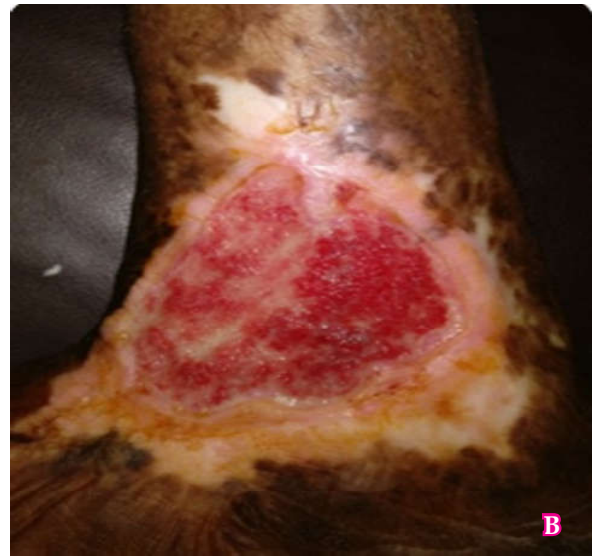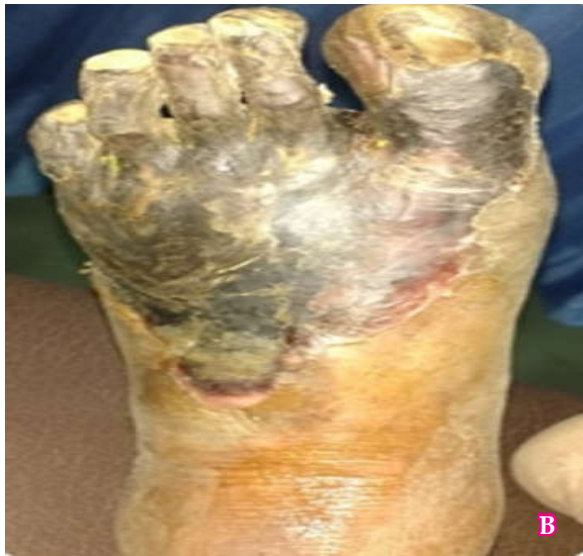Fig. 7: Krishna varna Vrana.

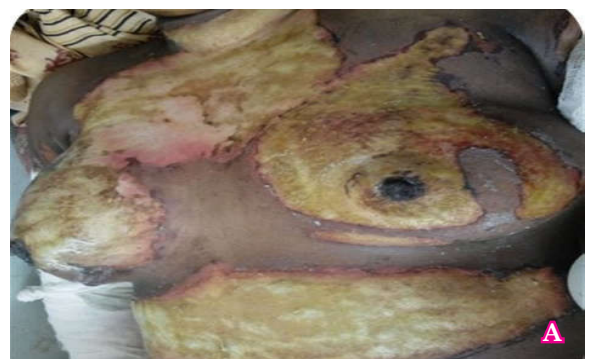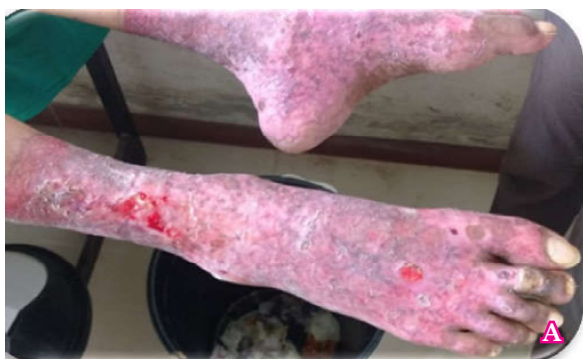Fig. 8: Rakta varna Vrana.

**Rakta varna**

Ulcer with red hue can be appreciated in burn wounds, Inflammatory ulcers, Martorel ulcer etc. (Fig. 8)

**Peeta varna**

The ulcer with yellowish discoloration are very often seen in purulent ulcers or numerous ulcers with increased microbial loads. (Fig. 9)



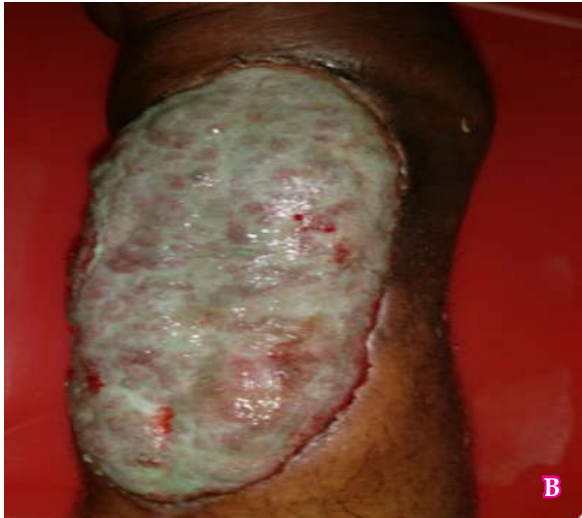

Fig. 9: Peeta varna Vrana.

#### *Shukla varna*

Ulcers with whitish discoloration are found in Candida associated gastric ulcer, peptic ulcer, tubercular ulcer. (Fig. 10)

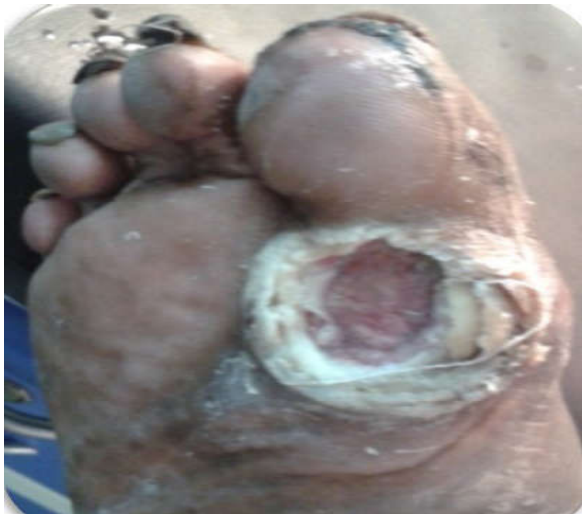

Fig. 10: Shukla varna Vrana.

#### *Anyatamo varna*

“Anyatamo” refers to undistinguishable colour or mixture of various colours and the designation of one specific colour are difficult. An ulcer exhibiting multiple colors is indicating the involvement of more than one dosha or bodily humours and its chronicity. Contents of wound bed, slough, unhealthy or healthy granulation tissue, discharge, ulcer on which it rests like fascia, muscle are responsible for the colour other than usual colour. (Fig. 11)

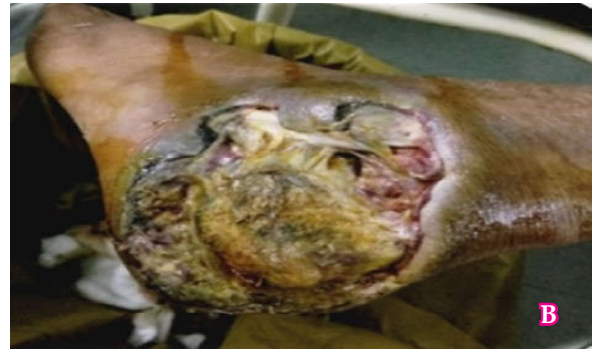
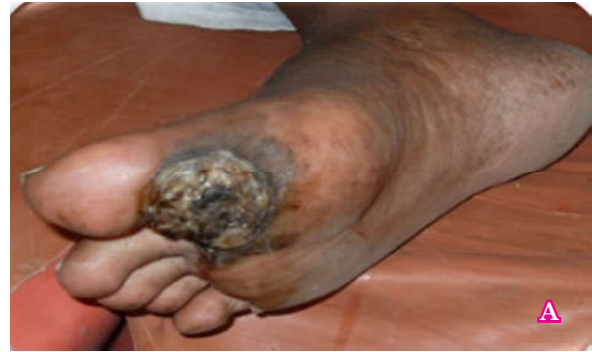
Fig. 11: Vrana with indistinguishable colour.

#### *Utsanna Vartma*

The word “vartma” denotes edge of the ulcer and ‘utsanna’ means elevated by the influence of Vata pitta dosha. An elevated edge of an ulcer is one of the characteristic features in Dushta vrana. Elevated edge of ulcers are commonly found in chronic non healing ulcer, malignant ulcer etc. (Fig. 12)

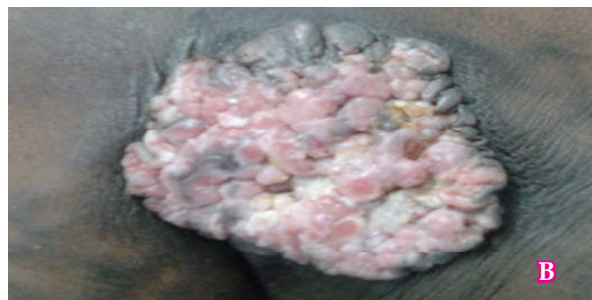
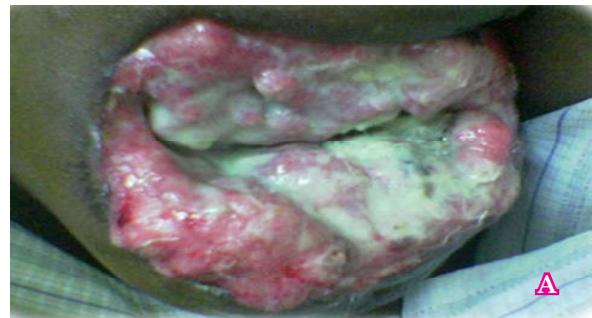
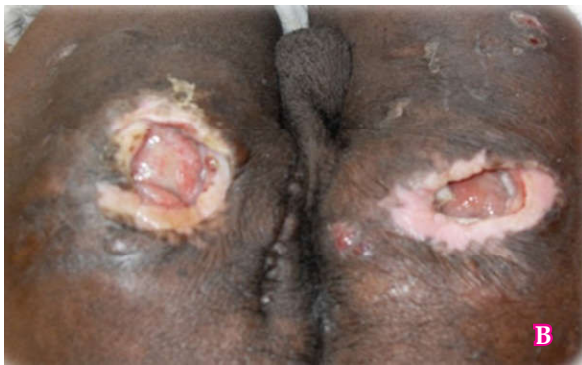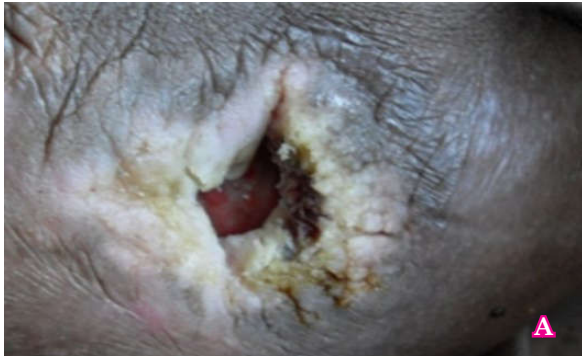Fig. 12: Utsanna Vartma.

***Avasanna vartma***

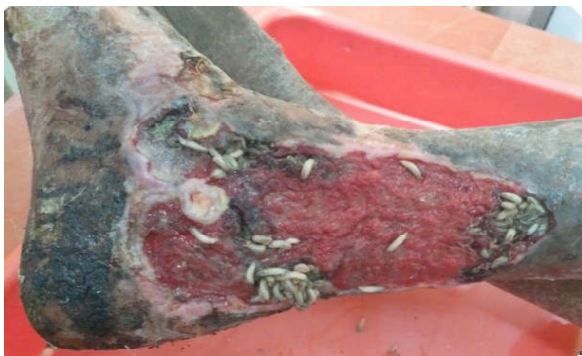It is contrary to Utsanna vartma, in this type of ulcers, the ulcer edge will be inverted or undermined as quite often seen in tubercular ulcer, chronic bed sores or trophic ulcers, Pyoderma gangrenosum, Buruli ulcer, Mooren ulcer. (Fig. 13). Pitta and rakta dosha is responsible for this type of edge.



**Fig. 13:** Avasanna vartma.

***Krimi***

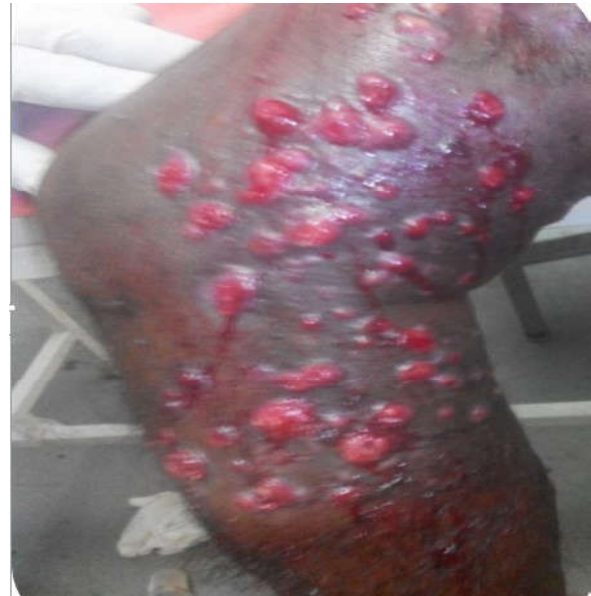Invasion of micro or macro organisms into the wound is observed in Dushtavrana by which the local doshic imbalance aggravates resulting in extensive tissue damage and also initiation of systemic complications. (Fig. 14)



**Fig. 14:** Vrana afflicted with Krimi (Maggots).

***Dushta shonitha sravi***

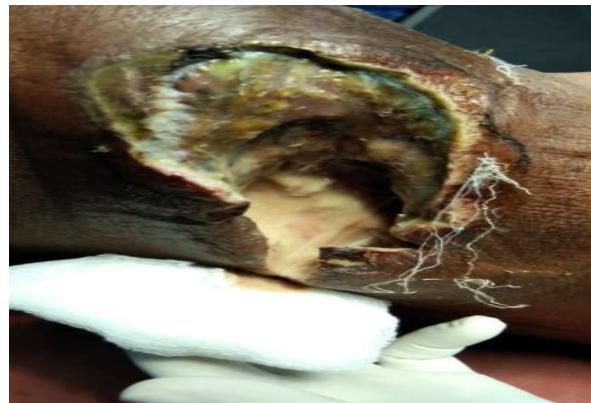
Bloody discharge is a customary feature observed in the ulcer necessitating the quick therapeutic measures to check the same. (Fig. 15)



**Fig. 15:** Vrana with bloody discharge.

***Pooyasravi***

Pooya or wound discharge is one of the vital feature which assists clinician both in diagnosis, prognosis and planning therapeutical measures. (Fig. 16)



**Fig. 16:** Vrana with pooyasrava.

***Bhairava - Amanojna Darshana: Horrifying or Unpleasant or Disagreeable look;***

This term is specifically mentioned in the details of the dushta vrana to denote the horrifying appearance or look of ulcer due to various causes. There are numerous benign and malignant ulcers which are unpleasant to look and also their exterior

is sickening like in basal cell carcinoma, Marjolin ulcer, basal cell epithelioma. (Fig. 17)

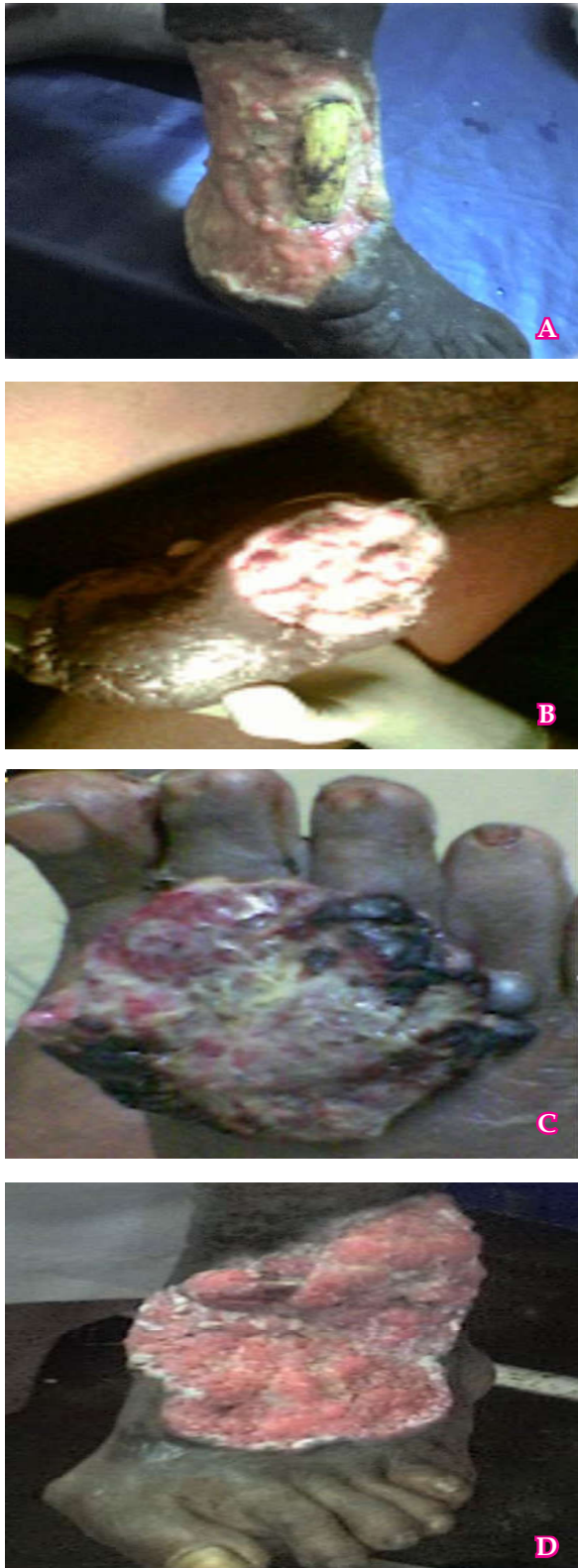

Fig. 17: Horrifying look of certain Vrana.

### ***Utsangi - Unmargi:***

Dalhana commenting on this delineate the word Unmargi as Tiryak gati which means, an ulcer with penetrating or invasive nature. Invasive spread of the ulcer destroying the healthy tissues is appreciable in Tubercular, malignant ulcers and sinuous tracts. The other examples are Shambookavarta bhagandara, ushtragriva bhagandara. (Fig. 18).

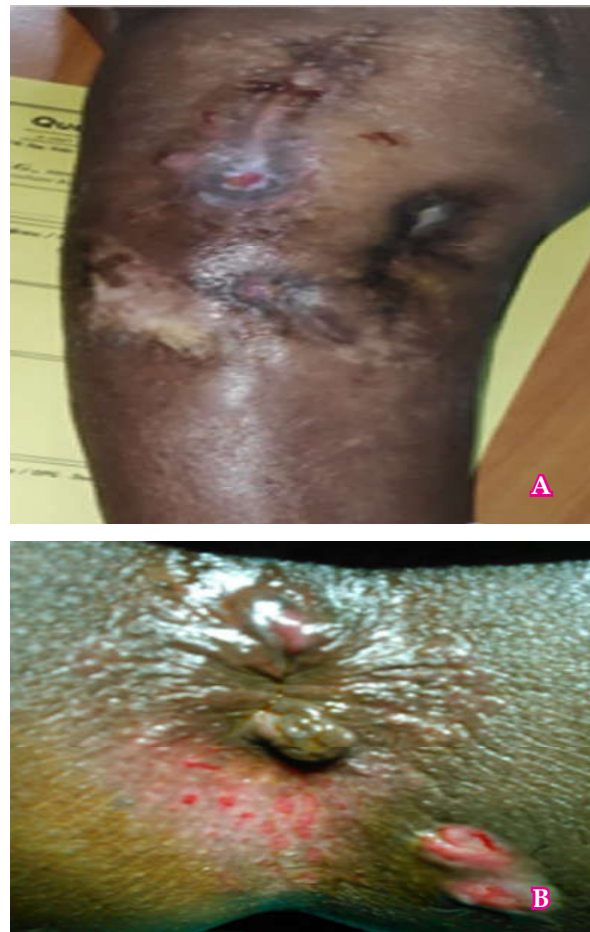

Fig. 18: Utsangi - Unmargi vrana

### ***Atyartha Vedan***

High scores of pain is experienced by the patient with infective, neurological and inflammatory conditions, the nature of wound pain varies based on the doshic composition in the pathology. Deranged Vata and rakta or raktavrita vata is responsible for the severe pain.

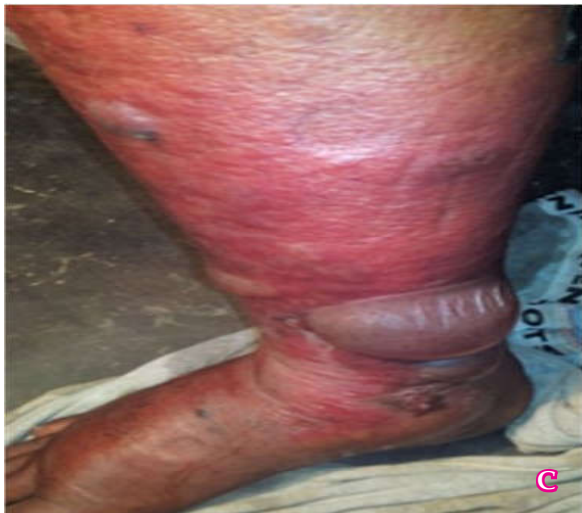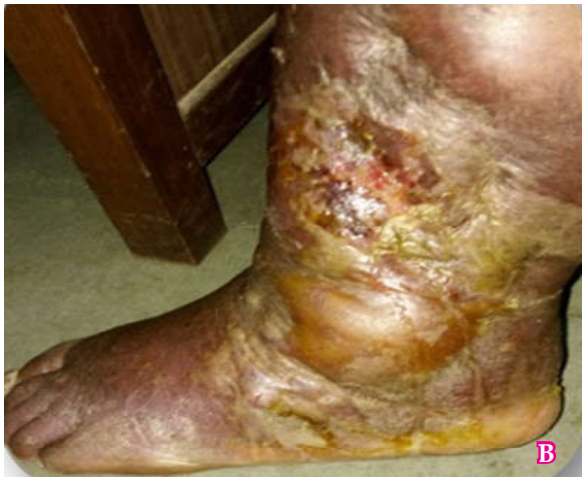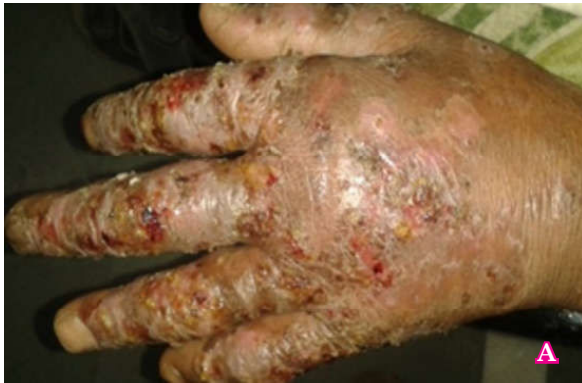### ***Daha - Burning sensation***

The vitiated pitta dosha is pivotal for the precipitation of burning sensation in a wound.



**Paka**

The term 'Paka' refers to the event of suppuration, wherein abnormal bodily humors especially Pitta along with the rakta dosha accelerate tissue destruction by virtue of Suppurative process. (Fig. 19)



**Fig. 19:** Vrana associated with Paka

**Raga**

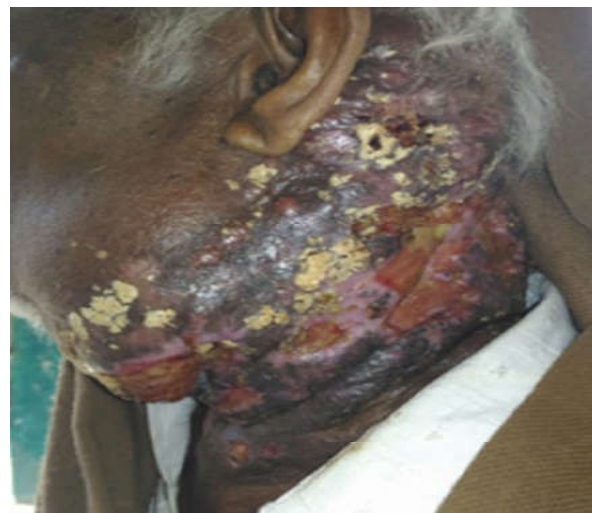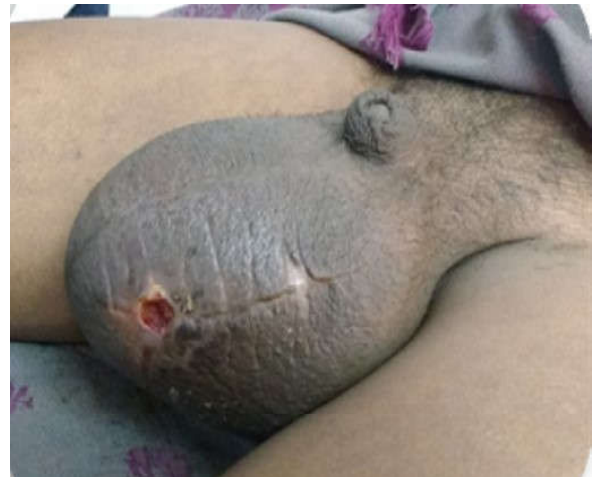Redness or Erythema is one of the salient feature of the dushta vrana, here the erythema is not just confined to wound itself event the peri wound area is also presents with redness denoting the ongoing process inflammation or Paka mainly due to the involvement of rakta dosha.

**Kandu**

Kandu or Itching sensation is resultant to the vitiation of Kapha dosha and increased dryness of Vata dosha.

**Shopha**

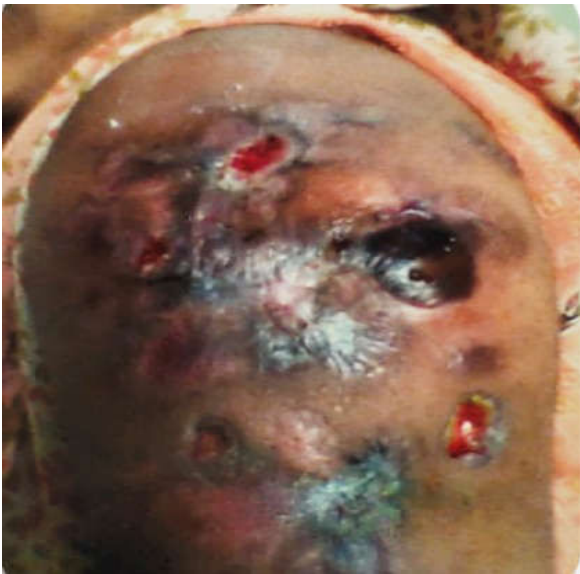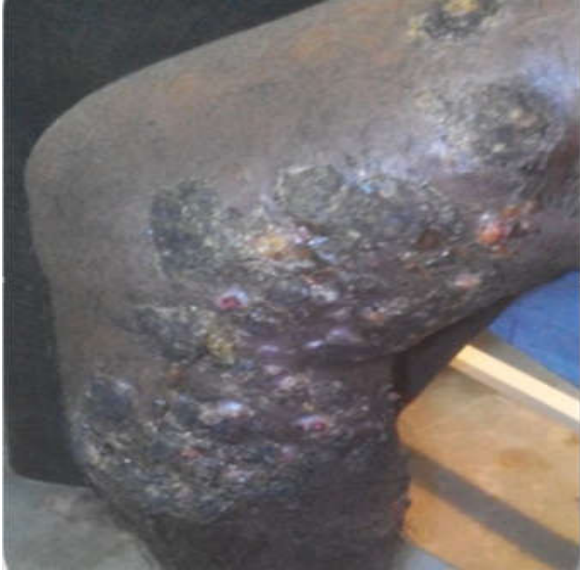Edema of the surrounding skin is usual feature in Dushta vrana denoting the local aggravation of dosha by virtue of inflammatory response or injury response or deranged extracellular and intracellular fluid volumes. (Fig. 20)



**Fig. 20:** Vrana associated with shotha.

### *Pidakopadruta*

The term pidaka is used to denote ulcers associated with pustules, blebs or boils, and such pidaka denotes the involvement of Kapha and pitta dosha predominance. (Fig. 21)



**Fig. 21:** Pidakayukta vrana.

### *Deergha kala anubandhi*

Chronic ulcers are considered as Dushta vrana, Dalhana while commenting on Sushruta's verse states, the fresh wound which fails to heal within seven days must be considered and treated as Dushta vrana, this denotes the minimum time frame for any wound to be considered as Dushta vrana is seven days.

Systemic symptoms of Fever, nausea, thirst etc must be assessed while diagnosing a case of Dushta vrana.

Checklist of factors essential to get designated as Dushta vrana:

- Any extent of the tissue loss either minimal like in sinus or huge as in case of Chronic non healing venous, trophic ulcers.
- Tissue consistency - Either too hard or solid, rough or soft consistency.
- Wound edge - Everted or undermined or inverted edge.
- Wound appearance - Gross tissue loss with horrifying or unpleasant look.
- Wound color - Wound exhibiting different color either yellow, white, black, green or mixed colors.
- Chronicity - More than 7 days.
- Systemic features - Fever, nausea, thirst etc.

### **Conclusion**

Dushta vrana is a chronic ulcer either sinus or wide mouthed, with oedematous, everted or undermined edge with high microbial load (Bahu doshata), with inflammation, varying degrees of pain, chronicity of more than 7 days, with highly stinky discharge and associated with systemic complaints of fever, thirst etc. A proper history of the case with methodical clinical examination is pivotal in arriving at the diagnosis.

### **References**

1. Kumar S, Channabasavanna Bm, Mallikarjun M. Vrana Shopha-An Ayurvedic Perspective. *Journal of Ayurveda and Integrated Medical Sciences* (ISSN 2456-3110). 2017 May 5; 2(2):224-8.
2. Praveen Pk, Savadi Bs. Clinical Comparative Study on the Efficacy of Ghonta Phaladi Varti and Aragvadhadi Varti in the Management of Nadi Vrana Wsr Sinus. *International Journal of Ayurveda and Pharma Research*. 2019 Apr 3.
3. Panda A, Tripathy R. Concept of Sopha (Inflammation): A Critical Study. *International Journal of Research-Granthaalayah*. 2020 Aug 18;8(8):15-23.
4. Gond P, Singh L. Concept of Infected Wound (Dushta Vrana) In Ayurveda. *J Adv Res Ayur Yoga Unani Sidd Homeo*. 2017;4(3):11-5.

5. Winslow R. Fungous Diseases of the Foot, or Madura Foot, In America. *Annals of Surgery*. 1917 Oct; 66(4):496.
6. Martinschek A, Evers B, Lampl L, Gerngroß H, Schmidt R, Sparwasser C. Prognostic Aspects, Survival Rate, and Predisposing Risk Factors in Patients with Fournier's Gangrene and Necrotizing Soft Tissue Infections: Evaluation of Clinical Outcome of 55 Patients. *Urologia Internationalis*. 2012;89(2):173-9.
7. Ndinya-Achola Jo, Kihara An, Fisher Ld, Krone Mr, Plummer Fa, Ronald A, Holmes Kk. Presumptive Specific Clinical Diagnosis of Genital Ulcer Disease (Gud) In A Primary Health Care Setting In Nairobi. *International Journal of Std & Aids*. 1996 May 1;7(3):201-5.
8. Agostini M, Meirelles V, Cortezzi Eb, Netto Jd, Curvelo Ja, Cabral Mg, Romañach Mj. Gingival Sebaceous Cystic Choristoma: Case Report. *Oral Surgery, Oral Medicine, Oral Pathology and Oral Radiology*. 2014 Feb 1;117(2):E124-5.
9. Strauss J. Martorell Hypertensive Ischaemic Leg Ulcer the Ulcer Nobody is talking about..... But Should. *Wound Healing Southern Africa*. 2020 Dec 1;13(2):40-2.
10. Maloy Jp. Arterial Ulcers. *Quick Reference to Wound Care*. 2009 Oct 5:123.
11. Mahesh S, Mallappa M, Vithoukas G. Gangrene: Five Case Studies of Gangrene, Preventing Amputation through Homoeopathic Therapy.
12. Dawson D, Mclean G, Wilson A. A Case of Popliteal Artery Stenosis: Masquerading As an Infective Foot Ulcer in a Young Male Traveller. *Journal of Surgical Case Reports*. 2015 Mar 1;2015(3):Rjv012.
13. Chadwick P, Mccardle J, Malone M. Assessing Infected Ulcers: A Step-By-Step Guide. *Journal of Wound Care*. 2015 May 1;24(Sup5b):15-9.
14. Singh R, Pawar S, Goel K. Ayurvedic Management of Dushta Vrana Wsr to Diabetic Foot Ulcers. *Journal of Ayurveda and Integrated Medical Sciences (Issn 2456-3110)*. 2020 May 25;5(2):263-8.
15. Imamura Y, Kudo Y, Ishii Y, Shibuya H, Takayasu S. A Case of Subacute Necrotizing Fasciitis. *The Journal of Dermatology*. 1995 Dec;22(12):960-3.
16. Hagedorn Jc, Wessells H. A Contemporary Update on Fournier's Gangrene. *Nature Reviews Urology*. 2017 Apr;14(4):205-14.
17. Meleney Fl. Hemolytic Streptococcus Gangrene. *Archives of Surgery*. 1924 Sep 1;9(2):317-64.
18. Dudhamal Ts. Wound Healing Effect of Humri (Securinega Leucopyrus) and Supportive Ayurveda Therapy in Beurger's Ulcer. *Annals of Ayurvedic Medicine*. 2016;5(1):37-43.
19. Blank H. Tropical Phagedenic Ulcer (Vincent's Ulcer). *The American Journal of Tropical Medicine and Hygiene*. 1947 May 1;1(3):383-98.
20. Makhous M, Lin F, Knaus E, Zeigler M, Rowles Dm, Gittler M, Bankard J, Chen D. Promote Pressure Ulcer Healing in Individuals with Spinal Cord Injury Using an Individualized Cyclic Pressure-Relief Protocol. *Advances in Skin & Wound Care*. 2009 Nov;22(11):514.
21. Hettiaratchy S, Papini R. Initial Management of a Major Burn: Ii-Assessment and Resuscitation. *Bmj*. 2004 Jul 8;329(7457):101-3.
22. Humphry Gm. A Course of Lectures on Surgery, Delivered in the Medical School of Cambridge. Lecture IX. Ulceration Continued: Mortification. *Provincial Medical and Surgical Journal (1844-1852)*. 1849 Jun 13:309-15.
23. Vuerstaek Jd, Reeder Sw, Henquet Cj, Neumann Ha. Arteriolosclerotic Ulcer of Martorell. *Journal of the European Academy of Dermatology and Venereology*. 2010 Aug;24(8):867-74.
24. Robinson Dc, Adriaans B, Hay Rj, Yesudian P. The Clinical and Epidemiologic Features of Tropical Ulcer (Tropical Phagedenic Ulcer). *International Journal of Dermatology*. 1988 Jan;27(1):49-53.
25. Zhu Qc, Shen Rr, Qin Hl, Wang Y. Solitary Rectal Ulcer Syndrome: Clinical Features, Pathophysiology, Diagnosis and Treatment Strategies. *World Journal of Gastroenterology: Wjg*. 2014 Jan 21;20(3):738.
26. Abbade Lp, Lastória S. Venous Ulcer: Epidemiology, Physiopathology, Diagnosis And Treatment. *International Journal of Dermatology*. 2005 Jun;44(6):449-56.
27. Sasaki K. Candida-Associated Gastric Ulcer Relapsing In a Different Position With a Different Appearance. *World Journal of Gastroenterology: Wjg*. 2012 Aug 28;18(32):4450.
28. Tileston W. Peptic Ulcer of the Oesophagus. *The American Journal of the Medical Sciences (1827-1924)*. 1906 Aug 1;132(2):240.
29. Hussaini J, Mutusamy S, Omar R, Rajagopalan R, Narayanan P. Base of Tongue Tuberculosis: a Case Report.
30. Johnson Sr, Taylor Ma. Identification and Management of Malignant Skin Lesions

- among older Adults. *The Journal for Nurse Practitioners*. 2012 Sep 1;8(8):610-6.
31. Rahman Ga, Adigun Ja, Fadeyi A. *Epidemiology, Etiology and Treatment of Chronic Leg Ulcer: Experience with Sixty Patients*. *Annals of African Medicine*. 2010;9(1).
  32. Lim Lg, Yeoh Kg, Wai Ct. *Metastatic Pancreatic Cancer Presenting as a Bleeding Duodenal Ulcer 30 months after Initial Diagnosis of Duodenal Ulcer. Should Duodenal Ulcers be Biopsied or Followed up with Repeat Endoscopy?*. *Acta Gastro-Enterologica Belgica*. 2008 Jul 1;71(3):347-8.
  33. Downie Jw. *Epithelioma Primarily Affecting The Tonsil*. *British Medical Journal*. 1890 May 3;1(1531):1008.
  34. Kannappan O, Mathew S, Naalla R. *Solitary Rectal Ulcer Syndrome-the Masquerader*. *International Journal of Scientific And Research Publications*. 2015 May;5(5):1-5.
  35. Ram H, Kumar S, Mehrotra S, Mohommad S. *Tubercular Ulcer: Mimicking Squamous Cell Carcinoma of Buccal Mucosa*. *Journal of Maxillofacial and Oral Surgery*. 2012 Mar;11(1):105-8.
  36. George C, Deroide F, Rustin M. *Pyoderma Gangrenosum—A Guide to Diagnosis and Management*. *Clinical Medicine*. 2019 May;19(3):224.
  37. Meyers Wm, Tignokpa N, Priuli Gb, Portaels F. *Mycobacterium Ulcerans Infection (Buruli Ulcer): First Reported Patients in Togo*. *British Journal of Dermatology*. 1996 Jun;134(6):1116-21.
  38. Majekodunmi Aa. *Ecology of Mooren's Ulcer in Nigeria*. *Documenta Ophthalmologica*. 1980 Oct;49(2):211-9.
  39. Pawar A, Borase Y. *Study of Efficacy of Nimbapatradi Vranadhoopan In Treatment of Dushta Vrana*. *International Journal of Research In Ayurveda and Medical Sciences*. 2019;2:207-13.
  40. Cannady Sb, Batra Ps, Koenig C, Lorenz Rr, Citardi Mj, Langford C, Hoffman Gs. *Sinonasal Wegener Granulomatosis: A Single Institution Experience With 120 Cases*. *The Laryngoscope*. 2009 Apr;119(4):757-61.
  41. Chao Yc, Chen Ch, Chen Yk, Chou Ct. *A Large Ulcer and Cutaneous Small Vessel Vasculitis Associated With Syphilis Infection*. *Scandinavian Journal of Rheumatology*. 2006 Jan 1;35(2):147-51.
  42. Ghodela Nk, Dudhamal Ts, Gupta Sk, Mahanta V. *Journal of Ayurveda Case Reports*. *Journal of Ayurveda Case Reports*. 2019 Jan;2(1):35.
  43. Jackson R, Adams Rh. *Horrifying Basal Cell Carcinoma: a Study of 33 Cases and a Comparison with 435 Non Horror Cases and a Report on Four Metastatic Cases*. *Journal of Surgical Oncology*. 1973;5(5):431-63.
  44. Maillard Gf, Landolt A. *Penetrating Marjolin's Ulcer of Scalp Involving Bone and Dura Mater Treated by Wide Excision and Direct Application of a Split-Skin Graft on The Brain: A 10-Year Follow-Up*. *British Journal of Plastic Surgery*. 1984 Oct 1;37(4):463-7.
  45. Dvoretzky I, Fisher Bk, Haker O. *Mutilating Basal Cell Epithelioma*. *Archives of Dermatology*. 1978 Feb 1;114(2):239-40.
  46. Banerjee Sn, Ananthkrishnan N, Mehta Rb, Parkash S. *Tuberculous Mastitis: A Continuing Problem*. *World Journal of Surgery*. 1987 Feb;11(1):105-8.
  47. Cordero-Coma M, Benito Mf, Fuertes Cl, Antolín Sc, Ruíz Jm. *Adalimumab for Mooren's Ulcer*. *Ophthalmology*. 2009 Aug 1;116(8):1589.
  48. Williams Hl, Heilman Fr. *Spreading Osteomyelitis of the Frontal Bone Secondary to Disease of the Frontal Sinus: With a Preliminary Report as to Bacteriology and Specific Treatment*. *Archives of Otolaryngology*. 1937 Feb 1;25(2):196-207.
  49. Dissemond J, Körber A, Grabbe S. *Differential Diagnosis of Leg Ulcers*. *Jddg: Journal Der Deutschen Dermatologischen Gesellschaft*. 2006 Aug;4(8):627-34.
  50. Venkatesh H, Venkatesh P, Hegde N. *A Case Study on Dushta Vrana Caused Due to Vatarakta*. *Journal of Ayurveda and Integrated Medical Sciences (Issn 2456-3110)*. 2018 Sep 9;3(4):228-33.
  51. Shekokar Av, Ukhalkar Vp. *Study of the Efficacy of Ksharaploti In Dushtavrana Wsr to Infected Wound*. *International Journal of Ayurvedic Medicine*;11(2):314-21.
  52. Binya Vb, Shukkoor Ma, Subi Nh. *Concept of Shadkriyakaala of Vrana By Susrutha Wsr to Venous Ulcer*. *International Journal of Ayurveda And Pharma Research*. 2020 Oct 16:38-46.
  53. Mohod P, Shah Ab, Deep Vc, Mohod S. *Short Review on Pain (Vedana) By Sushruta*. *International Journal of Ayurveda And Pharma Research*. 2020 Apr 2:55-8.

54. Fatima Sa, Kumar M. Clinical Approach to Vrana Shopha Wsr to Inflammatory Swelling. *Journal of Ayurveda and Integrated Medical Sciences* (ISSN 2456-3110). 2018 Sep 10;3(4):148-53.
55. Bhat Ks, Vishwesh Bn, Sahu M, Shukla Vk. A Clinical Study on the Efficacy of Panchavalkala Cream In Vrana Shodhana Wsr to its Action on Microbial Load and Wound Infection. *Ayu*. 2014 Apr;35(2):135.

